

## Pre-operative MRI Findings in Idiopathic Intracranial Hypertension (IIH) Patients Who Underwent Optic Nerve Sheath Fenestration (ONSF) with Postoperative Visual Improvement: Observational Findings

Forhad Hossain Chowdhury<sup>1</sup>, Muhammad Mukhlesur Rahman<sup>2</sup>,  
Mohammad Raziul Haque<sup>3</sup>, Mainul Haque Sarker<sup>4</sup>

### Abstract

**Background:** Optic nerve sheath fenestration (ONSF) is commonly used in idiopathic intracranial hypertension (IIH) with visual deterioration and visual improvement is observed post operatively in these patients. **Objective:** Retrospective evaluation of MRI observations in IIH patients who underwent optic nerve sheath fenestration (ONSF) with postoperative visual improvement. **Materials and method:** Optic nerve sheath fenestration (ONSF) was done in twenty four (24) patients with IIH having severe visual impairment. Post operatively all patients improved in their visual functions. The recorded pre operative MRI (of brain and orbit) of patients were reviewed and evaluated retrospectively. **Results:** Total number of MRI studied was 24. Male female ratio was 1:11. Posterior globe flattening was found in all 24 (100%) cases. Other findings were horizontal tortuosity of optic nerve (92%), optic nerve head protrusion (87.5%), optic nerve sheath distension (87%), and vertical buckling (62.5%). Ventricular size was normal in 92% cases and slit ventricle was found only in 8% cases. On magnetic resonance venogram (MRV) one sided transverse sinus abnormality was found in 25% cases. There was empty sella in 79% cases, more marked in three cases. **Conclusion:** The MRI findings in IIH patients with positive post ONSF result are of variable degree and prevalence except posterior globe flattening which was found in all cases.

**Keywords:** Optic nerve sheath fenestration; ONSF; IIH; MRI findings.

*Delta Med Col J. Jan 2020;8(1):21 – 27*

### Introduction

Increased intracranial pressure (ICP) can be due to a secondary etiology such as mass lesions, meningitis, venous sinus thrombosis or hydrocephalus. It may also be due to unknown etiology “idiopathic.” Idiopathic intracranial hypertension (IIH) is a condition of raised ICP in absence of any recognizable cranial pathology and with normal cerebrospinal fluid (CSF)

constituents.<sup>1-3</sup> The cause of IIH is not known and it is a diagnosis of exclusion.<sup>4</sup> Cerebral venous sinus thrombosis is the most important differential of IIH. Both IIH and cerebral venous sinus thrombosis may cause attenuation of the venous sinuses due to increased ICP. The differentiation of these two pathological condition may be difficult and challenging even on cerebral

1. Assistant Professor, Dept. of Neurosurgery, National Institute of Neurosciences and Hospital, Sher-e-Bangla Nagar, Dhaka, Bangladesh.
2. Assistant Professor, Dept. of ENT, Sylhet MAG Osmani Medical College and Hospital, Sylhet, Bangladesh.
3. Professor, Dept. of Neurosurgery, Dhaka Medical College Hospital, Dhaka, Bangladesh.
4. Professor and Senior Consultant, Ibn Sina specialized Hospital, Dhaka, Bangladesh.

**Correspondence:** Dr. Forhad Hossain Chowdhury. e-mail: forhadchowdhury74@yahoo.com

venogram.<sup>5</sup> Exclusion of differentials is crucial for management of IIH.

In literature many MRI findings of IIH have been reported such as perioptic nerve sheath distention, vertical buckling of optic nerve, posterior globe flattening, optic nerve head protrusion and an empty sella.<sup>1,6-8</sup>

In this study a retrospective evaluation of MRI observations was done in IIH patients with visual impairment who underwent optic nerve sheath fenestration (ONSF) with postoperative visual improvement at least to that extent by which one can maintain himself or herself in their daily personal life.

## Materials and method

During the period of January 2011 to June 2019, the MRI findings of the patients who underwent optic nerve sheath fenestration (ONSF) for idiopathic intracranial hypertension (IIH) in National Institute of Neurosciences and Hospital and some other private hospitals in Dhaka, Bangladesh were studied. A total of twenty four (24) patients with IIH having severe visual impairment were operated. Post operatively visual functions of all the patients improved (at least to that extent by which one can maintain himself or herself in their daily personal life). The recorded data of pre operative MRI findings and patient management along with follow up were reviewed retrospectively. The patients who improved in their visual function at least to some extent were identified and their preoperative MRI findings of orbit and brain were observed, studied and presented as results. Preoperative MRI findings that were studied include preoperative perioptic nerve sheath distention, horizontal and vertical tortuosity of optic nerve, posterior globe flattening, optic nerve head protrusion, ventricular size, magnetic resonance venogram (MRV) and empty sella. Post operatively MRI was not done in all cases. Where done postoperative MRI findings were also studied and presented.

## Results

Total number of MRI studied was 24. Age range of the study subjects was 11-38 years (average 24.4 years). Male and female ratio was 1:11. Indications of ONSF were idiopathic intracranial hypertension (IIH) with severe visual impairment. (Table I)

**Table I: Age and sex distribution with MRI findings in the operated patients of IIH**

Age (years) and sex	Peri-optic sheath distension	Vertical buckling	Posterior globe flattening	ON nerve head protrusion	Horizontal bending & elongation	Ventricular size	MRV	Empty sella	Post op ON
11,M	+	+	+	+	+	N	N	+	N
35,F	++	+	++	+	+	N	Hypoplastic left TS	-	-
19,F	+	-	+	+	+	N	Hypoplastic left TS	+	N
27,F	++	+	++	++	++	N	N	++	-
19,F	+++	+	++	++	++	N	Hypoplastic left TS	+	P
23,F	-	-	+	+	+	Slit	N	-	-
26,F	+	-	+	+	+	N	Both stenosis	TS +	-
15,F	++	+	+	+	++	N	Absent right and Stenosed left TS	TS +	-
22,F	++	-	+	+	+	N	Right stenosis	TS +	-
25,F	++	+	++	++	++	N	Both stenosis	TS +	-
16,F	+++	+	++	++	++	N	N	+	P
26,F	-	-	+	-	-	N	N	-	-
33,F	+	+	+	-	+	Slit	N	-	-
27,F	+	-	+	+	+	N	Left stenosis	TS -	-
26,F	+	-	+	-	+	N	N	+	-
14,F	+	-	+	+	+	N	N	+	-
30,F	++	+	++	++	++	N	N	+	-
38,F	++	+	+	++	++	N	N	+	-
26,M	+++	+	++	++	++	N	N	++	-
20,F	+	-	+	+	+	N	N	-	-
32,F	++	+	++	++	++	N	N	++	-
14,F	++	+	+	+	+	N	Left stenosis	TS +	N
26,F	++	+	++	++	++	N	N	+	-
30,F	++	+	++	++	++	N	N	+	-

*[Ratio between ON sheath (ONS) and ON is usually 2:1; here the ratio was between 2:1 to 2.5:1, considered as grade-1 distension (+), when the ratio was between 2.5:1 to 3:1, considered as grade -2 distension (++) and when the ratio was > 3:1, considered as grade-3 distension (+++). The ratio was calculated at the site of maximum distension.*

**Horizontal tortuosity of ON:** for mild to moderately marked tortuosity: + and for more marked Tortuosity: ++

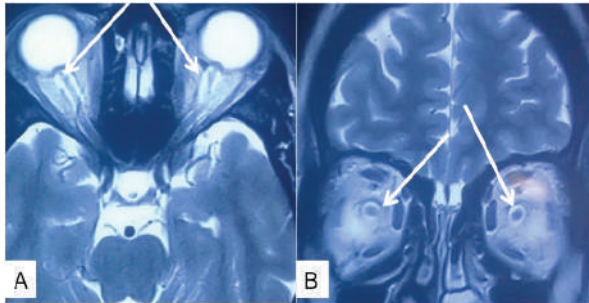
**Posterior globe flattening, Optic nerve head protrusion in globe and Empty sella:** marked: + and more marked: ++

**Post operative MRI:** Not done:- ; done with normal finding: N and done with persistent findings in lesser form: P

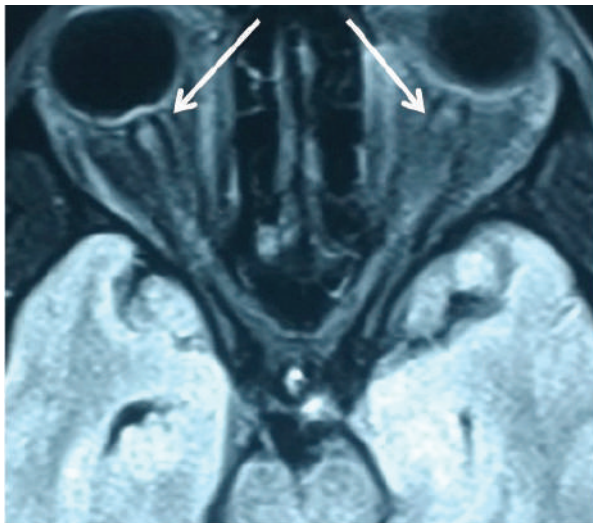
**Ventricular size:** normal: N

**MRV findings:** TS-transverse sinus normal: N]

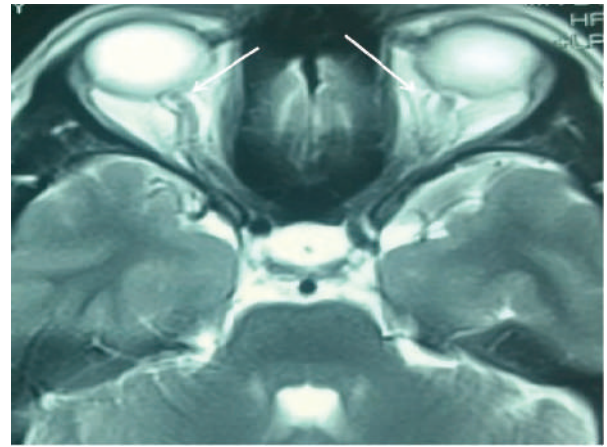
Posterior globe flattening was found in all 24(100%) cases and in 12(50%) cases it was more marked than the rest of the cases. Vertical buckling of optic nerve was found in 15(62.5%) cases. Horizontal tortuosity of optic nerve was negligible in 02(8%) cases whereas it was marked in 11(46%) cases and more marked in another 11(46%) cases. Optic nerve head protrusion was negligible in 03(12.5%) cases, mild to moderate in 09(37.5%) cases and more marked in 12(50%) cases. (Fig 1-6)



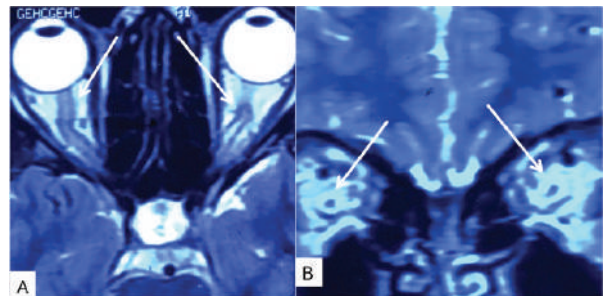
**Fig 1: Preoperative MRI of brain and orbit T2W A - axial image and B - coronal image showing huge ON sheath distension, flattening of globe, protrusion of ON head in globe, tortuosity of ON (arrow marked) and also empty sella.**



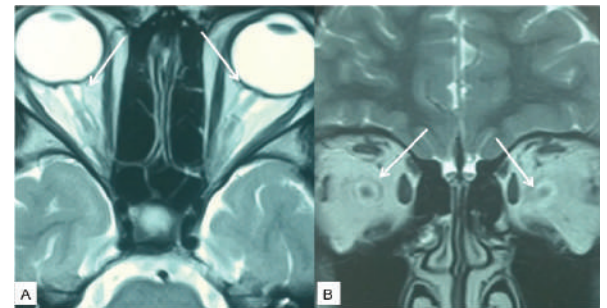
**Fig 2: MRI of brain and orbit FLAIR axial image showing expanded subarachnoid spaces around the ON with flattening of globes posteriorly as well as protrusion of ON head in globes (arrow marked).**



**Fig 3: Preoperative MRI of brain and orbit T2W axial image showing huge ON sheath distension, flattening of globe, protrusion of ON head in globe, tortuosity of ON (arrow marked) and also empty sella in IIIH.**

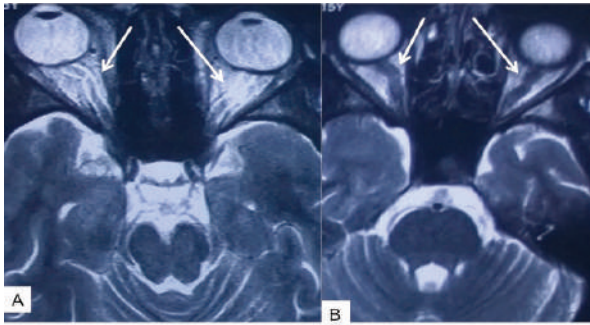


**Fig 4: Preoperative MRI of brain and orbit T2W images; A - axial image showing prominent axial tortuosity (angulation) of ON (arrow marked) and also empty sella. and B - coronal images showing prominent ON sheath distension (arrow marked).**



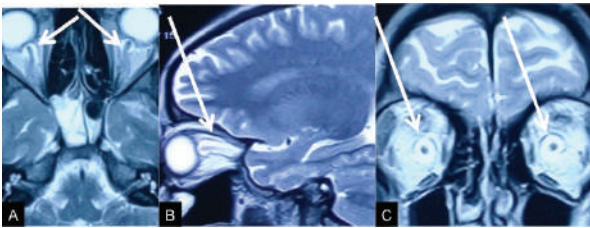
**Fig 5: Preoperative MRI of brain and orbit T2W images; A - axial and B - coronal images showing ON sheath distension, flattening of globe, protrusion of ON head in globe, tortuosity of ON (arrow marked) and also empty sella in IIIH.**



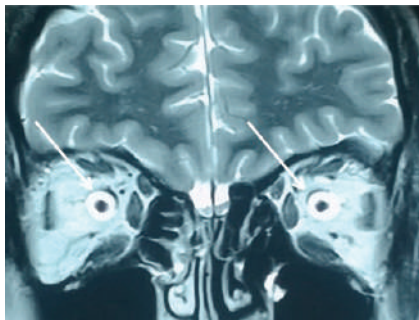


**Fig 6: Preoperative MRI of brain and orbit T2W images; A and B - axial images showing ON sheath distension, flattening of globe, protrusion of ON head in globe, tortuosity of ON (arrow marked) and also partial empty sella in IIIH.**

Significant optic nerve sheath distension was not found in 03(12.5%) cases. Mild to moderate distension (grade-1/+) was found in 07(29%) cases and moderate to severe (grade-2/++) distension found in 11(46%) cases whereas severe distension (grade-3/+++) found in 03(12.5%) cases. (Fig 7,8)

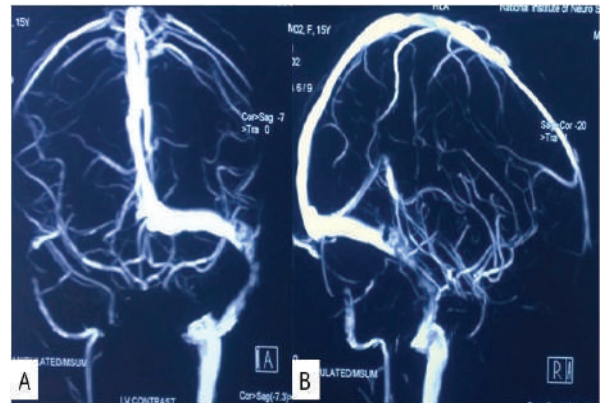


**Fig 7: Preoperative MRI of brain and orbit T2W images; A – axial, B - sagittal and C - axial images showing clear demonstration of huge ON sheath distension, flattening of globe, protrusion of ON head in globe, tortuosity (vertical & axial) of ON (arrow marked) and also partial empty sella in IIIH.**

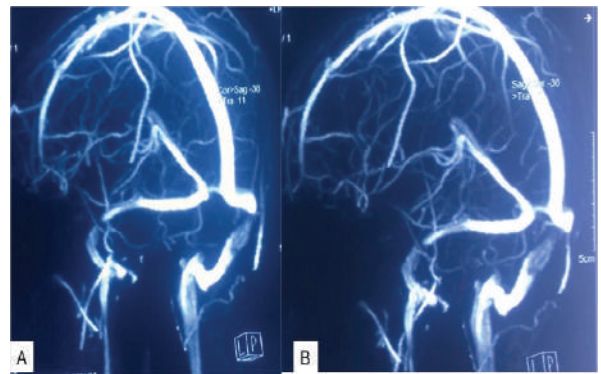


**Fig 8: Preoperative MRI of brain and orbit T2W image coronal images showing huge, clear and nice demonstration of ON sheath distension in IIIH.**

Ventricular size was normal in 22(92%) cases and slit ventricle was found only in 02(8%) cases. On MRV one sided transverse sinus stenosis/occlusion/ aplasia/ significant hypoplasia found 06(25%) cases (05 left and 01 right) [Fig 9]. Bilateral stenosis of TS in 02(8%) cases and one-sided stenosis and other sided occlusion was found in 01 case. MRV was normal in 15(62.5%) cases. (Fig 10)

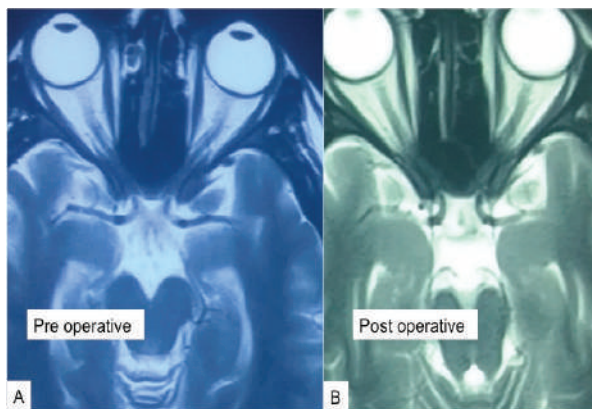


**Fig 9: MRV of brain showing; A & B - absence of left transverse sinus (TS) and stenosis of right TS in IIIH.**



**Fig 10: MRV of brain showing; A & B - bilateral stenosis of TS in IIIH.**

Empty sella was found in 19(79%) cases, more marked in three cases. Postoperative MRI was done in 05(21%) cases where finding was normal in 03 cases and in rest of the cases findings were persistent with lesser form than the preoperative form. (Fig 11)



**Fig 11: MRI of brain and orbit T2W axial images. A - preoperative, showing ON kinking and ON sheath distension. B - postoperative, showing decreased kinking of ON and distension of ON sheath.**

## Discussion

Studies of American populations have shown that the incidence of IIH ranges from 0.9 to 1.0/100,000. This incidence rises to 1.6-3.5/100,000 in women and 7.9-19.0/100,000 in women who were overweight.<sup>9,10</sup> Peak incidence is seen amongst 15-40 years of age. Clinical features of IIH include headache, tinnitus, nausea, vomiting or dizziness, blurring or diminishing of vision, double vision (diplopia) and neck pain.<sup>9</sup>

Among many imaging techniques, MRI has fascinating role due to its ability of visualization of the globe, optic nerve, orbits and optic tract. Moreover, it provides higher soft-tissue contrast and free section orientation. It is more accurate in examining the optic nerve than ultrasonography.<sup>11</sup> The T2-weighted image sequence with fat-suppression has been seemed to be optimal for visualizing the optic nerves and peri-optic CSF.<sup>10</sup> Coronal images are optimal for visualizing the true dimensions of the optic nerve and peri-optic CSF in relation to the surrounding optic sheath.<sup>9,11</sup>

Raised ICP may lead to several abnormal findings on MRI, including the following<sup>9</sup> -

1. Empty sella.
2. Flattening of the posterior sclera.
3. Distension of the perioptic sub arachnoid space (SAS).
4. Intraocular protrusion of the prelaminar ON.
5. Vertical tortuosity of the orbital ON.
6. Enhancement of the prelaminar ON.

The optic nerve sheath (ONS) diameter can be calculated by measuring the outer diameter of the SAS. The normal diameters of ONS immediately posterior and 4 mm posterior to the eyeball are  $5.52 \pm 1.11$  mm and  $5.2 \pm 0.9$  mm, respectively.<sup>12</sup> Because all CSF spaces communicate freely, the pressure and composition of the CSF is thought to be the same throughout the CNS. In the SAS of the ON, CSF flows from the chiasmatic cistern into the intraorbital portion of the ON, through the canalicular portion. Increased intracranial pressure can be seen as prominent subarachnoid space along the ON.<sup>13</sup>

The optic nerve head is considered to be the site most vulnerable to the effects of elevated ICP. Usually, the papilla appears as a flat hyperintense (hypointense relative to the vitreous of the globe) area in the posterior sclera. In IIH intraocular protrusion of the optic nerve head is sometime observed on MRI. Pre-laminar enhancement is seen in 50% of MRI of IIH patients.<sup>9,14</sup>

The orbital part of the ON was studied in patients at different stages of papilledema and the ONS diameter was seen to be larger compared with that in healthy person.<sup>13</sup> MRI had been used to evaluate the effectiveness and efficacy of treating elevated ICP with ONSF by studying the optic sheath enlargement. The findings supported that the ONS diameter was a strong indicator of increased ICP.<sup>12</sup> In literature several studies had showed posterior scleral flattening in patients with increased ICP.<sup>9</sup>

Optic nerve elongation, kinking or tortuosity has also been accompanied with raised ICP. The tortuosity of ON in patients with raised ICP is due

to the fixated distal and proximal points of the ON. The sensitivity of finding of ON tortuosity in either the vertical or horizontal axis also depends on slice distant. The vertical component of tortuosity, which needs a greater deflection of the ON to be seen on axial images, retains a greater specificity value. The ON vertical tortuosity is often associated with a "smear sign," in which the mid portion of the ON appears unseen by a "smear" of fat on T1-weighted images. The eyeball puts pressure to the distal part of the ONS, which results in kinking of the enlarged ONS.<sup>9</sup>

In IIH, all neuroimaging findings except for intraocular protrusion of the optic disc have been seemed to be highly significant for the presence of raised ICP.<sup>14</sup>

Brodsky and Vaphiades found flattening of the posterior sclera in 80% cases, empty sella in 70%, distension of the perioptic SAS in 45% and enhancement of prelaminar ON in 30% of their cases.<sup>15</sup> Posterior scleral flattening and prelaminar enhancement are thought to be confirmatory for papilledema, whereas distension of the peri-ONS or empty sella is only suggestive for raised ICP.<sup>14</sup>

Previous studies have described a higher frequency of several orbital and sellar findings in patients with IIH than in control subjects. Brodsky and Vaphiades<sup>15</sup> in a group of 20 IIH patients found that flattening of the posterior sclera, enhancement of the pre-laminar ON, distention of the peri-optic subarachnoid space, intraocular protrusion of the pre-laminar ON, and vertical tortuosity of the orbital ON, as well as an "empty" sella, were all present at significantly higher rates in IIH patients than in control subjects; these findings were seen in fewer than 5% of the control subjects. In 30 patients with IIH, Agid et al.<sup>16</sup> found similar significantly higher frequencies of these findings, but they concluded that only flattening of the posterior aspect of the globes, if present, was clinically useful for strongly suggesting the diagnosis of IIH. Maralani et al.<sup>15,17</sup> found that an empty sella turcica and posterior globe flattening were both highly specific for IIH in a study of 43 IIH patients and 43 control subjects.

Cerebral venous sinus thrombosis/stenosis is an important cause or effect of intracranial hypertension and it can be seen in 14-90% patients of IIH. So MRV should be done in all suspected cases of IIH.<sup>18</sup> The presence of transverse sinus (TS) stenosis may be useful in the diagnosis of IIH but TS stenosis is not a good predictor of vision loss, and it does not appear that its presence or absence should guide specific management.<sup>15</sup>

Although these findings are common among IIH patients and are indeed suggestive of elevated ICP, none of these imaging findings are specific for IIH.<sup>15</sup>

## References

1. Hingwala DR, Kesavadas C, Thomas B, Kapilamoorthy TR, Sarma PS. Imaging Signs in Idiopathic Intracranial Hypertension: Are These Signs Seen in Secondary Intracranial Hypertension Too? *Ann Indian Acad Neurol.* 2013;16(2):229-33.
2. Dandy WE. Intracranial Pressure without Brain Tumor: Diagnosis and Treatment. *Ann Surg.* 1937;106:492-513.
3. Smith JL. Whence Pseudotumor Cerebri? *J Clin Neuroophthalmol.* 1985;5:55-56.
4. Friedman DI, Jacobson DM. Diagnostic Criteria for Idiopathic Intracranial Hypertension. *Neurology.* 2002;59:1492-95.
5. Rohr A, Dörner L, Stingele R, Buhl R, Alfke K, Jansen O. Reversibility of Venous Sinus Obstruction in Idiopathic Intracranial Hypertension. *AJNR.* 2007;28:656-59.
6. Lim MJ, Pushparajah K, Jan W, Calver D, Lin JP. Magnetic Resonance Imaging Changes in Idiopathic Intracranial Hypertension in Children. *J Child Neurol.* 2010;25:294-99.
7. Suzuki H, Takanashi J, Kobayashi K, Nagasawa K, Tashima K, Kohno Y. MR Imaging of Idiopathic Intracranial Hypertension. *AJNR.* 2001;22:196-99.
8. Vaghela V, Hingwala DR, Kapilamoorthy TR, Kesavadas C, Thomas B. Spontaneous Intracranial Hypo and Hypertensions: An Imaging Review. *Neurol India.* 2011;59:506-12.



9. Thakkar DK, Patil A, Thakkar D, Patil P, Jantre MN. Magnetic Resonance Imaging in Pseudotumor Cerebri: A Case Report. *Med J DY Patil Univ.* 2014;7:802-805.
10. Abdelghaffar H. Vestibular Abnormalities in Pseudotumor Cerebri. *Mediterr J Otol.* 2006;2:58-62.
11. Seitz J, Held P, Strotzer M, Müller M, Völk M, Lenhart M, et al. Magnetic Resonance Imaging in Patients Diagnosed with Papilledema: A Comparison of 6 Different High-Resolution T1- and T2(\*)-Weighted 3-Dimensional and 2-Dimensional Sequences. *J Neuroimaging.* 2002;12:164-71.
12. Mashima Y, Oshitari K, Imamura Y, Momoshima S, Shiga H, Oguchi Y. High-Resolution Magnetic Resonance Imaging of the Intraorbital Optic Nerve and Subarachnoid Space in Patients with Papilledema and Optic Atrophy. *Arch Ophthalmol.* 1996;114:1197-203.
13. Watanabe A, Kinouchi H, Horikoshi T, Uchida M, Ishigame K. Effect of Intracranial Pressure on the Diameter of the Optic Nerve Sheath. *J Neurosurg.* 2008;109:255-58.
14. Eliseeva NM, Serova NK, Arutiunov NV. Magnetic Resonance Imaging of the Orbital Portion of the Optic Nerve at Different Stages of Papilledema. *Vestn Oftalmol.* 2005;121:5-9.
15. Brodsky MC, Vaphiades M. Magnetic Resonance Imaging in Pseudotumor Cerebri. *Ophthalmology.* 1998;105:1686-93.
16. Saindane AM, Bruce BB, Riggeal BD, Newman NJ, Bioussé V. Association of MRI Findings and Visual Outcome in Idiopathic Intracranial Hypertension. *American Journal of Roentgenology.* 2013;201:412-18.
17. Agid R, Farb RI, Willinsky RA, Mikulis DJ, Tomlinson G. Idiopathic Intracranial Hypertension: the Validity of Cross-Sectional Neuroimaging Signs. *Neuroradiology.* 2006;48:521-27
18. Maralani PJ, Hassanlou M, Torres C, Chakraborty S, Kingstone M, Patel V, et al. Accuracy of Brain Imaging in the Diagnosis of Idiopathic Intracranial Hypertension. *Clin Radiol.* 2012;67:656-63.
19. Degan AJ, Levy LM. Pseudotumor Cerebri: Brief Review of Clinical Syndrome and Imaging Findings. *AJNR.* 2011;32:1986-93.