

## Incidental Diagnosis of Bicornuate Uterus in a Lady of 48 Years - A Case Report

Rafia Parveen<sup>1</sup>, Shaikh Shofiur Rahman<sup>2</sup>

### Abstract

*Congenital anomalies of uterus are not very uncommon. Quite a number of women with these anomalies can be totally asymptomatic. In some women, anomalies may be first detected during pregnancy or delivery. Here a case of incidentally diagnosed bicornuate uterus is reported in a lady of 48 years while being treated for breast carcinoma. The patient attended with a lump in her left breast at Delta Medical College Hospital, Dhaka, Bangladesh. She was totally asymptomatic previously and her three children were born preterm without any difficulty. Along with other investigations, abdominal ultrasonogram was done which showed two separate fundal and uterine cavities with single cervix. Bicornuate uterus was confirmed by endovaginal ultrasonogram. Breast carcinoma was treated accordingly.*

**Key words:** Bicornuate uterus; Uterine anomaly.

*Delta Med Col J. Jan 2020;8(1):46 – 50*

### Introduction

Fusion of the Mullerian ducts (or paramesonephric ducts) normally occurs between the 6th and 11th weeks of gestation to form the uterus, fallopian tubes, cervix, and proximal two-thirds of the vagina.<sup>3</sup> A bicornuate uterus can be classified as a class IV Mullerian duct anomaly that results from partial failure of fusion of the Mullerian ducts, resulting in a uterine body divided into two horns, which join just above or at the cervix.<sup>4</sup>

Accurate statistical percentage and incidence of Mullerian duct abnormality (MDA) in a population is difficult to estimate due to its rarity.<sup>5</sup> The reported prevalence of Mullerian duct anomalies varies in the literature, ranging from 1%-5% in the general population to 13%-25% among women with recurrent pregnancy loss.<sup>1</sup> Depending on the population studied and the

imaging modalities used, the prevalence of individual congenital uterine anomalies varies.

In a retrospective study on 21961 patients (from year 1998 to 2009) including 116 patients of uterine anomalies, septate uterus was highest in number, followed by uterus didelphys.<sup>5</sup> Fox et al. conducted a study on uterine anomalies, where septate uterus was the commonest anomaly and bicornuate uterus was second common.<sup>6</sup> In a study on 110 patients of Mullerian duct anomalies, septate uterus was highest in number (73) followed by bicornuate uterus (20), uterine hypoplasia (10), unicornuate uterus (4) and Mayer-Rokitansky-Küster-Hauser syndrome (3) in descending order.<sup>7</sup> In a study by Patel et al. (from 2011 to 2014) septate uterus was the commonest Mullerian duct anomaly followed by

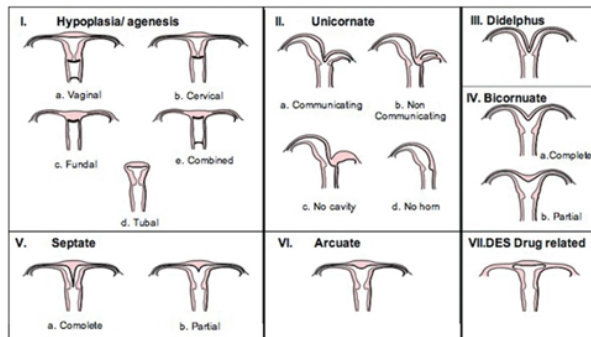
1. Associate Professor, Dept. of Radiology & Imaging, Delta Medical College & Hospital, Dhaka, Bangladesh.

2. Professor & Head, Dept. of Radiology & Imaging, Delta Medical College & Hospital, Dhaka, Bangladesh.

**Correspondence:** Dr. Rafia Parveen. e-mail: prafia08@yahoo.com

bicornuate uterus and transverse vaginal septum.<sup>8</sup> Bhuyan et al. found uterine agenesis and hypoplasia as the commonest MDA in their study<sup>9</sup>, similar to Chandrayan et al.<sup>10</sup> and Rani et al.<sup>11</sup>

The most common classification system of Mullerian anomaly is that developed by the American Society of Reproductive Medicine (Fig 1).<sup>12</sup>



**Fig 1: Classification of Mullerian duct anomaly**

Bicornuate uterus can be subdivided into<sup>3,12</sup>

- a) Bicornuate bicollis: two cervical canals; central myometrium extends to external cervical os.
- b) Bicornuate unicollis: one cervical canal; central myometrium extends to internal cervical os.

Women with bicornuate uterus may be totally asymptomatic (greater than 60%).<sup>1</sup> In some women, this condition may be unnoticed throughout their lives. The anomaly may be first detected during pregnancy or delivery.<sup>2</sup> Some women may present with cyclic or noncyclic pelvic pain and dysmenorrhea suggestive of an obstructive anomaly, retrograde menstruation, and endometriosis.<sup>13</sup>

Patients with Mullerian duct anomalies are known to have higher incidences of infertility, repeated first trimester spontaneous abortions, fetal intra-uterine growth retardation, fetal malposition, pre-term labour, retained placenta, cervical incompetence, pregnancy induced hypertension (due to associated renal abnormalities), antepartum and postpartum bleeding and perinatal mortality.<sup>13-15</sup>

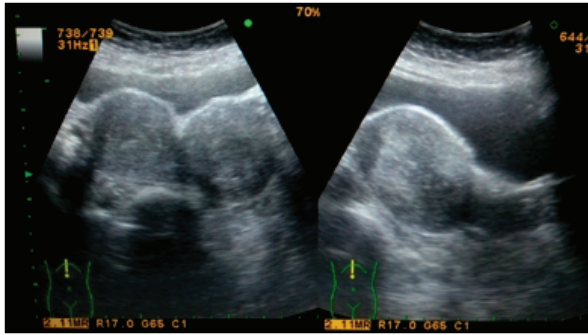
Diagnosis of Mullerian duct anomalies is done by pelvic ultrasound (US), MRI, sonohysterography or hysterosalpingography (HSG). The HSG correctly diagnoses 55% of septate and bicornuate uteri, and the addition of ultrasonography improves this result to 90%.<sup>16</sup> MRI is considered the ideal imaging modality for evaluation of MDAs.<sup>4</sup> A study on 26 cases of MDA, MR imaging demonstrated sensitivity and specificity of 100% and endovaginal sonogram demonstrated a sensitivity of 100% and a specificity of 80%.<sup>17</sup>

Mullerian duct anomaly may be associated with other genital tract anomalies, anomalies of renal tract (e.g. renal agenesis, ectopic kidney, horseshoe kidney, renal dysplasia and duplicated collecting systems), axial skeletal system (e.g. wedged or fused vertebral bodies, spina bifida), cardiac anomalies, and syndromes such as Klippel-Feil syndrome.<sup>2,4,12</sup>

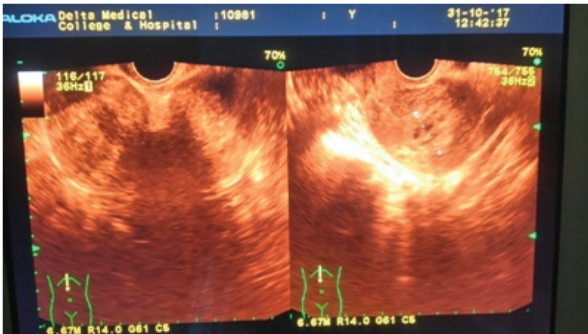
## Case report

A 48 years old lady hailing from Bogura, came to Delta Medical College Hospital, Dhaka on 27.09.16 with a lump in left breast for 3 months. She also complained of irregular periods for last 4 months. She was subsequently diagnosed with carcinoma of left breast. Bimanual pelvic examination was performed by a gynaecologist and uterus was found bulky. Abdominal ultrasonogram was done along with other relevant investigations. Whole abdomen ultrasonography suggested bicornuate uterus which was later confirmed by transvaginal sonogram. Breast carcinoma was treated by surgery followed by radiotherapy and chemotherapy.

The lady is a mother of three children. Surprisingly, all her childbirth histories were uneventful. She lives in a remote village and had never done any ultrasonography before noticing the lump in her left breast. Therefore, her bicornuate uterus remained undiagnosed for all these years. All her children were delivered at home by normal vaginal delivery without any difficulty. However, all of them were born as preterm.



**Fig 2: Abdominal ultrasonogram of the patient shows two uterine horns at transverse scan**



**Fig 3: Endovaginal ultrasonogram of the patient at transverse and longitudinal scans**

## Discussion

Uterine anomalies are congenital malformations caused by fusion or resorption defects during embryogenesis. Bicornuate uterus must be differentiated from septate one as their treatments are totally different. Several radiologic techniques are useful for evaluating congenital anomalies of the female reproductive tract. Each imaging technique has its inherent strengths and limitations; therefore a combination of several techniques may best evaluate a particular abnormality.<sup>13</sup>

Hysterosalpingography can evaluate internal uterine configuration, uterine filling defects and fallopian tube patency.<sup>12,13</sup> It allows evaluation of only the component of the uterine cavity that communicates with the cervix. Since the anatomic information is limited without the ability to evaluate the external contours of the uterine fundus, HSG has little clinical utility in confirmation of Mullerian duct anomaly and

additional exploration by means of endovaginal or three-dimensional ultrasound is recommended.<sup>3,18</sup> Ultrasonography is frequently employed in obstetric and gynaecologic evaluations, as it does not require ionizing radiation, is widely available and rapid. It effectively evaluates the internal and external uterine contour, detects a pelvic mass, hematometra or hematocolpos, confirms the presence of ovaries and assesses the kidneys.<sup>13</sup> 3D ultrasonogram of the uterus has been reported to improve depiction of the external fundal contour.<sup>3,18</sup>

Despite such improvements in US technology, significant limitations remain in diagnosing Mullerian duct anomaly subtypes, including identification of unicornuate uterus and rudimentary uterine horns.<sup>3</sup> Sometimes, the second uterine horn may mimic a fibroid.<sup>1</sup> On the other hand, MRI is an excellent noninvasive and non-ionizing modality for assessing clear anatomic detail of both uterine cavity and the external contour of the uterus.<sup>2</sup> Furthermore, MRI can identify a rudimentary uterine horn and determine if functional endometrium is present.<sup>13</sup>

At ultrasonogram, the differentiation of fusion (didelphys and bicornuate) anomalies from reabsorption (septate and arcuate) anomalies is based on the presence of a uterine fundal cleft.<sup>4</sup> The bicornuate uterus is characterized by an indented fundus. Didelphic uterus is different from bicornuate uterus in that it contains two endometrial and two cervical canals.<sup>4</sup> The septate uterus has a normal fundal contour but is characterized by a persistent longitudinal septum that partially divides the uterine cavity.

A bicornuate uterus can be identified by the presence of two well-formed uterine cornua with a convex fundal contour in each and the presence of a fundal indentation greater than 10 mm. Similar to bicornuate uterus, uterus didelphys is also characterized by the presence of a cleft (>10 mm in depth at MR imaging) in the external contour of the uterine fundus.<sup>2</sup> A septate uterus is identified by the presence of septum associated with a uniformly convex external contour or with an indentation less than 10 mm.<sup>7</sup>

Classification criteria for sonographic differentiation of bicornuate from septate uteri are as follows. When the apex of the fundal contour is more than 5 mm above a line drawn between the tubal ostia, the uterus is septate. When the apex of the fundal contour is below or less than 5 mm above a line drawn between the tubal ostia, the uterus is bicornuate.<sup>4</sup>

Although not a specific finding, the angle between the horns of the bicornuate uterus is usually not more than 105°. If the angle between the uterine cavities is less than or equal to 75°, a septate uterus is present. If the angle is larger than 75° but less than 105°, it is still probable that the uterus is septate, but sonography can rule out the possibility of a bicornuate component. If the angle is equal to or more than 105°, a bicornuate uterus is probably present.<sup>4</sup>

On identification of an MDA, radiologists should also look for associated renal and skeletal anomalies.<sup>4</sup>

Confirmation of Mullerian anomaly is important as treatment varies significantly in different anomalies. Imaging especially MRI plays an essential role in diagnosis and treatment planning of Mullerian duct anomaly. This modality provides excellent delineation of internal and external uterine contours. Surgical intervention for Mullerian anomalies is indicated in women with pelvic pain, endometriosis, obstructive anomalies, recurrent pregnancy loss, and preterm delivery. In our case the woman was undiagnosed until late in her life and she had experienced three preterm deliveries. So timely diagnosis and intervention could improve her obstetric outcome.

## References

1. Afodun AM, Quadri KK, Masud MA, Buhari MO, Lawal SK. (Ventrodorsal) Symmetrical Bicornuate Uterus Mimicking a Pedunculated Myoma - A Case Report. *Forensic Medicine and Anatomy Research*. 2017;5(4):33-38.
2. Troiano RN, McCarthy SM. Mullerian Duct Anomalies: Imaging and Clinical Issues. *Radiology*. 2004;233(1):19-34.
3. Behr SC, Courtier JL, Qayyum A. Imaging of Mullerian Duct Anomalies. *RSNA Radiographics*. 2012;32:E233-E250.
4. Ly JQ. Rare Bicornuate Uterus with Fibroid Tumors: Hysterosalpingography - MR Imaging Correlation. *AJR*. 2002;179:537-38.
5. Zhang Y, Zhao Y, Qiao J. Obstetric Outcome of Women with Uterine Anomalies in China. *Chinese Medical Journal*. 2010;123(4):418-22.
6. Fox NS, Roman AS, Stern EM, Gerber RS, Saltzman DH, Rebarber A. Type of Congenital Uterine Anomaly and Adverse Pregnancy Outcomes. *J Matern Fetal Neonatal Med*. 2014;27(9):949-53.
7. Mazouni C, Girard G, Deter R, Haumonte JB, Blanc B, Bretelle F. Diagnosis of Mullerian Anomalies in Adults: Evaluation of Practice. *Fertil Steril*. 2008;89(1):219-22.
8. Patel SN, Desai AN, Pamnani DH, Modi KP. Analysis of Mullerian Developmental Defects in a Tertiary Care Hospital: A Four Year Experience. *Int J Reprod Contracept Obstet Gynecol*. 2015;4(3):1920-22.
9. Bhuyan D, Choudhury PR, Agarwala P. Study of Mullerian Duct Anomalies Using Magnetic Resonance Imaging Technique in a Tertiary Care Hospital of Assam. *Indian Journal of Clinical Anatomy and Physiology*. 2016;3(4):531-37.
10. Chandrayan P, Parekh U, Jain N. Mullerian Duct Anomalies Presenting with Primary Amenorrhoea. *Int J Reprod Contracept Obstet Gynecol*. 2016;5(2):300-305.
11. Rani H, Nawaz S, Saif N, Usmani AT. Frequency of Mullerian Duct Abnormalities. *JRMC*. 2009;13(1):34-37.
12. Chandler TM, Machan LS, Cooperberg PL, Harris AC, Chang SD. Mullerian Duct Anomalies: from Diagnosis to Intervention. *Br J Radiol*. 2009;82(984):1034-42.
13. Rackow BW, Arici A. Reproductive Performance of Women with Mullerian Anomalies. *Curr Opin Obstet Gynecol*. 2007;19(3):229-37.
14. Shuiqing M, Xuming B, Jinghe L. Pregnancy and Its Outcome in Women with Malformed Uterus. *Chin Med Sci J*. 2002;17:242-45.
15. The American Fertility Society Classifications of Adnexal Adhesions, Distal Tubal Obstruction, Tubal Occlusions Secondary to Tubal Ligation, Tubal

- Pregnancies, Mullerian Anomalies and Intrauterine Adhesions. *Fertil Steril*. 1988;49:944-55.
16. Reuter KL, Daly DC, Cohen SM. Septate Versus Bicornuate Uteri: Errors in Imaging Diagnosis. *Radiology*. 1989;172(3):749-52.
  17. Pellerito JS, McCarthy SM, Doyle MB, Glickman MG, DeCherney AH. Diagnosis of Uterine Anomalies: Relative Accuracy of MR Imaging, Endovaginal Sonography, and Hysterosalpingography. *Radiology*. 1992;183:795-800.
  18. Braun P, Grau FV, Pons RM, Enguix DP. Is Hysterosalpingography Able to Diagnose All Uterine Malformations Correctly? A Retrospective Study. *Eur J Radiol*. 2005;53:274-79.