

## Variation of Shapes of Spleen of Bangladeshi People

Nilufar Jahan Khan<sup>1</sup>, Mohsin Khalil<sup>2</sup>, Sabina Mannan<sup>3</sup>, Seheli Zannat Sultana<sup>4</sup>, Nahaida Sultana<sup>5</sup>,  
Sharmin Akter Sumi<sup>6</sup>, Shakera Akter<sup>7</sup>, Labiba Jabeen<sup>8</sup>, Ismat Ara<sup>9</sup>

### Abstract

**Background:** Spleen is a haemo-lymph organ and belongs to the reticuloendothelial system of human body. The spleen plays a central role in the pathophysiology of several potentially severe diseases and increasing application of sophisticated procedures in radiology and surgery requires a profound knowledge of the gross and histomorphological aspects of the human spleen and also its vascular pattern. **Objective:** The present study was carried out to minimize the dependency on foreign standards and to identify the morphological changes with a view to establish a data related to spleen of Bangladeshi people. **Materials and method:** A cross sectional descriptive study was performed on 65 postmortem human spleen (34 of male and 31 of female) by purposive sampling technique and their different shapes were noted. Dissection was performed according to standard autopsy techniques. **Results:** There were variations of the shapes of the spleen, 2 were found disc shaped (3.07%), 2 were irregular (3.07%), 21 were oval (32.30%), 7 were tetrahedral (10.76%), 8 were triangular (10.76%) and 26 were wedge shaped (40.0%). **Conclusion:** From the present study, it was concluded that six types of shapes of spleen were observed, common shapes were wedge and oval shape, with less frequent occurrence of triangular and tetrahedral and few were disc and irregular. The finding of the present study will be of fundamental importance to medical teaching and also to clinicians.

**Keywords:** Spleen; Shapes of spleen; Cadaver.

*Delta Med Col J. Jan 2021;9(1):33-36*

### Introduction

The spleen is an organ found virtually in all vertebrates. In human, it is the largest lymphatic organ. It consists of a large encapsulated mass of lymphoid and vascular tissues. Spleen is highly vascular, friable and elastic, purple in colour

and moving with respiration.<sup>1</sup> Spleen filters blood by taking out worn erythrocytes. It is situated in the left hypochondrium and partly in the epigastrium between the fundus of the stomach and the diaphragm. The shape of the spleen varies

### Author information

1. Assistant Professor, Department of Anatomy, International Medical College, Gazipur, Bangladesh.
2. Professor, Department of Anatomy, Mymensingh Medical College, Mymensingh, Bangladesh.
3. Professor, Department of Anatomy, Mymensingh Medical College, Mymensingh, Bangladesh.
4. Professor, Department of Anatomy, Mymensingh Medical College, Mymensingh, Bangladesh.
5. Assistant Professor, Department of Anatomy, Khulna City Medical College, Khulna, Bangladesh.
6. Assistant Professor, Department of Anatomy, Delta Medical College, Dhaka, Bangladesh.
7. Associate Professor, Department of Anatomy, International Medical College, Gazipur, Bangladesh.
8. Assistant Professor, Department of Anatomy, Bikrampur Bhuiyan Medical College, Munshiganj, Bangladesh.
9. Assistant Professor, Department of Anatomy, Mymensingh Medical College, Mymensingh, Bangladesh.

**Correspondence:** Dr. Nilufar Jahan Khan. email: nilufarjahan.khan@yahoo.com

from slightly curved wedge to a domed tetrahedron.<sup>2</sup> The axis of spleen is oblique and it is directed downward, forward and laterally coinciding with the left tenth rib. The size and weight of the spleen vary with age and sex. In adults, it is usually 12 cm long.<sup>3-5</sup> Spleen may increase in size in many disease processes, such as idiopathic thrombocytopenic purpura, and is called splenomegally. Hypersplenism also causes splenic enlargement.<sup>6</sup> The spleen plays important roles in regard to red blood cells and the immune system. It removes old red blood cells and holds a reserve of blood which can be valuable in case of haemorrhagic shock and also recycles iron. As a part of mononuclear phagocyte system, it metabolizes haemoglobin removed from senescent erythrocytes. The spleen synthesizes antibodies in its white pulp and removes antibody coated bacteria and antibody coated blood cells by the way of blood and lymph circulation. A study found that the pulp of the spleen forms a reservoir that contains over half of the body's monocytes. These monocytes, upon moving to injured tissue, turn into dendritic cells and macrophages while promoting tissue healing. The tissue is a centre of activity of the mononuclear phagocytic system and can be considered analogous to a large lymph node parasites. During the second half of foetal life, the spleen forms red blood corpuscles. After birth, other sites take this responsibility of producing RBC. But sometimes, even in adults, spleen starts to produce RBC when there is anaemia due to destruction of bone marrow. For these reasons, the spleen demands constant attention from the anatomical, immunological and clinical point of view. The finding of the present study will be of fundamental importance to the physicians during the routine clinical examinations of the abdomen, to the surgeons while they perform surgical procedures which are related to the spleen, to the radiologists for their diagnostic procedures and of course, this knowledge is very important for anatomists during routine classroom dissection. With the above rationale in mind, aim of the present study was to

find out the anatomical variations of spleen occurring in Bangladeshi people for particular locality.

### Materials and method

This cross sectional descriptive study was performed on 65 postmortem human spleen (34 of male and 31 of female). Splens were collected from Bangladeshi cadaver of both sexes, age ranging from 6 to 60 years from autopsy laboratory of the Department of Forensic Medicine of Mymensingh Medical College, Mymensingh, Bangladesh. Dissection was performed according to standard autopsy techniques. All the collected specimens were from medico-legal cases. Samples were collected within 12 hours of death that showed no sign of putrefaction. Gross and fine dissection was carried out to study the different morphological parameters and fixed in 10% formol-saline for 24 hours for proper fixation. The present study was done with these fixed specimens inspite of some hardening and shrinking brought about by fixation.

All data collected from specimens of each cadaver were recorded in the pre designed data sheet, analysis by SPSS program and compared with the findings of other national and international studies and standard text books. Observation of different shapes of spleen was noted.



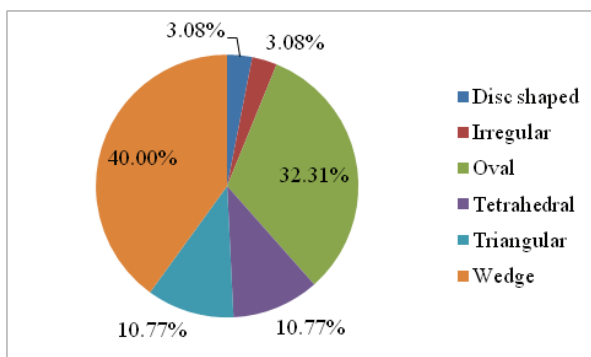
**Fig. 1: Photograph showing different shapes of spleen. a. Tetrahedral, b. Wedge, c. Triangular, d. Oval, e. Irregular, and f. Disc shaped**

## Results

There were variations of the shapes of the spleen, 2 were found disc shaped (3.07%), 2 were irregular (3.07%), 21 were oval (32.30%), 7 were tetrahedral (10.76%), 8 were triangular (10.76%) and 26 were wedge shaped (40.0%) (Table I).

**Table I: Incidence of different shapes of spleen**

Shape	Frequency	Percentage
Disc	2	3.077
Irregular	2	3.077
Oval	21	32.308
Tetrahedral	7	10.769
Triangular	7	10.769
Wedge shaped	26	40
Total	65	100



**Fig. 2: Pie Diagram showing incidence of different shapes of spleens**

## Discussion

In this study, six different shapes of spleen observed. Among those, most common was wedge shape (40.0%), followed by oval (32.30%), triangular (10.76%), tetrahedral (10.76%), disc (2.86%) and irregular (3.07%) shapes. The shape of the spleen is variable and it often appears as a slightly curved wedge.<sup>2</sup> The superolateral surface is shaped by the left dome of the diaphragm and the inferomedial aspect is shaped by the neighboring stomach, left kidney and the splenic flexure of colon. Sangeeta, Varalakshmi and Sahana<sup>7</sup> studied 53 spleens and found that 18(34%) were wedge shaped, 18(34%) were

triangular, 5(9.4%) were oval, 8(15%) were tetrahedral, 2(3.7%) were heart shaped and 2(3.7%) were semilunar but in present study heart shape and semilunar shaped spleen were not found. Chaudhury et al.<sup>8</sup> studied 62 spleens found that 21(33.87%) were tetrahedral shaped, 20(32.25%) were wedge shaped, 12(19.35%) were triangular shaped, 5(8.06%) were oval shaped and 4(6.45%) were irregular in shape. Alex et al.<sup>9</sup> studied 70 spleens in India and found that 37 were oval (52.9%), 13 had wedge shape (18.6%), 10 were triangular (14.3%) and nine were tetrahedral (12.9%). Chaware et al.<sup>10</sup> studied on 111 spleens, among them 68 were wedge shaped and 24 were tetrahedral, 14 were triangular and 4 were oval and 1 was irregular in shape. Chidambaram & Sridharm<sup>11</sup> studied 60 formalin fixed cadaveric spleens and found that 73.33% were wedge shaped, 13.33% were triangular, 6.67% were tetrahedral and 6.67% were oval shaped.

In the present study six types of shapes were observed, common shapes were wedge and oval shape, with less frequent occurrence of triangular and tetrahedral and few were disc shaped and irregular. The shape variation was nearly similar to Alex et al.<sup>9</sup>, but considerably different from those of others studies. This may be due to the different genetic factors, different geographical condition, feeding habits, socioeconomic status and body constitution.

## Conclusion

From the present study, it was concluded that six types of shapes were observed in a sample of Bangladeshi people where common shapes were wedge and oval shape, with less frequent occurrence of triangular and tetrahedral. The finding of the present study will be of fundamental importance to the physicians during the routine clinical examinations of the abdomen, to the surgeons while they perform surgical procedures which are related to the spleen, to the

radiologists for their diagnostic procedures and of course, this knowledge is very important for anatomists during routine classroom dissection.

## References

1. Chaurasia BD. Human Anatomy. Vol. 2. 7th ed. Calcutta: CBS Publishers Allied distributors; 2016. p.322-26.
2. Standring S. Gray's Anatomy: The Anatomical Basis of Clinical Practice. 39th ed. London: Churchill Livingstone; 2005. p.1239-41.
3. Sinnatamby CS. Last's Anatomy Regional and Applied. 11th ed. Edinburgh: Churchill Livingstone; 2011. p.279-82.
4. Snell RS. Clinical Anatomy by Regions. 9th ed. London: Lippincott Williams & Wilkins; 2012. p.203-205.
5. Kulkarni NV. Clinical Anatomy. 2nd ed. New Delhi: Jaypee Brothers Medical Publishers (p) Ltd; 2012. p.700-703.
6. Williams NS, Bulstrode CJK, O'Connell PR. Bailey & Love's Short Practice Surgery. 26th ed. London: Hodder Arnold; 2013. p.1089-91.
7. Sangeeta M, Varalakshmi KL, Sahana BN. Cadaveric Study of Morphometry of Spleen. Journal of Medical Sciences and Health. 2015;1(3):14-17.
8. Chowdhury AI. Gross and Histomorphological Study of Spleen in Bangladeshi People [thesis]. Mymensingh: Mymensingh Medical College; 2008.
9. Alex L, George A, Xavier B, Jacob P, Rani KD, Lakshmi GV. Morphological Variations of Human Spleen in Different Age Groups. International Journal of Health Care Sciences. 2015;3(1):122-29.
10. Chaware PN, Belsare SM, Kulkarni YR, Pandit SV, Ughade JM. The Morphological Variations of the Human Spleen. Journal of Clinical and Diagnostic Research. 2012;6(2):159-62.
11. Chidambaram RS, Sridhar, S. Morphological Variations of Spleen: A Cadaveric Study. Journal of Evidence Based Medicine & Healthcare. 2015;2(29):4248-54.