

Glanzmann Thrombasthenia – A Rare Case Report

Sabrina Rahman¹, Maha Harun², Tashmim Farhana Dipta³, Farida Parvin⁴

Abstract

Glanzmann thrombasthenia is a rare inherited bleeding disorder resulting from mutation in platelet membrane glycoprotein (GP) IIb or IIIa leading to impaired platelet function which is characterized by defective platelet aggregation and diminished clot retraction. Glanzmann thrombasthenia patients commonly visit to physician with features of bleeding. Here we discuss about the case of a 32-years-old young female presented with menorrhagia, ecchymosis and occasional gum bleeding. Her coagulation profile was in favor of Glanzmann thrombasthenia. This rare disease has a good outcome if early diagnosis and proper management can be ensured.

Keywords: Thrombasthenia; Ecchymosis; Platelet; BIRDEM.

Delta Med Col J. Jul 2021;9(2):101-103

Introduction

In 1981, Dr. Eduard Glanzmann first described Glanzmann thrombasthenia as a rare inherited bleeding disorder.¹ It is an autosomal recessive disorder that leads to failure of primary platelet aggregation. It is a familial hemorrhagic disorder that shows normal or low thrombocyte count with prolonged bleeding time due to defective platelet aggregation.^{2,3} Chance of Glanzmann thrombasthenia is about one in a million affecting both gender, predominantly female (male 40% and female 60%).⁴ Among 500 reported cases of Glanzmann thrombasthenia most commonly included ethnic groups were Arab and French Gypsies.⁵ Incidence of Glanzmann thrombasthenia is more where consanguineous marriage is common.⁶

Case report

A 32-years-old young lady presented to Transfusion Medicine & Clinical Hematology Department with menorrhagia, irregular menstrual cycle and occasional gum bleeding for few months. She has previous history of ecchymosis in both arms and back of chest. She has a strong family history of gastrointestinal malignancy and endometriosis from maternal side. She has received one unit of RCC transfusion 10 years back due to low Hb% but diagnosis was not ruled out. She had no other features of active bleeding like epistaxis, hematemesis, melaena or any spontaneous bruising. She has no familial consanguinity. Her baby had no bleeding problem. On clinical examination she was exhausted, pale, non icteric, had healthy gum, no organomegaly

Author information

1. Junior Consultant, Department of Transfusion Medicine, BIHS General Hospital, Dhaka, Bangladesh.
2. Junior Consultant, Department of Transfusion Medicine, Impulse Hospital, Dhaka, Bangladesh.
3. Professor and Head, Department of Transfusion Medicine & Clinical Haematology, BIRDEM General Hospital, Dhaka, Bangladesh.
4. Assistant Professor, Department of Transfusion Medicine & Clinical Haematology, BIRDEM General Hospital, Dhaka, Bangladesh.

Correspondence: Dr. Maha Harun. e-mail: mahaharun@gmail.com

and no sign of active bleeding. Then patient's relevant investigations were done that showed; RBC: $4.54 \times 10^6/\mu\text{L}$, Hb%: 11.5 gm/dl, HCT: 35.7%, MCV: 78.6fl, MCH: 25.5 pg, MCHC: 32.2 gm/dl, Platelet: $256 \times 10^3/\mu\text{L}$, RDW-SD: 47.2fl, RDW-CV: 17.7%, PDW: 12.4%, MPV: 11.0fl. Coagulation profile including bleeding and clotting time was within normal range. Factor VIII, fibrinogen and VWF was normal. There was absence of platelet aggregometry with ADP and collagen but normal Ristocetin cofactor activity. She has impaired glucose tolerance since last pregnancy but blood sugar was under control on diet. Her liver function test and hormonal assay reveals no significant abnormality. Following diagnosed as Glanzmann thrombasthenia she was treated conservatively in OPD department with Tab. Tranexamic Acid 500 mg due to menorrhagia. She was advised for platelet transfusion if overt uncontrolled bleeding occurs. On follow up after two weeks she was stable with normal hematological parameters.

Discussion

Glanzmann thrombasthenia is a rare, autosomal recessive, inherited hemorrhagic disease, that is characterized by prolonged bleeding time, defective platelet aggregation and reduced clot retraction.^{2,7} Responsible gene for Glanzmann thrombasthenia is carried on chromosome 17 (long arm) that codes for GP IIb/IIIa heterodimeric transmembrane cell receptor of platelet which binds with fibrinogen, vitronectin and fibronectin, are essential for platelet function (aggregation).^{1,4,8} Three subtypes of Glanzmann thrombasthenia are reported. These are Type-1 or severe with <5% of normal GP IIb/IIIa level, Type-2 or moderate with 10-20% of normal GP IIb/IIIa level and Type-3 or variant where GP IIb/IIIa levels are normal but these are functionally inactive.⁹ But, an interesting feature of Glanzmann thrombasthenia is noted that there is no correlation between the subtype of the disease and clinical severity.¹

Common presentation of Glanzmann thrombasthenia includes epistaxis, gum bleeding, bruising and menorrhagia. Bruising may be spontaneous or followed by minor injury.¹⁰ It is of great importance to diagnose Glanzmann thrombasthenia, as it is a rare disease and is often overlooked. Positive family history of consanguineous marriage has an important role in Glanzmann thrombasthenia,¹ though the present case does not give any such history. Most of the Glanzmann thrombasthenia cases presented with bleeding manifestation, are usually diagnosed in their first decades of life.⁷ Incidences of bleeding induced mortality declines as patients age.¹¹ In our case, medical history reveals endometriosis which overlapped with menorrhagia common in Glanzmann thrombasthenia. Von Willebrand disease and Bernard Soulier syndrome were considered as differential diagnoses. Normal platelet morphology and aggregometry excludes Bernard Soulier syndrome and normal coagulation profile excludes Von Willebrand disease.¹ To confirm Glanzmann thrombasthenia, light

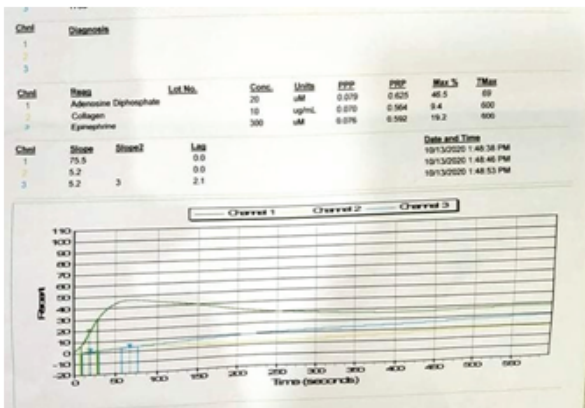


Fig. 1: Absent aggregometry with ADP

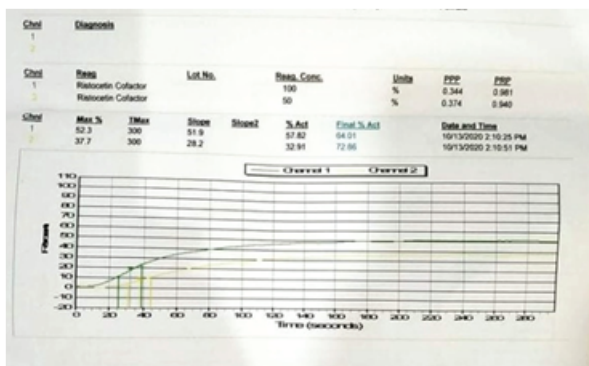


Fig. 2: Normal Ristocetin cofactor activity and collagen

transmission aggregometry is gold standard but it is time consuming and requires highly specialized facilities.⁶ Platelet function analyzer flow cytometry, hematological parameter with proper medical history is essential for diagnosis of Glanzmann thrombasthenia. A fibrinolytic agent and transfusion if needed, is adequate for management of Glanzmann thrombasthenia.⁶ In some severe cases, allogenic bone marrow transplantation gives cure of disease.¹² There are also reports that showed development of platelet antibody following platelet transfusion in some of the Glanzmann thrombasthenia cases.¹³ Consanguineous marriage should be discouraged by counseling which can reduce its incidence as it is a hereditary disorder.

Conclusion

Glanzmann thrombasthenia should be considered as a differential diagnosis while evaluating bleeding patients with normal platelet count. It has a good prognostic value in early diagnosis with prompt management. Patient's education is important to avoid any bleeding episode which may happen due to minor trauma or due to medication like NSAIDS.

Acknowledgement

We would like to express our gratitude and appreciation to all those who gave us the opportunity to complete this report. Special thanks to our mentor, Professor Salma Afrose, Ex-Honorary Senior Consultant (Haematology), Department of Transfusion Medicine and Clinical Haematology, BIRDEM General Hospital, Dhaka, to guide and advise us in writing this report.

Conflict of interest

We declare that we have no competing interests.

References

1. Venkat V, Kalluri S, Hanumantha SRB. Glanzmann Thrombasthenia – A Rare Case Report of Spontaneous Gingival Bleeding. *J Indian Acad Oral Med Radiol*. 2018;30:88-91.
2. Sebastiano C, Bromberg M, Breen K, Hurford MT. Glanzmann's Thrombasthenia: Report of Case and Review of the Literature. *Int J Clin Exp Pathol*. 2010;3(4):443-47.
3. Gopalkrishnan A, Veeraraghavan R, Panicker P. Hematological and Surgical Management in Glanzmann's Thrombasthenia: A Case Report. *J Indian Soc Pedod Prev Dent*. 2014;32(2):181-84.
4. Al Wahab A, Nugud A, Nugud S, Alras Z. Unexplained Bleeding: Case Report of Glanzmann Thrombasthenia. *Medical Student Research Journal (MSRJ)*. 2017. doi:10.15404/mstj/09.2017.0127.
5. Chang VY, Green ME, Frankel LS, Federman NC. Thrombasthenia. *Medscape* [Internet]. 2021 [cited 2021 Jan 9]. Available from: <https://emedicine.medscape.com/article/955385-overview?form=fpf>.
6. Cherian S, Thomas P, Roshni PR. A Rare Case Report on Glanzmann Thrombasthenia. *Natl J Physiol Pharm Pharmacol*. 2017;7(11):1291-92.
7. Stevens R, Meyer S, Fanconi and Glanzmann: the Men and Their Works. *British Journal of Hematology*. 2002;119(4):901-4.
8. Di Minno G, Zotz R, d'Oiron, Bindslev N, Di Minno M, Poon M. The International Prospective Glanzmann Thrombasthenia Registry, Treatment Modalities & Outcome in Non Surgical Bleeding Episode in Glanzmann Thrombasthenia Patients. 2015 August; 100(08).
9. Iore M, Nurden A, Nurden P, Seligsohn U. Clinical Utility Gene Card for: Glanzmann Thrombasthenia. *European Journal of Human Genetics*. 2012;20(10):1102.
10. Bisch FC, Bowen KG, Hanson BS, Kudryk VL, Billman MA. Dental Consideration for a Glanzmann Thrombasthenia Patient: Case Report. *J Periodontol*. 1996; 67(5):536-40.
11. George J, Caen J, Nurden A. Glanzmann Thrombasthenia: The Spectrum of Clinical Disease. *Blood*. 1990;75(7):1383-95.
12. Gobbur RH, Varghese I. A Rare Case of Glanzmann Thrombasthenia. *Int J Med Sci Public Health*. 2014;3(8):1027-28.
13. Varkey I, Rai K, Hegde AM, Vijaya MS, Oommen VI. Clinical Management of Glanzmann's Thrombasthenia: A Case Report. *J Dent (Tehran)*. 2014;11(2):242-47.