

ORIGINAL ARTICLE

Oral Atenolol Therapy in the Treatment of Infantile Hemangioma: A Prospective Study

Kh Ahsanul Kabir¹, KMN Ferdous², F Hossain³, MK Islam⁴

Abstract

Background: Infantile haemangiomas (IH) are the most common tumors of infancy with an incidence of >2% of infants in general, and of 10% of Caucasian children, in particular.

Objective: The aim of this study was to assess the efficacy and safety of atenolol in the treatment of proliferating IHs.

Methods: This prospective study was conducted among 120 patients' up to 30 months of age, clinically diagnosed with IH's in surgical outpatient department (SOPD) of the Dhaka Shishu Hospital from July 2013 to March 2018. Atenolol was started initially 0.5mg/kg. Then doses were titrated according to clinical response (0.5- 3mg/kg/day OD). Parents were instructed to interrupt the administration of the drug if the child had a serious cough with dyspnoea or gastroenteritis with vomiting or diarrhoea. Patients' were advised to come for follow up visit and in each follow up blood pressure, percentage of regression (of size), color change, complications were recorded. The change in the appearance of IH was evaluated on a visual analogue scale (VAS). Regression in the size and color clearance of IHs were evaluated according to 0%-to-100% scale.

Results: Majority of the babies were from 1-10 months age group. Most of the infants were term babies and majority of the infants were girls. Majority of the IHs were located in head and neck regions. Majority of the mothers had multiple gestation pregnancy and few had family history of IH. Excellent, good and fair colour regression was found in 74.17%, 22.50% and 3.33% participants respectively. Excellent, good and fair size regression was found in 57.50%, 38.33% and 4.17% participants respectively. Adverse effects of drug like loose motion (7.50%) and sleep disturbance (3.33%) were found among the participants.

Conclusion: Atenolol is effective in the treatment of IHs with few minor side effects.

Key words: Infantile hemangioma, atenolol, adverse effect.

Introduction

Infantile haemangiomas (IH) are the most common tumors of infancy with an incidence of >2% of infants in general, and of 10% of Caucasian children, in

particular. IH typically presents few a weeks after births, and occur more frequently in girls.¹ Many are benign and do not require treatment, but potential complications include airway obstruction, visual

1. Registrar, Department of Neonatal Surgery, Division of Pediatric Surgery, Bangladesh Institute of Child Health (BICH), Dhaka Shishu (Children) Hospital.
2. Assistant Professor, Department of Neonatal Surgery, Division of Pediatric Surgery, Bangladesh Institute of Child Health (BICH), Dhaka Shishu (Children) Hospital.
3. Data Analyst.
4. Professor and Head, Department of Neonatal Surgery, Division of Pediatric Surgery, Bangladesh Institute of Child Health and Dhaka Shishu (Children) Hospital

Correspondence to: Dr. Kh. Ahasanul Kabir, Registrar, Department of Neonatal Surgery, Division of Pediatric Surgery, Bangladesh Institute of Child Health and Dhaka Shishu (Children) Hospital. Cell: +8801552380841, E-mail: khkabar1977@gmail.com

Received: 2 May 2018; **Accepted:** 15 May 2018

compromise, disfigurement, ulceration, congestive heart failure, and death.² Previously, corticosteroids were the mainstay of treatment for complicated IHs. However, corticosteroids have undesired side effects, such as temporary growth retardation, an increased risk of infection, and behavioral changes.³ Recently, propranolol, a nonselective β -blocker, became the preferred treatment for complicated or select types of IHs.¹ Still, its use is not risk-free and many adverse events have been documented, including: hypoglycemia, bronchial obstruction, hypotension, seizures, sleep disturbances, and gastrointestinal symptoms, among others.⁴ On the other hand, atenolol, a hydrophilic cardio selective β -blocker that acts principally on β_1 receptors, does not cross the blood-brain barrier and has less β_2 effects.⁵ The aim of this study was to assess the efficacy and safety of atenolol in the treatment of proliferating IHs.

Materials and Methods

This prospective study was conducted among 120 patients up to 30 months of age, clinically diagnosed with IHs in surgical outpatient department (SOPD) of the Dhaka Shishu Hospital from July 2013 to March 2018. Patients previously treated for Infantile Hemangioma or having hemangioma presenting life threatening condition, cardiovascular disease contraindicating use of propranolol, known hypersensitivity to atenolol were also excluded from the study. Measurement of lesion was taken along long axis and another one perpendicular to this axis in centimeters with flexible soft rubber tape. Photograph was taken with digital camera. These photographs were taken prior to the treatment (baseline) and after the start of treatment at 2-8 weeks and 11-24 weeks. The change in the appearance of IH was evaluated on a visual analogue scale (VAS). The VAS uses a 100-mm scale on which -100 represented a doubling in the size and extent of the IH, 0 represented no change/baseline and +100 represented complete disappearance.⁶ Atenolol was started initially 0.5mg/kg. Then doses were titrated according to clinical response (0.5- 3mg/kg/day OD). If no relevant adverse effects were detected after administration and if this was well tolerated, treatment was continued. Parents were instructed to interrupt the administration of the drug if the child had a serious cough with dyspnea or gastroenteritis with vomiting or diarrhoea. They were also advised to call the investigator over phone for any adverse effects. Patients were advised to come for follow up visit at 2nd week, 1st month, 2nd month, 4th month, 6th month and 8th month. In each follow up blood pressure,

percentage of regression (of size), color change and complications were recorded.

Regression in the size and color clearance of IHs were evaluated according to 0%-to-100% scale. An excellent response denotes 80% to 100% regression or color clearance. A good response denotes 50% to 80%. A fair response denotes 25% to 50% and finally a poor response denotes 25% or less.⁷

Frequency distributions for categorical variables were used to describe the characteristics of the total sample. The findings of the study were presented by frequency, percentage in tables and graphs.

Results

Majority of the babies were from 1-10 months age group. Most of the infants were termed babies and majority of the infants were girls. Majority of the IHs were located in head and neck regions. Majority of the mothers had multiple gestation pregnancy and few had family history of IH (table I). Excellent, good and fair colour regression was found in 74.17%, 22.50% and 3.33% participants respectively (figure 1). Excellent, good and fair size regression was found in 57.50%, 38.33% and 4.17% participants respectively (figure 2). Adverse effects of drug like loose motion (7.50%) and sleep disturbance (3.33%) were found among the participants (table II).

Table I

Base line characteristics of the participants (n=120)

Characteristics	n (%)
Age (in months)	
1-10 months	69(57.50)
11-20 months	38(31.67)
>20 months	13(10.83)
Term baby	110(91.67)
Female	82(68.33)
IH in head and neck region	81(67.5)
Multiple gestation pregnancy	85(70.83)
Family history of IH	5(4.17)

Table II

Adverse effect of drugs (n=120)

Adverse effect	n (%)
Loose motion	9(7.50)
Sleep disturbance	4(3.33)

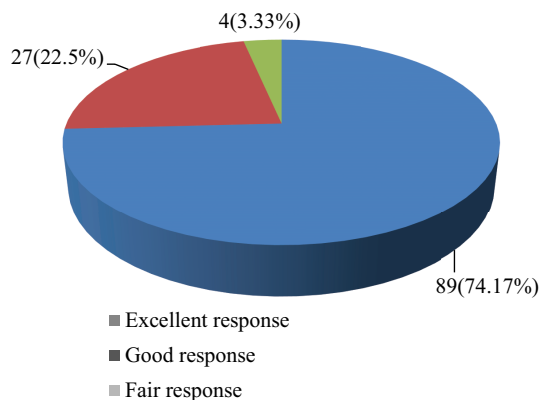


Fig 1 Regression of color of IH

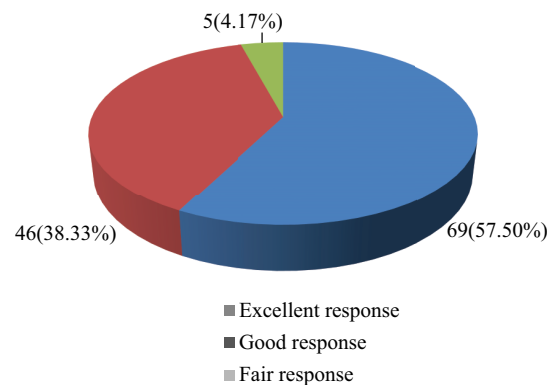


Fig 2 Regression of size of IH

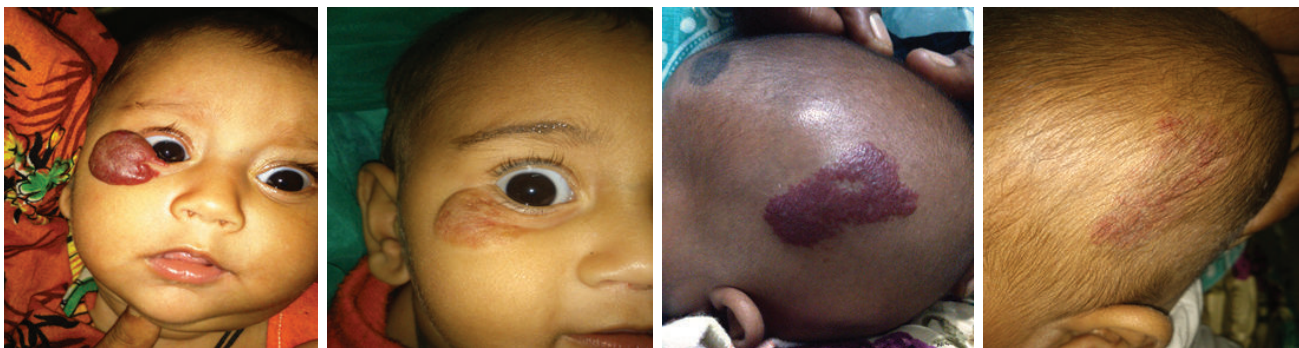


Fig 3 Pre treatment and 6 months post treatment with atenolol

Discussion

Infantile hemangiomas (IHs), also known as “hemangiomas of infancy,” are common benign tumors of endothelial cells characterized by a unique pattern of rapid proliferation that occurs in the first months of life.

Infertility (IHs) are more common among female infants, however, although older data suggest female to male ratios ranging from 3:1, more recent studies suggest a range of 1.4:1 to 3:1.^{2,11} Similar result found in the current study where it was found that majority of the participants were female. The present study also that most of the infants were termed baby and product of multiple gestations. Other study also reported that infants with hemangiomas are more likely to be female, premature, and products of multiple gestations.¹² Hemangioma can be found in all regions of the baby, but they occur most commonly in the head and region (60%), followed by the trunk (25%) and then the extremities (155).¹³ Majority of the infants (67,5%) of the current study also had His located in the head and neck regions.

The first noticeable effects on treatment were the changes in color and softening of His, followed by

regression of their sizes, Color regression of IH was determined by blind investigator using digital photograph. The photographs were taken prior to be treatment, after the start of treatment at 4 months and at 8 months. Excellent colour regression was found in 74.17% infants, Excellent size regression was found in 57.50% infants. This result was consistent with other studies. 14,15 Abraz, ua-Araya et al. had conducted a prospective comparative study to evaluate the effectiveness of atenolol against propranolol for the treatment of His where they reported that patients treated with atenolol had a complete response of 53.8%.¹⁴ The study of Jiet al. evaluated the efficacy and safety of atenolol in the treatment of proliferating His. They observed an “excellent” treatment response (complete or nearly complete resolution of the IH) in 56.5% of patients at week 24.¹⁵

Clinical studies that addressed the adverse effects of atenolol children with IH have generated conflicting results. In a study by Abarzua-Araya et al¹⁴ the authors should no significant adverse event in atenolol

treatment during the 6-month follow up. In the present study, any adverse events were recorded by parents between study visits and were documented by investigations at each visit. Among the 120 infants, few developed minor adverse effects like loose motion (7.50%) and sleep disturbance (3.33%). No patients developed any major adverse effects. In the study of de Grannf M, et al⁴ mild side effects occurred in 40% (12/30) of patients and severe side effects occurred in 3% (1/30). Other study most common side effects of atenolol in the treatment of IHs were diarrhea, followed by central nervous system effects.¹⁵ These minor side effects occurred in the present study were treatment and ceased after cessation of the drug.

Conclusion

Atenolol is effective in the treatment of IHs with few minor side effects.

References

1. Léauté-Labrèze C, de la Roque ED, Hubiche T, Boralevi F, Thambo JB, Taïeb A. Propranolol for Severe Hemangiomas of Infancy. *N Engl J Med* 2008; **358**(24): 2649-51.
2. Haggstrom AN, Drolet BA, Baselga E, Chamlin SL, Garzon MC, Horii KA, et al. Prospective study of infantile hemangiomas: clinical characteristics predicting complications and treatment. *Pediatrics* 2006; **118**:827-82.
3. George ME, Sharma V, Jacobson J, Simon S, Nopper AJ. Adverse effects of systemic glucocorticosteroid therapy in infants with hemangiomas. *Arch Dermatol* 2004; **140**(8): 963-69.
4. De Graaf M, Breur JM, Rapha ·el MF, Vos M, Breugem CC, Pasmans SG. Adverse effects of propranolol when used in the treatment of hemangiomas: a case series of 28 infants. *J Am Acad Dermatol* 2011; **65**: 320-27.
5. Ratnasamy C, Rossique-Gonz_alez M, Young ML. Pharmacological therapy in children with atrioventricular reentry: which drug? *Curr Pharm Des* 2008; **14**: 753-61.
6. Lonergan MH, Olivera-Figueroa LA, Pitman RK, Brunet A. Propranolol's effects on the consolidation and reconsolidation of long-term emotional memory in healthy participants: a meta-analysis. *J Psychiatry Neurosci* 2013; **38**(4): 222-31.
7. Pope E, Krafchik BR, Macarthur C, Stempak D, Stephen D, Weinstein M, et al. Oral versus high dose pulse corticosteroids for problematic infantile hemangiomas: a randomized, controlled trial. *Pediatrics* 2007; **119**(6): e1239-47.
8. Bruckner AL, Frieden, I.J. Infantile hemangiomas. *J Am Acad Dermatol* 2006;**55**(4):671-82.
9. Shayan YR, Prendiville JS, Goldman RD. Use of propranolol in treating hemangiomas. *Can Fam Physician* 2011; **57**(3): 302-03.
10. Bayart CB, Tamburro JE, Vidimos AT, Wang L, Golden AB. Atenolol Versus Propranolol for Treatment of Infantile Hemangiomas During the Proliferative Phase: A Retrospective Noninferiority Study. *Pediatr Dermatol* 2017; **34**(4): 413-21.
11. Hoornweg MJ, Smeulders MJ, Ubbink DT, van der Horst CM. The prevalence and risk factors of infantile haemangiomas: a case-control study in the Dutch population. *Paediatr Perinat Epidemiol* 2012; **26**(2): 156-62.
12. Haggstrom AN, Drolet BA, Baselga E. Hemangioma Investigator Group. Prospective study of infantile hemangiomas: demographic, prenatal, and perinatal characteristics. *J Pediatr* 2007; **150**(3): 291-94.
13. Zheng JW, Zhang L, Zhou Q, Mai HM, Wang YA, Fan XD, et al. A practical guide to treatment of infantile hemangiomas of the head and neck. *Int J Clin Exp Med* 2013; **6**(10): 851-60.
14. Abarz_ua-Araya A, Navarrete-Dechent CP, Heusser F, Retamal J, Zegpi-Trueba MS. Atenolol versus propranolol for the treatment of infantile hemangiomas: a randomized controlled study. *J Am Acad Dermatol* 2014; **70**(6): 1045-49.
15. Ji Y, Wang Q, Chen S, Xiang B, Xu Z, Li Y, et al. Oral atenolol therapy for proliferating infantile hemangioma: a prospective study. *Medicine (Baltimore)* 2016; **95**: e3908.