

CASE REPORT

Cutis Laxa Syndrome: A Rare Genetic Disorder of Elastolysis

Md. Mizanur Rahman¹, AKM Tajuddin Bhuiyan², Md. Atiqul Islam³

Introduction

Cutis laxa is a heterogeneous group of disorders with variable phenotypes and inheritance pattern¹. Incidence is 1 in every 2 million babies, it may be acquired or inherited forms. Include autosomal dominant CL (ADCL); autosomal recessive CL (ARCL) I, IIA, IIB, Urban-Rifkin-Davis Syndrome (URDS); Macrocephaly-alopecia-CL-Scoliosis (MACS) syndrome, arterial tortuosity Syndrome (ATS) or X-Linked CL (XLCL).² ARCL has most commonly reported particularly II, Cutis laxa (elastolysis) affect person of all races. Male and female affect equally.

Autosomal recessive has earlier presentation, Autosomal dominant form has a later onset, acquired cutis laxa may develop at any age, but often be appeared in adult hood.

The cutis laxa is diagnosed by physician on the basis of clinical feature. Inherited form ADCL may present from birth to early adult hood with predominantly skin findings.³⁻⁵ Patients have loose inelastic redundant skin that typically worsen with age, characteristic facial features include an aged appearance, long philtrum, large fore head, large ear lobes and broad nose.⁶

Systemic manifestation can have from mild to severe cardiac and pulmonary complication, such as bronchiectasis and emphysema, aortic aneurysm, severe congestive lung disease and pulmonary artery disease.⁷ Approximately 30% of patient with ADCL have denovo mutations with no family history.

ARCL Type-I: Clinical findings, manifestations of ARCL-I began at birth with abnormal faces, redundant fold around the face and neck and aged appearance.⁸⁻¹⁰ Compared with ADCL, ARCL-I is more often associated with emphysema and diaphragmatic defect, arterial tortuosity and aneurysms^{9,11,12} joint laxity and muscular hypotonia. Patient die from pulmonary or cardiac complications in early child hood.^{9,11,12} Joint laxity and muscular hypotonia is also observed. Mental and motor development usually normal.^{8,13,14} Some case of ARCL-I results from FBLN5 or FBLN4 mutation.

ARCL Type IIA: Include more frequent motor nervous system abnormalities, cardiovascular abnormalities, patent anterior fontanel and female predominance. Microcephaly, hypotonia, seizures, myopia neurodegeneration and Dandy-Walker malformation are also associated with this variety.^{15,16}

ARCL Type IIB: Features of ARCL-IIB Overlap those of progeria osteodysplasticum, ARCL-IIA/wrinkled skin syndrome and De Barys syndrome (DBS).¹⁷⁻¹⁹

ARCL Type III (DBS): DBS is also known as ARCL-III progeroid syndrome of De Barys, or CL-corneal clouding- mental retardation syndrome.²⁰

Acquired CL: Acquired CL (ACL) is a rare disorder with insidious onset that most often occurs in adulthood and may be associated with various conditions and drugs.^{21,22}

1. Associate Professor & Head, Department of Infectious Diseases and Community Pediatrics, Bangladesh Institute of Child Health (BICH), Dhaka Shishu (Children) Hospital, Bangladesh
2. Registrar, Department of Infectious Diseases and Community Pediatrics, Dhaka Shishu (Children) Hospital, Bangladesh
3. Assistant Professor Department of Infectious Diseases and Community Pediatrics, Bangladesh Institute of Child Health (BICH), Dhaka Shishu (Children) Hospital, Bangladesh

Correspondence to: Dr. Md. Mizanur Rahman, Associate Professor & Head, Department of Infectious Diseases and Community Pediatrics, Dhaka Shishu (Children) Hospital, Bangladesh. Cell: 01819490177, E-mail: mizandsh@yahoo.com

Received: 3 February 2018; **Accepted:** 7 March 2018

Case summary

Samia, 16 months old female child second issue of consanguineous parents admitted to Dhaka Shishu (Children) Hospital, with characteristics facial features including age appearance with sagging jaws, a hooked nose with everted nostrils, a short columella, along with upper lips and everted lower eyelids and downwards slanting palpebral fissures, a broad flat nose and large ears (Fig 1). Her birth and development were normal and past history was negative except for an episode of pneumonia at the age of 4 months and was treated on an inpatient basis at another hospital. The family history was negative for any individuals with a similar appearance or any unusual deaths during infancy or childhood.

We have done skin biopsy (Fig 2) which revealed epidermis is thin and mild hyperkeratosis. The dermis revealed a decrease in the number, fragmentation, and disorderly arrangement of connective tissue fibers especially elastic fibers. Few lymphocytes infiltrations are noted in the upper dermis.

We have done chest X-ray and Echocardiogram to evaluate complications, but the reports revealed normal findings.

Cutis Laxa Syndrome

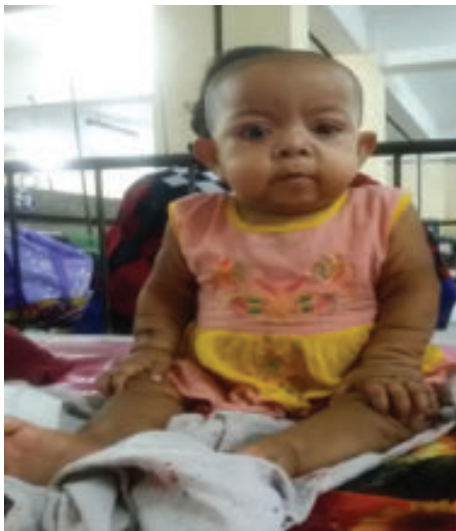

Fig 1 *Cutis Laxa syndrome, samia 16 month, note redundancy of skin folds sagging jaws, a hooked nose with everted nostrils, a short columella, along upper lips and everted lower eyelids and downwards slanting palpebral fissures, a broad flat nose and large ears.*

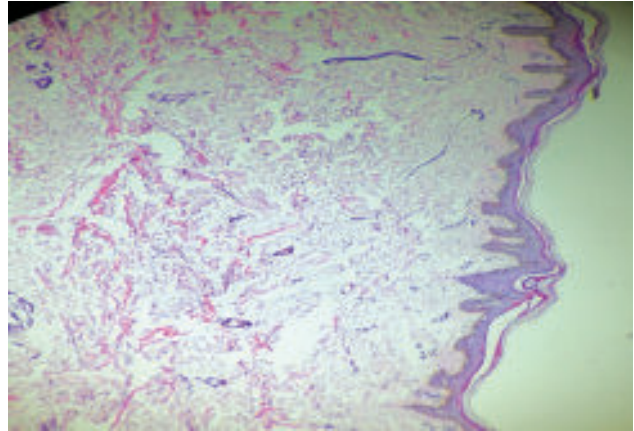


Fig 2 *Histopathology slide picture of skin biopsy*

Discussion

Cutis laxa (CL), or elastolysis, is a rare, inherited or acquired connective-tissue disorder in which the skin becomes inelastic and hangs loosely in folds. Patients develop a prematurely aged appearance.

The clinical presentation and the mode of inheritance show considerable heterogeneity. Autosomal dominant, autosomal recessive, and X-linked recessive patterns have been need in inherited forms. A serine to proline amino acid substitution in the fibulin5 (*FBLNS*) gene has been associated with problems in normal elastogenesis, resulting in a dominant form of cutis laxa (elastolysis) in humans.

Autosomal recessive cutis laxa is a genetically heterogeneous condition. A combined disorder of N- and O-linked glycosylation has been described in children with congenital cutis laxa in association with severe central nervous system involvement, brain migration defects, seizure, and hearing loss.

The X-linked form is currently classified in the group of copper transport disease. The precise cause is unknown, but it may be due to abnormal elastin metabolism resulting in markedly reduced dermal elastin content. Autosomal dominant congenital cutis laxa (ADCL) is genetically heterogeneous and shows clinical variability. Mutation in the elastin gene (*ELN*) have been described.

In both the inherited type and the acquired type, the internal organs are frequently involved. Cutis laxa (elastolysis) may be preceded by an inflammatory rash, such as urticaria, or it may develop spontaneously.

Cutislaxa (elestolysis) affects person of all races and affects men and women equally. The autosomal dominant form has a later onset than the autosomal recessive form. Acquired cutis laxa (elestolysis) may develop at any age, but it often begins in adulthood.

Treatment and prognosis of cutis laxa vary depending on the specific type of the disorder and the individual case Treatment generally involves ongoing care and monitoring by a variety of specialists, such as a cardiologist, dermatologist, internits, geneticist and pulmonologist. People with the form of cutis laxa only affects the skin may be able to live a normal lifespan. Complications, such as ruptured aortic aneurysm and corpulmonale can be fatal.

Treatment for Cutis laxacont: Sometimes plastic surgery can often improve the appearance of the skin, although the improvement may only temporary.^{23,24}

The lifespan of some patients with cutis laxa (elestolysis) may be significantly decreased, Patients with the autosomal dominant form have a normal life expectancy.

Conclusion

Most of the case of cutis laxa are genetic origin and few are acquired, so treatment are supportive and multidisciplinary approaches. Recent studies have greatly contributed to our understanding, classification, and treatment of CL and related syndrome. As this is rear disease so all case should have to recorded and monitor nationally and internationally and more study and lifelong follow-up needed.

References

1. Neerja Gupta, ShubrahR. Phadke. Cutis Laxa Type II and Wrinkly Skin Syndrome: Distinct Phenotypes. 2006 (doi.org/10.1111/j.1525-1470.2006.00222).
2. Morava E, Guillard M, LefeberDJ, Wevves RA. Autosomal recessive cutis laxa syndrome revisited. *Eur j Hum Genet* 2009; **17**: 1099-110.
3. Beighton P. The dominant and recessive forms of cutis laxa. *J Med Genet* 1972; **9**: 216-12
4. DamkierA,Brandroup F, StarklintH. Cutislaxa.: autosomal dominant inheritance in five generations. *Clin Genet* 1991; **39**: 321-29.
5. Zhang MC, He L, Giro M, Yong SL, Tiller GE, Davidson JM. Cutis laxa arising from framshift mutations in exon 30 of the elastin gene (HLN). *J BiolChem* 1999; **274**: 981-86.
6. Dingman RO, Grabb WC, Oneal RM. Cutis laxa congenita-generalized elastosis. *Plast Reconstr Surg* 1969; **44**: 431-45.
7. Szabo Z, Crepeau MW, Mitchell AL, Stephan MJ, Puntel RA, YinLoke k et al. Aortic aneurysmal disease and cutis laxa caused by defects in the elastin gene. *J Med Genet* 2006; **43**: 255-58.
8. Andiran N, Sarikayalar F, Saraclar M, Caglar M. Autosomal recessive form of congenital cutis laxa: more than the clinical appearance. *Pediatr Dermatol* 2002; **19**: 412-14
9. De Schepper S, Loeys B, de Paepe A, Lambert J, Naeyaert JM. Cutis laxa of the autosomal recessive type in a consanguineous family. *Eur J Dermatol* 2003; **13**: 529-33.
10. Loeys B, Van Malderge mL, Mortier G, Coucke P, Gerniers S, Naeyaert JM, et al. Homogenicity for a missense mutation in fibrillin -5 (FBLNS) results in a severe form of cutis laxa. *Hum Mol Genet* 2002; **11**: 2113-18.
11. van maldergemL, VamosE, LiebaersI, PetitPV and evelde G, Simonis-Blumenfrucht A et al. Severe congenital cutis laxa with pulmonary emphysema: a family with three affected sibs. *Am J Med Genet* 1983; **31**: 155-61.
12. Tsuji A, YanalJ, MiuraT, ShiraiY, Osano M, Hosoda Y, et al. Vascular abnormalities in congenital cutis laxa-reports of two cases. *Acta pediatr dermatol* 2001; **18**: 365-66.
13. Ledoux-Corbusier m. Cutis laxa, congenital form with pulmonary emphysema : an ultrastructural study. *J Cutan Pathol* 1983; **10**: 340-49.
14. Baldwin L, Kumrah L, Thoppuram P , Bhattacharji S,. Congenital cutis laxa (dermatochalasia)with cardiac valvular disease. *Pediatr Dermatol* 2001; **18**: 365-66.
15. Huchtagowder V, Morava E, Kornak U, Lefeber DJ, Fischer B, Dimopoulou A, et al. Loss -of-function mutations in ATP6VOA2 impair vesicular trafficking, tropoelastin secretion and cell survival. *Hum Mol Genet* 2009; **18**: 2149-65.
16. Van Meldergem L, Yuksel-Apek M, KayserillH, Seemnova E, Giurgea S, Basel-Vanagait L, et.al Cobbleston-like brain dysgenesis and altered glycosylation in congenital cutis laxa, Deber type. *Neurology* 2008; **71**: 1602-08.
17. Al-Gazali Li, Sztriha L, Skaff F, Hass D, Gerodermia osteodys plastica and wrinkly skin syndrome: are they the same ? *Am J Med Genet* 2001; **101**: 213-20.

18. Guernsey DL, Jiang H, Evans SC, Ferguson M, Matsuoka M, Nightingale M et al. Mutation in pyroline-5-carboxylate reductase 1 gene in families with cutis laxa type 2. *Am J Hum Genet* 2009; **85**: 120-29.
19. Hamamy H, Masri A, Ajlouni K, Wrinkly Skin syndrome. *Clin Exp Dermatol* 2005; **30**: 509-02.
20. De Barsy AM, Moens E, Dierckx L. Dwarfism, oligophrenia and degeneration of the elastic tissue in skin and cornea: a new syndrome? *Helv paediatr Acta* 1968; **23**: 305-13.
21. Reed WB, Horowitz RE, Beighton P. Acquired cutis laxa; primary generalized elastolysis. *Arch Dermatol* 1971; **103**: 661-69.
22. Tsuji T, Imajo Y, Sawabe m, Kuniyuki S, Ishii M, Hamada T, et al. Acquired cutis laxa concomitant with nephrotic syndrome. *Arch Dermatol* 1987; **123**: 1211-16.
23. Nahas FX, Sterman S, Gemperli R, Ferreira MC. The role of plastic surgery in congenital cutis laxa: a 10 years' follow-up. *Plast Reconstr Surg* 1999; **104**: 1174-49.
24. Banks ND, Redett RJ, Mofid MZ, Manson PN, Cutis laxa : clinical experience and outcomes. *Plast Reconstr Surg* 2003; **111**: 2434-43.