

CASE REPORT

Allergic Proctocolitis (AP) with Protein Losing Enteropathy (PLE): A Case Report

Sharmin Akter¹, Aysha Sabiha², Nahide-E-Subha³, Maimuna Sayeed⁴, Bishnu Pada Dey⁵, ASM Bazlul Karim⁶

Introduction

Allergic Proctocolitis (AP) is an immune mediated gastrointestinal disorder characterized by inflammation of the distal colon and this inflammation occurred in response to one or more food proteins. The disorder usually presents within a few months after birth but occasionally may present as early as first week of life.¹ The prevalence rate is 18 to 64 percent among infants with rectal bleeding.^{2,3} 50 percent of AP babies are breastfed. But it is less common in infants fed with cow's milk-based or soy protein-based formulas.⁴⁻⁶

Infant with AP babies are generally healthy, presents with visible specks or streaks of blood mixed with mucus in the stool.⁷ Some infant experience increased gas, episodic emesis, pain with defecation, and abdominal pain.⁸ Cow's milk (CM), soy, egg and corn in the maternal diet are most common causative foods in breast-fed infants with AP, although other foods such as meat, fish, apple, carrot, wheat, and sesame have been mentioned.⁹ There is transient colitis in AP which may cause hypoalbuminaemia due to protein losing enteropathy.^{10,11}

Case report

Here, we are reporting a 7 month old female baby, second issue of non-consanguineous parents got

admitted in the department of pediatric gastroenterology and nutrition, BSMMU with the history of gradual swelling of whole body for 1 month, loose stool for 9 days. She had h/o occasional mucus-streaked stool since 5 month of age. Then she developed swelling of abdomen which gradually spread on whole body. There was also history of loose stool for last 9 days, passed 10 to 15 stools per day, not mixed with blood or mucous. Regarding feeding history baby was on exclusive breast feeding since birth & there was no history of drinking of cow's milk. There was no history of fever, vomiting, per rectal bleeding, atopic dermatitis, family history of atopy, scanty micturation, jaundice, feeding mismanagement. There was history of one unit of blood transfusion at six month of age. On examination the child was ill looking, no skin or hair change, vitals were within normal limit. The child was mildly pale, edematous, moderately wasted, bed side urine for albumin was nil. Per abdominal examination showed ascites. Other systemic examination revealed nothing abnormality.

The laboratory data showed Hb% 10 gm/dl, ESR 15 mm in 1st hr, Total count 19,000/cmm, neutrophil 32%, lymphocyte 63%, Eosinophil 7%. Electrolytes within normal limit, serum albumin 17 gm/l, liver

1. Consultant, Department of Paediatric Gastroenterology and Nutrition, Bangabandhu Sheikh Mujib Medical University, Dhaka, Bangladesh.
2. Resident Phase B, Department of Paediatric Gastroenterology and Nutrition, Bangabandhu Sheikh Mujib Medical University, Dhaka, Bangladesh.
3. Resident Phase B, Department of Paediatric Gastroenterology and Nutrition, Bangabandhu Sheikh Mujib Medical University, Dhaka, Bangladesh.
4. Resident Phase B, Department of Paediatric Gastroenterology and Nutrition, Bangabandhu Sheikh Mujib Medical University, Dhaka, Bangladesh.
5. Assistant Professor, Department of Pathology, Bangabandhu Sheikh Mujib Medical University, Dhaka, Bangladesh.
6. Professor, Department of Paediatric Gastroenterology and Nutrition, Bangabandhu Sheikh Mujib Medical University, Dhaka, Bangladesh.

Correspondence to: Dr. Sharmin akter, consultant, Department of Paediatric Gastroenterology & Nutrition, Bangabandhu Sheikh Mujib Medical University (BSMMU), Dhaka, Bangladesh. Cell: 01714040145, E-mail: dr.sakter@yahoo.com

Received: 15 March 2020; **Accepted:** 25 May 2021

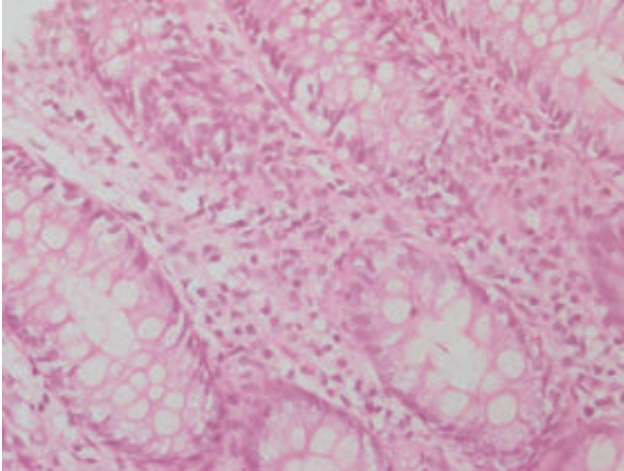


Fig.-1a: *H&Ex200: Allergic colitis with mucosal edema and many eosinophils in the lamina propria.*

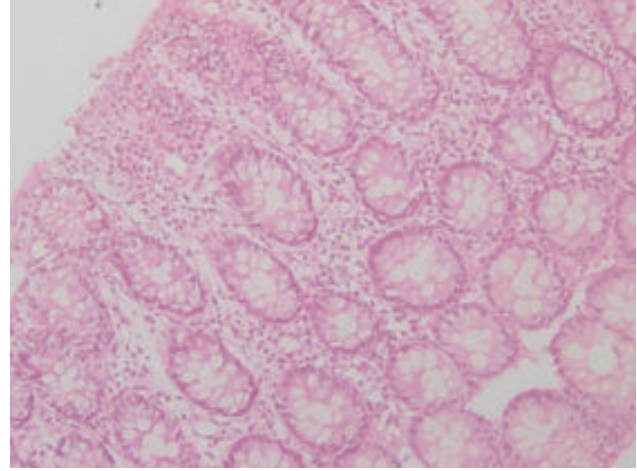


Fig.-1b: *H&Ex100: Allergic colitis with mucosal edema and many eosinophils in the lamina propria.*

function test normal, urine microscopic examination showed no proteinuria and no growth in urine culture. Stool microscopic examination showed RBC 1- 5, pus cell >50, macrophage 1-5 and OBT positive. Upper endoscopy and colonoscopy studies revealed grossly normal appearing mucosa lining the upper and lower gastrointestinal tract. Subsequent histologic examination revealed chronic nonspecific colitis.

Initially we sequentially eliminated cow's milk and dairy product, then egg from maternal diet. But patient's condition did not improved. Then we eliminated soy from maternal diet and started to feed the baby khichuri with mustard oil and the frequency of stool passing gradually became normal. Finally we diagnosed the case as allergic proctocolitis with protein losing enteropathy.

Sections of the colonic mucosa shows mucosal edema, increased number of eosinophils (>60 per 10 HPF) in the lamina propria, in the crypt abscesses and around muscularis mucosa. Focal area shows mild active colitis (Fig.-1).

Discussion

AP is a non-IgE-mediated food protein hypersensitivity reaction. In 1982 Lake et al¹¹ described AP in six exclusively breastfed infants with rectal bleeding during the first month of life.

Exact mechanisms of AP are not known, but it is assumed that the disease may be the result from maternal ingestion of a protein allergen (mostly CM) that is passed through breast milk in a form that can be immunologically recognized.⁸

Infant usually present within first six month of life with intermittent blood streaked stool and normal to moderately loose stool.¹² Our patient had history of occasional mucus-streaked stool since 5 month of age and at 7 month of age presented with loose stool but no visible blood in stool. AP is more common in breastfed babies than in infant fed with cow's milk-based or soy protein-based formulas.⁴ Our patient was on breast fed since birth.

On examination the AP infant appears generally well. Anaemia may be noted in some cases without necessity of blood transfusion. Mild edema also noted.¹³ The reported case was pale and edematous, she had history of one unit blood transfusion at six month of age. We excluded hepatic and renal causes of edema by doing liver function test and renal function test. We also excluded malnutrition by taking feeding history and considered the edema due to protein losing enteropathy.

Microscopic examination of the stool and a complete blood count (CBC) with differential may be helpful when diagnosis is unclear. The laboratory findings consistent with anemia, peripheral blood eosinophilia, hypoalbuminemia and hypoproteinemia.¹³ Our patient had anaemia, eosinophil count was 7%, hypoalbuminaemia and feature of colitis in stool but no growth in culture. Stool OBT was positive.

Colonoscopic evaluation with biopsy is indicated for some selected patients present with unusual or atypical symptoms, such as constipation, diarrhea with mucus-streaked stools but without grossly

visible bleeding, or severe rectal bleeding or anemia despite a trial of cow's milk elimination diet.⁶ Our patient had diarrhea without visible bleeding and generalized edema due to hypoalbuminaemia. By colonoscopy we also excluded early onset inflammatory bowel disease.

Colonoscopic findings include a mild colitis with patchy erythema and edematous mucosa with loss of vascularity confined to the distal colon.^{2,4} Biopsies typically reveal high numbers of eosinophils (including eosinophilic abscesses) in the lamina propria and muscularis mucosa.^{12,14}

An USA-based prospective cohort study of infants with rectal bleeding, demonstrated that 14 of 22 (64 percent) are AP, based on biopsy findings from flexible sigmoidoscopy.⁶ Five (23 percent) had normal biopsies, and three (14 percent) had nonspecific colitis. Upper endoscopy & colonoscopy studies of our patient revealed grossly normal appearing mucosa lining the upper and lower gastrointestinal tract. Subsequent histologic examination revealed chronic nonspecific colitis

Allergic proctocolitis (AP) is almost always a clinical diagnosis. Diagnosis usually made by typical history of rectal bleeding, exclusion of infections and other causes of rectal bleeding, and response to an elimination diet. After elimination of offending food clinical resolution of symptom within 72-96 hours.¹¹

Treatment is dietary restriction in mother when baby is on breast feeding or in infant of formula feeding. CM and all dairy product should be eliminated first. In the breastfed infants, when symptom not controlled by the elimination of cow's milk and soy, additional eliminations may be done including wheat and egg. Milk hydrolysate may be considered when the child is not breastfed or when the mother decides to stop breastfeeding, but the persistence of bleeding means the need for an amino-acid formula. Food introduction should be done at home gradually over 2 weeks.¹⁵

Diagnosis of the reported case was made through clinical history, exclusion of infection and other causes of edema and response to an elimination diet. After counseling we sequentially eliminated cow's milk and dairy product, egg, soy from the maternal diet. The frequency of stool passing gradually became normal and edema subsided. There may be recurrence of bleeding when oral food challenge

takes place within the first 6 months.¹⁵ We did not do any food challenge test of our patient.

The prognosis is excellent. Around 50 percent of patients with AP achieve food tolerance by 1 year of age¹⁶ and most of the patient by 3 years.³ After two months follow up she had no subsequent episodes of edema, diarrhea and occult blood test was negative. We advised our patient to continue dietary restriction up to 1 year age, then to reintroduce food gradually over 2 week.

Conclusion

Allergic proctocolitis (AP) is a common condition in infancy, but its association with PLE is rare. This case highlights the importance that when a infant present with generalized edema and diarrhoea, AP with PLE may be one of the differential diagnosis. AP infants are generally healthy appearing and happy. Because of this, many infants have symptoms for weeks or months before they are formally diagnosed. This delay in diagnosis may be the cause of development of edema and anaemia. So a high degree of suspicion and awareness of this rare condition is important for early diagnosis, management and prevention of unusual complication.

References

1. Boné J, Claver A, Guallar I, Plaza AM. Allergic proctocolitis, food-induced enterocolitis: Immune mechanisms, diagnosis and treatment. *Allergol Immunopathol (Madr)* 2009;**37**:36-42.
2. Arvola T, Ruuska T, Keränen J, Hyöty H, Salminen S, Isolauri E. Rectal bleeding in infancy: Clinical, allergological, and microbiological examination. *Pediatrics* 2006;**117**:e760-68.
3. Xanthakos SA, Schwimmer JB, Melin-Aldana H, Rothenberg ME, Witte DP, Cohen MB. Prevalence and outcome of allergic colitis in healthy infants with rectal bleeding: A prospective cohort study. *J Pediatr Gastroenterol Nutr* 2005;**41**:16-22.
4. Lake AM. Food-induced eosinophilic proctocolitis. *J Pediatr Gastroenterol Nutr* 2000;**30** Suppl:S58.
5. Lake AM, Whittington PF, Hamilton SR. Dietary protein-induced colitis in breast-fed infants. *J Pediatr* 1982;**101**:906-10
6. Pittschieler K. Cow's milk protein-induced colitis in the breast-fed infant. *J Pediatr Gastroenterol Nutr* 1990;**10**:548
7. Caubet JC, Szajewska H, Shamir R, Nowak-Węgrzyn A. Non-IgE-mediated gastrointestinal food allergies in children. *Pediatr Allergy Immunol* 2017;**28**:6-17.

8. Nowak-Węgrzyn A. Food protein-induced enterocolitis syndrome and allergic proctocolitis. *Allergy Asthma Proc* 2015;**36**:172-84.
9. Erdem SB, Nacaroglu HT, Karaman S, Erdur CB, Karkýner CU, Can D. Tolerance development in food protein-induced allergic proctocolitis: single centre experience. *Allergol Immunopathol (Madr)* 2017; **45**:212-219
10. Feuille E, Nowak-Węgrzyn A. Food Protein-Induced Enterocolitis Syndrome, Allergic Proctocolitis, and Enteropathy. *Curr Allergy Asthma Rep* 2015;**15**:50.
11. Lake AM, Whittington PF, Hamilton SR. Dietary protein-induced colitis in breast-fed infants. *J Pediatr* 1982;**101**:906-10.
12. Winter HS, Antonioli DA, Fukagawa N. Allergy-related proctocolitis in infants: diagnostic usefulness of rectal biopsy. *Mod Pathol* 1990;**3**:5-10.
13. Connors L, O'Keefe A, Rosenfield L, Kim H. Non-IgE-mediated food hypersensitivity. *Allergy Asthma Clin Immunol* 2018;14(Suppl 2):**56**:84-91.
14. Goldman H, Proujansky R. Allergic proctitis and gastroenteritis in children. Clinical and mucosal biopsy features in 53 cases. *Am J Surg Pathol* 1986;**10**:75-86.
15. Dupont C. Food Protein-Induced Enterocolitis Syndrome and Proctocolitis. *Ann Nutr Metab* 2018;**73**(suppl 4):8-16.
16. Kaya A, Toyran M, Civelek E, Misirlioglu E, Kirsaciloglu C, Kocabas CN. Characteristics and prognosis of allergic proctocolitis in infants. *J Pediatr Gastroenterol Nutr* 2015;**61**:69-73.