

Effectiveness of Aloe Vera Gel in Management of Superficial Burn in Children

Md. Saif Ullah¹, Md. Mazharul Alam², Kazi Md. Noor-ul Ferdous³

Abstract

Background: Aloe vera has been used traditionally for healing burn and inflammation. Though, the evidence for the effectiveness of aloe vera for healing burn is not sufficient.

Objective: The aim of this study was to assess the effectiveness of aloe vera gel in management of superficial burn in children.

Methods: This retrospective study was taken place in the Department of Burn and Reconstructive Surgery, Bangladesh Shishu Hospital & Institute, Dhaka and other two private clinics at Dhaka, from September, 2019 to March, 2022. Total 47 patients with superficial partial thickness burn was included in the study.

Results: In this study, majority (48.94%) patients were belonged to the age group of ≤ 24 months. The mean age was found 38.9 ± 26.31 months. The current study observed that almost two third (61.70%) patients were male. In our study, majority (63.83%) patients stayed hospital for 1-5 days. In the present study, mean (\pm SD) pain relief time was 3.56 ± 1.24 days and mean (\pm SD) wound healing time was found 8.19 ± 1.6 days. The current study observed that only 3 (6.38%) patients had found wound infection. In current study showed that mean treatment cost was found 76.46 ± 31.88 Taka.

Conclusion: Aloe vera gel facilitated early pain alleviation, wound healing, and cost-effective superficial burn treatment in children. Therefore, it can be utilized to treat superficial burns in children to get better results.

Keywords: Aloe vera gel, children, superficial burn.

DS (Child) HJ 2022;38(1):39-43

DOI: <https://doi.org/10.3329/dshj.v38i1.67002>

Introduction

Aloe vera is being used for centuries for “cosmetic, medicinal, and nutraceutical purposes” due to its antioxidant properties.¹ It has 75 potentially active ingredients, including amino acids, carbohydrates, lignin, saponins, vitamins, enzymes, minerals, and salicylic and other acids.² The extract of aloe vera gel allowed for quicker healing of burns and restored the vascularity of burn tissues. These effects could be the result of a number of mechanisms, such as

an increase in the production of collagen and the rate of epithelialization brought on by the ability of acemannan (mannose-6 phosphate) to stimulate fibroblasts, as well as an anti-inflammatory, antimicrobial, and moisturizing effect (Maenthaisong et al. 2007).³ One of the main benefits of using aloe vera gel in many nations is the healing of burn wounds.⁴⁻⁵ Burns have been identified as one of the most damaging types of child damage in terms of functional, social, and psychological impact.⁶⁻⁹ Burns

1. Associate Professor, Division of Paediatric Surgery, Bangladesh Shishu Hospital & Institute, Dhaka.

2. Assistant Professor, Department of Paediatric Surgery, Mainamoti Medical College & Hospital, Cumilla, Bangladesh.

3. Associate Professor, Division of Paediatric Surgery, Bangladesh Shishu Hospital & Institute, Dhaka.

Correspondence to: Dr. Md. Mazharul Alam, Assistant Professor, Department of Paediatric Surgery, Mainamoti Medical College & Hospital, Cumilla, Bangladesh. 01717062971, E-mail: mazharcemec3@gmail.com

Received: 25 April 2022; **Accepted:** 30 May 2022

are a major cause of public health concern and are an international issue.¹⁰ In 2000, there were 238,000 fire-related fatalities worldwide, 95% of which were in low- and middle-income nations.¹¹ Aloe vera has been shown by Davis RH¹² to relieve pain, inflammation, arthritis, and wounds. His conductor-orchestra theory of aloe vera considers how all of its biologically active components work together to deliver the maximum amount of desired effects with little to no toxicity. Athavale et al¹³ evaluated the percentage decrease of wound healing with aloe vera gel dressing and contrasted its efficacy with that of traditional dressing (normal saline and povidone iodine). According to the study's findings, aloe vera gel is very successful in treating chronic ulcers and accelerates wound healing, which shortens hospital stays. Aloe vera gel was not linked to any adverse reactions or infections. According to Varaei et al¹⁴, local burn wound pain was measured using a visual analogue scale 10 minutes before to changing the dressing and 24, 48, and 72 hours afterwards using 2% nitrofurazone ointment and aloe vera gel. Thus, dressing pain intensity considerably decreased over the course of 72 hours in both locations, but aloe vera gel was able to lessen pain more quickly than nitrofurazone. The cause might be the carboxypeptidase found in aloe vera gel, which interacts with bradykinin, a potent cause of acute inflammatory pain.¹⁵ Aloe vera use is also reasonably priced. Aloe vera is thought to function by boosting the turnover, production, and cross-linking of collagen in the healing wound.¹⁶⁻¹⁸ By inhibiting leukocyte adherence and the activities of Transforming Necrosis Factor and Interleukin-6, it may also suppress the inflammatory process.¹⁹ However, the effectiveness of aloe vera gel in management of superficial burn in children has not been previously studied in depth. Therefore, the current study was conducted to evaluate the effectiveness of aloe vera gel in management of superficial burn in children.

Materials and Methods

This retrospective study was taken place in the Department of Burn and Reconstructive Surgery, Bangladesh Institute of Child Health (BICH), Dhaka Shishu (Children) Hospital and other two privet

clinics at Dhaka, from September, 2019 to March, 2022. Total 47 patients' data collected from hospital records who admitted with superficial partial thickness burn involving <20% of TBSA (total body surface area) admitted within 24 hours during the study period and treated with aloe vera gel. Hospital records confirmed that, burn involving special areas (face, palm, sole, and perineum), burn associated other injuries, electric and chemical burn, patients with known allergy to aloe vera gel were excluded. An informed written consent of the guardians were taken before starting the treatment. Statistical analysis was carried out using the Statistical Package for Social Sciences version 23.0 for Windows (SPSS Inc., Chicago, Illinois, USA). The quantitative observations were indicated by frequencies and percentages.

Results

In this study, majority (48.94%) patients were belonged to the age group of ≤ 24 months. The mean age was found 38.9 ± 26.31 months. The current study observed that almost two third (61.70%) patient were male (Table I). Majority (63.83%) patients stayed hospital for 1-5 days (Table II). Mean (\pm SD) pain relief time was 3.56 ± 1.24 days and mean (\pm SD) wound healing time was found 8.19 ± 1.6 days (Table III). Fig.-1 demonstrates the distribution of the study population according to wound infection using Aloe vera gel. The current study observed that only 3(6.38%) patients had wound infection. Mean treatment cost was found 76.46 ± 31.88 Taka (Table IV).

Table I
Demographical characteristics of the study people (N=47)

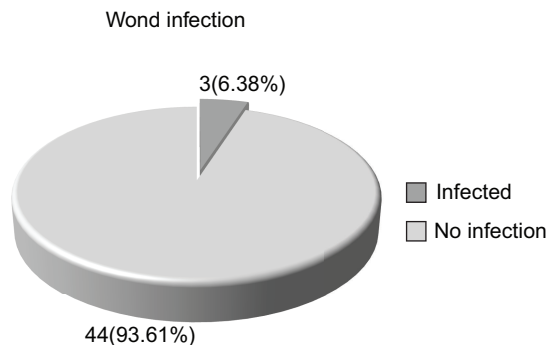
Characteristics	n	%	
Age (months)	≤ 24	23	48.94
	25-60	15	31.91
	>60	9	19.15
	Mean \pm SD	38.9 \pm 26.31	
Gender	Male	29	61.70
	Female	18	38.30

Table II*Distribution of the study population according to hospital stay (N=47)*

Hospital stay (day)	n	%
1-5	30	63.83
6-10	17	36.27

Table III*Distribution of the study population according to pain relief time and wound healing time using Aloe vera gel (N=47)*

Characteristics	Mean \pm SD	Range (min-max)
Pain relief time (day)	3.56 \pm 1.24	1-6
Wound healing time (day)	8.19 \pm 1.6	4-11

**Fig.-1** *Distribution of the study population according to wound infection using Aloe vera gel (n=47)***Table IV***Distribution of the study population according to treatment cost (N=47)*

	Mean \pm SD	Range (min-max)
Treatment cost (Taka)	76.46 \pm 31.88	30-180

Discussion

This study observed that majority (48.9%) patients were belonged to age ≤ 24 months. The mean age was found 38.9 \pm 26.31 months. Jozsa et al²⁰ reported most of the studied children were <5 years of age. Up to 50% of children under the age of 11 get sunburns, which are the most frequent and avoidable kind of burns.²¹ Children of five years of age or younger most frequently get scald burns, which are

frequently caused by spilling hot liquids while cooking.²² The current study observed that almost two third (61.70%) patients were male. In the study of Shahzad et al²³, 68.0% patients were male in aloe group. In our study, majority (63.83%) patients stayed hospital for 1-5 days. In this present study, mean (\pm SD) pain relief time was 3.56 \pm 1.24 days and mean (\pm SD) wound healing time was found 8.19 \pm 1.6 days. In a study conducted in Bangladesh by Alam et al²⁴, mean pain relief time was found 2.60 \pm 1.27 days and the mean wound healing time was found 5.15 \pm 1.56 days. Thamlikitkul et al²⁵ used Aloe fresh mucilage in 38 patients with thermal burn and found that the healing process was accelerated significantly. In 1995, Visuthikosol et al²⁶ published the results of a research on 27 patients who had partial thickness burn wounds that were either dressed with gauze soaked in Aloe vera gel or left untreated. They noticed that patients who received aloe treatment had considerably faster wound healing times (11.19 days). The aloe-treated patients' wound healing times were dramatically shortened (18.9 days) in the study of Akhtar and Hatwar²⁷. Shahzad et al²³ in their study found that the time taken for partial thickness burns to heal was significantly shorter with aloe vera compared to control group (11 \pm 4.18 days vs. 24.24 \pm 11.16 days). Walash et al²⁸ compared the effectiveness of aloe vera gel dressing to traditional dressing on the recovery process and pain levels in burn patients. Compared to the control group, the research group experienced a quicker healing process, less discomfort, and a shorter hospital stay after using an Aloe Vera gel dressing. The current study observed that only 3(6.38%) patients had wound infection. This finding is similar to the study of Alam et al²⁴, where the rate of wound infection was 5%. According to Shahzad et al²³, the sole mechanism supporting the ongoing usage of silver sulphadiazine in burn injuries is its antibacterial action. The topical administration of SSD may result in leukopenia, renal damage, or both. In reality, while treating major wounds, severe negative effects have been noted.^{25,29,30} In the study of Walash et al²⁸, while 48% of the control group's patients exhibited signs of wound infection during the last two evaluations, all trial participants were free of these symptoms throughout the fifth and sixth assessments. In current study showed that mean treatment cost was found 76.46 \pm 31.88 Taka which is very cost effective compared to chemical products.

Conclusion

Aloe vera gel facilitated early pain alleviation, wound healing, and cost-effective superficial burn treatment in children. Therefore, it can be utilized to treat superficial burns in children to get better results. This research recommends using aloe vera gel to treat children's superficial burns, and the outcomes were encouraging. Further study is required with larger sample size in the fascinating topic of burn wound treatment for better understanding.

References

- Vaidya ADB, Devasagayam TPA. Current status of herbal drugs in India: An overview. *Journal of Clinical Biochemistry and Nutrition* 2007;**41**:1-11.
- Surjushe A, Vasani R, Saple DG. Aloe vera: A short review. *Indian journal of dermatology* 2008;**53**:163.
- Maenthaisong R, Chaiyakunapruk N, Niruntraporn S, Kongkaew C. The efficacy of aloe vera used for burn wound healing: A systematic review. *Burns* 2007; **33**:713-18.
- Reynolds T, Dweck AC. Aloe vera leaf gel: A review update. *J Ethnopharmacol* 1999;**68**:3-37.
- Marshall JM. Aloe vera gel: What is the evidence? *Pharm J* 1990;**24**:360-62.
- Crawley-Coha T. Childhood injury: A status report, part 2. *J Pediatr Nurs* 2002;**17**:133-36.
- Taal LA, Faberb AW. Posttraumatic stress and maladjustment among adult burn survivors 1-2 years postburn. *Burns* 1998;**24**:285-92.
- Macarthur C. Evaluation of Safe Kids Week 2001: prevention of scald and burn injuries in young children. *Injury Prevention* 2003;**9**:112-16.
- Drago DA. Kitchen scalds and thermal burns in children five years and younger. *Pediatrics* 2005; **115**:10-16.
- Zaidi MM, Abusetta A, Brogowski K, Agrawal PL, Franka MR. Analysis of burned children treated in the Burns and Plastic Surgery Center, Tripoly Libya, in the Year 1992. *Ann Medit Burns Club* 1993;VI.
- Peden MM, McGee K, Krug E. Injury: A leading cause of the global burden of disease, 2000. World Health Organization; 2002.
- Davis RH. Aloe vera: A scientific approach, Published by Vantage Press, Inc.1997. Available from: <https://scirp.org/reference/referencespapers.aspx?referenceid=996367>
- Athavale VS, Khandalkar SN, Mahawar M, Shtty I, Lad A. A comparative study between aloe vera gel dressing and conventional dressing in chronic wounds. *Int Surg J* 2017;**4**: 3427-32.
- Varei S, Aedakili FM, Irani OS, Ranban H. The effect of aloe vera gel and nitrofurazone on dressing related pain of superficial burn wounds. *World J Plast Surg* 2017;**6**:254-56.
- Yagi A, Kabbash A, Mizuno H, Moustafa SM, Khalifa TI, Tsuji H. Radical scavenging glycoprotein cyclooxygenase-2 and thromboxane A2 synthase from aloe vera gel. *Planta Med* 2003;**69**:267-71.
- Chithra P, Sajithlal GB, Chandrakasan G. Influence of Aloe vera on collagen turnover in healing of dermal wounds in rats. *Indian J Exp Biol* 1998;**36**:896-901.
- Chithra P, Sajithlal GB, Chandrakasan G. Influence of Aloe vera on collagen characteristics in healing dermal wounds in rats. *Mol Cell Biochem* 1998; **181**:71-76.
- Chithra P, Sajithlal GB, Chandrakasan G. Influence of Aloe vera on the healing of dermal wounds in diabetic rats. *J Ethnopharmacol* 1998; **59**:195-201.
- Duansak D, Somboonwong J, Patumraj S. Effects of Aloe vera on leukocyte adhesion and TNF-alpha and IL-6 levels in burn wounded rats. *Clin Hemorheol Microcirc* 2003;**29**:239-46.
- Jozsa G, Vajda P, Garami A, Csenkey A, Juhasz Z. Treatment of partial thickness hand burn injuries in children with combination of silver foam dressing and zinc-hyaluronic gel. *Medicine* 2018;**97**:e9991.
- Yin S. Chemical and common burns in children. *Clinical pediatrics* 2017;**56**(5_suppl):8S-12S.
- Herndon DN. *Total Burn Care*. 5th ed. Elsevier. 2017 Oct 10:1-812.
- Shahzad MN, Ahmed N. Effectiveness of Aloe Vera gel compared with 1% silver sulphadiazine cream as burn wound dressing in second degree burns. *J Pak Med Assoc* 2013;**63**:225-30.
- Alam MM, Hossan MA, Islam F, AM N, Nahiduzzan DM, Chakroborthy D. Effect of Aloe Vera Gel and 1% Silver Sulphadiazine cream in the treatment of superficial burn in children: A comparative study. *Journal of MAR Pediatrics* 2022;**2**. Available from: https://www.medicalandresearch.com/assets/articles/documents/DOCUMENT_20220831124839.pdf
- Thamlikitkul V, Bunyapraphatsara N, Riewpaiboon W, Theerapong S, Chantrakul C, Thanaveerasuwan T, et al. Clinical trial of aloe vera Linn. for treatment

- of minor burns. *Siriraj Medical Journal* 2017;**43**: 313-16.
26. Visuthikosol V, Chowchuen B, Sukwanarat Y, Sriurairatana S, Boonpucknavig V. Effect of aloe vera gel to healing of burn wound a clinical and histologic study. *J Med Assoc Thai* 1995;**78**:403-09.
27. Akhtar MA, Hatwar SK. Efficacy of aloe vera extract cream in management of burn wound. *Journal of Clinical Epidemiology* 1996;49:S24.
28. Walash AM, Shehata OEKA, El-Sol AEl-SH. Efficacy of dressing by aloe vera gel on healing and pain among burned patients. *Am J of Nursing Res* 2019;**7**:1028-40.
29. Atiyeh BS, Costagliola M, Hayek SN, Dibo SA. Effect of silver on burn wound infection control and healing: Review of the literature. *Burns* 2007;**33**:139-48.
30. Klasen HJ. A historical review of the use of silver in the treatment of burns. II. Renewed interest for silver. *Burns* 2000;**26**:131-38.