



Original Article

Evaluation of Fecal Occult Blood Test for Screening of Colorectal Carcinoma

Haldar GC¹, Hoque AKMA², Das A³, Majumder RC⁴, Karmakar P⁵

Abstract

Background: Colorectal carcinoma is one of the most common and leading causes of cancer-related death in the United States. Fecal occult blood test used as a screening test followed by sigmoidoscopy or colonoscopy to early detection of colorectal carcinoma. **Objective:** To assess the fecal occult blood by fecal occult blood test of the patients who fulfill the criteria as a screening for colorectal carcinoma and evaluation of those patients who are positive for fecal occult blood test for early detection of colorectal carcinoma by fiber optic full colonoscopy. **Materials and Methods:** This hospital based observational study was carried out in Dhaka Medical College Hospital, Dhaka, Bangladesh for a period of 6 month from July 2009 to December 2009. A total of 50 cases were selected by convenient sampling fulfilling the inclusion and exclusion criteria. Those who had positive fecal occult blood test were further advised for fiber optic full colonoscopy and biopsies were taken where necessary as a screening for colorectal carcinoma. Reported results and relevant data were recorded in the data sheet and then analyzed by standard statistical method. **Results:** Total number of cases was 50. Adequate samples were obtained in 46 (92%) cases, among the adequate samples 18 (36%) were malignant and 28 (56%) were benign or nonmalignant lesions. Among the benign lesions, nonspecific colitis (13;26%) was the most common followed by rectal polyp (1;2%), proctocolitis (1;2%) and Normal tissue (1;2%). Adenocarcinoma (18;36%) was the most common type of colorectal carcinoma. In male, colorectal carcinoma (15;30%) was the more common than female (3;6%). **Conclusion:** Guaiac based FOBT is a simple and less expensive test for identification of occult blood in stool. It is easily done with minimum cost and suitable test as a screening for early diagnosis of colorectal cancer. FOBT positive patient's fiber optic colonoscopy is a wonderful investigation for further diagnosing the colonic lesion.

Key words: Fecal Occult Blood Test (FOBT), Colonoscopy, Colorectal carcinoma.

Received: April 23, 2023; **Accepted:** May 12, 2023

DOI: <https://doi.org/10.3329/emcj.v8i2.69692>

Introduction

Colorectal cancer (CRC) is a leading cause of cancer death in the western world¹. The estimated lifetime risk of colorectal is 5-6%. The incidence rate increases sharply after the age of 50 years. The incidence rate has remained relatively unchanged during the past 30 years, while the mortality rate has decreased, particularly in female. Colorectal cancer is preventable in up to 90% cases¹.

Colorectal cancer is the third most common cancer in the world². With about one million new cases and more than 500,000 deaths per year. Because most cases of CRC are sporadic and develop from removable precancerous lesions (adenomas) and curable early stage cancer³. Screening for CRC has high potential for reducing morbidity and mortality. Randomized controlled trials have been demonstrated reduced mortality with guaiac-based fecal occult blood testing (FOBT) followed by

colonoscopy or sigmoidoscopy if the FOBT result is positive⁴. Colorectal cancer screening is a high public health priority in all industrialized countries. Fecal occult blood test is a noninvasive test. This test detects hidden blood in the stool. Such blood may come from anywhere along the digestive tract⁵. Hidden blood in stool is often the first and many cases the only, warning sign that a person has colorectal disease including colon cancer. Fecal occult blood test is recommended as a screening test for colorectal cancer⁵.

Annual fecal occult blood test screening is endorsed by major medical organizations as a viable colorectal cancer screening. Large randomized controlled trials have shown that screening test for colorectal cancer by FOBT can significantly lower incidence and mortality⁶. In that study patients with positive FOBT results will undergo a complete

¹Ganesh Chandra Haldar, Associate Professor, Dept. of Medicine, Eastern Medical College & Hospital, Cumilla, Bangladesh.

²AKM Aminul Hoque, Professor, Dept. of Medicine, Anwer Khan Modern Medical College & Hospital, Dhaka, Bangladesh.

³Apama Das, Associate Professor, Dept. of Medicine, Dhaka Medical College & Hospital, Dhaka, Bangladesh

⁴Ripon Chandra Majumder, Associate Professor, Dept. of Nephrology, Eastern Medical College & Hospital, Cumilla, Bangladesh.

⁵Pijush Karmakar, Associate Professor, Dept. of Biochemistry, Eastern Medical College, Cumilla, Bangladesh.

Address of Correspondence: Dr. Ganesh Chandra Haldar, Associate Professor, Department of Medicine, Eastern Medical College and Hospital, Cumilla, Bangladesh. Mobile: +01711160427. Email: drghc53117415@gmail.com

diagnostic evaluation (CDE) which consists of colonoscopy or double contrast barium enema plus flexible sigmoidoscopy.

A colorectal cancer screening test should identify persons with early-stage cancer that is an immediate medical threat and persons with advanced adenomas that could be a future threat as well as having high sensitivity; the screening test should have high specificity for detecting clinically significant neoplasia, cancer and advanced adenomas to minimize follow up colonoscopy examination⁷.

Stool tests are an important component of the options recommended for CRC screening. They are particularly relevant for patients who would not be willing to have screening colonoscopy or in a setting in which colonoscopy is not offered as a primary screening tool⁸.

Materials and Methods

The study was carried out in Dhaka Medical College Hospital, Dhaka, Bangladesh for a period of 6 month from July 2009 to December 2009. A total of 50 cases were selected by convenient sampling fulfilling the inclusion and exclusion criteria. Selected patients were advised for traditional guaiac-based fecal occult blood test. Before the test patients were advised to avoid iron supplements, red meat, cabbage, cauliflower, citrus fruits, and vitamin-C for three days. Those who had positive fecal occult blood test were further advised for fiber optic full colonoscopy as a screening for colorectal carcinoma. Before colonoscopy, colon was prepared mechanically; colonoscopy was carried out under sedation. Most of the patient’s bowel was prepared with oral mannitol and enema simplex. The maximum number of cases (46) was given pethidine as premedication. Colonoscopy was carried out following visualization endoscopically the colon, biopsies were taken where necessary. Patient’s detailed particulars, such as patients name, age, sex, occupation, address were entries in the protocol, symptomatic presentations, physical findings and detailed colonoscopic finding were also recorded. Reported results and relevant data were recorded in the data sheet and then analyzed by standard statistical method.

Results

Different information of 50 patients presented with change in bowel habit, anemia, abdominal pain, weight loss has been plotted in different tables and charts.

In this study, 50 patients with FOBT positive underwent fiber optic colonoscopy but in 4 cases could not be done successfully due to poor bowel preparation. Out of 50 patients, 38 patients (76%) were male and 12 (24%) were female (figure-1).

Studied patients were 50 to 70 years (table-I). Changes in bowel habit, abdominal pain and weight loss were in 50%, 30% and 20% cases respectively (table-II). Maximum number of patients (38%) presented with symptoms of 1-3 months duration. The next number of cases (24%) with less than 1 month duration. The longest duration was 12 months, and the shortest duration was 20 days (figure-2). Anemia was found in all patients and 5 patients presented with severe anemia and the maximum were moderately anemic (table-III). Rectal mass could be palpated in 4 cases and in 2 cases colonic mass could be palpated per abdomen (table-IV).

Normal colonoscopic findings were found that 12 patients and 11 patients were found to have congestion with edematous changes in the left colon more on the sigmoid colon and histopathological report revealed non-specific colitis (table-V). 22 patients were suspected colonoscopically to have malignant lesions in the colon or rectum. After histopathology, 7 cases were diagnosed as carcinoma rectum, 11 cases were diagnosed as carcinoma colon. Nonspecific inflammation was found in 2 cases. Normal colonic mucosa was found in 1 case and 1 patient having feature of proctocolitis (table-VI).

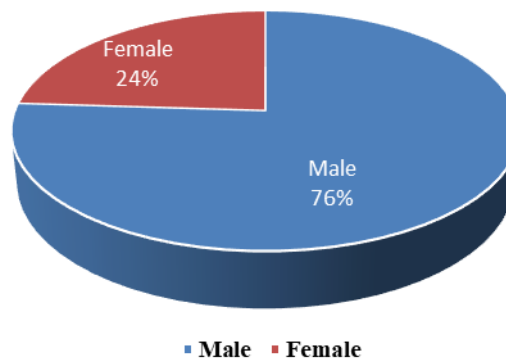


Figure-1: Distribution of Gender in the study cases (n=50)

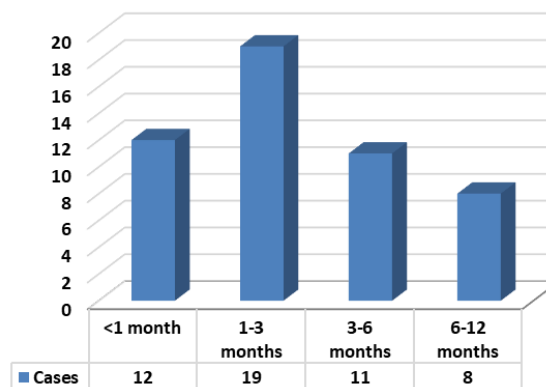


Figure-2: Duration of the symptoms of the cases (n=50)

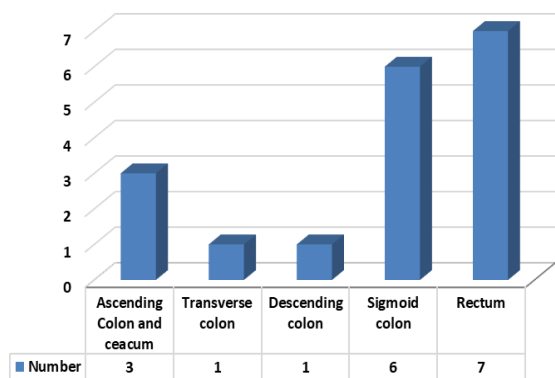


Figure-3: Incidence of carcinoma at different sites of the large gut (histologically confirmed)

Carcinoma of rectum was found in 7 cases where 6 were male and 1 was female. 11 cases were diagnosed as carcinoma of colon where 9 were male and 2 were female. On the other hand, the most common type of colorectal carcinoma in this study was adenocarcinoma. The age limit was between 50-70 years, but incidence of colorectal carcinoma is more common in the age of 50-60 years (table-VII, VIII). Figure-3 shows the incidence of large gut carcinoma at the different sites. 7 (14%) cases were involved in the rectum, 6 (12%) in the sigmoid colon, 1 (2%) in the descending colon, 1 (2%) in the transverse colon and 3 (6%) cases were found in the caecum and ascending colon.

Table-I: Distribution of age in the study (n=50)

Age (year)	Cases (n=50)	Percentage (%)
50-60	28	56
61-70	22	44

Table-II: Symptomatic presentation of the cases (n=50)

Symptoms	Cases (n=50)	Percentage (%)
Change in bowel habit	25	50
Abdominal pain	15	30
Weight loss	10	20

Table-VII: Colonoscopic and Histopathological findings of rectal masses (n-7)

Sl No	Age (year)	Gender	Colonoscopic findings	Histopathological report
1	60	Male	Ulcerative growth in the rectum	Moderately differentiated adenocarcinoma
2	55	Male	Ulceroproliferative growth in the rectosigmoid junction	Poorly differentiated adenocarcinoma
3	57	Male	Cauliflower like growth in the rectum	Well differentiated adenocarcinoma
4	69	Male	Ulcerative growth in the rectum	Well differentiated adenocarcinoma
5	58	Male	Cauliflower like growth in the rectum	Poorly differentiated adenocarcinoma
6	65	Male	Proliferative growth in the rectosigmoid junction	Moderately differentiated adenocarcinoma
7	52	Female	Ulcerative growth in the rectum	Mucin secreting adenocarcinoma

Table-III: Category of anemia in the study cases (n-50)

Category of Anemia	Cases (n=50)	Percentage (%)
Mild	20	40
Moderate	25	50
Severe	5	10

Table-IV: Abdominal and digital rectal examination findings of the study cases (n-50)

Findings	Cases (n=50)	Percentage (%)
Normal	44	88
Colonic mass	2	4
Rectal mass (DRE)	4	8

Table-V: Colonoscopic findings of the study cases (n-50)

Findings	Cases (n=50)	Percentage (%)
Normal	12	24
Rectal polyp	1	2
Non-specific colitis	11	22
Suspicious growth in the rectum or colon	22	44
Not possible due to poor bowel preparation	4	8

Table-VI: Histopathological findings of the suspected cases of carcinoma of colon and rectum after colonoscopy (n-22)

Histopathological report	Cases (n=22)	Percentage (%)
Carcinoma rectum	7	14
Carcinoma colon	11	22
Non-specific colitis	2	4
Proctocolitis	1	2
Normal tissue	1	2

Table-VIII: Colonoscopic and Histopathological findings of colon masses (n-11)

Sl. No	Age	Gender	Colonoscopic findings	Histopathological report
1	50	Male	Ulceroproliferative growth in the sigmoid colon	Mucinous Adenocarcinoma
2	52	Female	Ulceroproliferative growth in the descending colon (splenic flexure)	Moderately differentiated Adenocarcinoma
3	60	Female	Ulceroproliferative growth in the ascending colon	Adenocarcinoma
4	52	Male	Growth in the caecum & ascending colon	Mucinous Adenocarcinoma
5	50	Male	Growth in the caecum & ascending colon	Moderately differentiated Adenocarcinoma
6	70	Male	Cauliflower like growth in the transverse colon (hepatic flexure)	Mucinous Adenocarcinoma
7	62	Male	Growth in the sigmoid colon	Adenocarcinoma
8	65	Male	Growth in the sigmoid colon	Mucinous Adenocarcinoma
9	63	Male	Cauliflower like growth in the sigmoid colon	Moderately differentiated Adenocarcinoma
10	57	Male	Growth in the sigmoid colon	Adenocarcinoma
11	53	Male	Ulcerative growth in the sigmoid colon	Moderately differentiated Adenocarcinoma

Discussion

Colorectal cancer is the second leading cause of cancer death in the world. In women, it ranks third after lung and breast cancer and in men, it ranks third after lung and prostate cancer. Incidence and mortality from colorectal cancer are similar in both men and women⁹ but we found more in male (76%) than female (24%) due to lack of exposure of female patients. Death from colorectal cancer can be prevented by the detection of early-stage disease that has not metastasized. Symptoms of individuals beginning at about the age of 50 years, but different study showed incidence was more in 50-70 years^{10,11}. Similar to that study our study also showed the incidence was more in 50-70 years.

Most of the patients in this study had changes in bowel habit (50%), abdominal pain (30%), and weight loss (20%). Several studies showed changes in bowel habit (40%), abdominal pain (40%), and weight loss (40%) that were nearly similar with this study^{12,13}. Maximum number of our patients (38%) presented with symptoms of 1-3 months duration. But other studies showed maximum number of patients presented with symptoms of 6 months (42%) duration. This may be due to food habits and racial variations^{14,15}.

In this study anemia was found in all patients in which 10% of patients were presented with severe anemia. But most of the patients (50%) were moderately anemic. In a study by Konishi F, et al showed that anemia was found in 98% cases in which mostly were moderately anemic (60%)¹⁶. Rectal mass was palpated in 8% cases and in 4%

cases colonic mass was palpated per abdomen in our study. But multiple studies showed that colonic mass (10%) was more common than rectal mass (7%)^{17,18}.

Out of 50 patients, 44% were suspected colonoscopically to have malignant lesions in the colon or rectum. After histopathology, 7 (14%) cases were diagnosed as carcinoma rectum, 11 (22%) cases were diagnosed as colonic carcinoma, nonspecific inflammation found in 4% cases, normal colonic mucosa was found in 2% cases and 2% patient having feature of proctocolitis. Celestino A, et al in their study showed colorectal cancer in 35% cases¹⁹. Out of 7 carcinoma rectum cases, 6 (12%) were male and 1 (2%) was female. 11 cases were diagnosed as carcinoma of colon where 9 (18%) were male and 2 (4%) were female. The age limit was 50-70 years. It was noticeable that incidence of colorectal carcinoma is more in 50-60 years. Different studies showed colorectal carcinoma were more common in 50-60 years and male were predominant. Similar to the study, one study showed colorectal carcinoma in 31.25% cases²⁰.

The incidence rate of large gut carcinoma at the different sites were 7 (14%) in the rectum, 6 (12%) in the sigmoid colon, 1 (2%) in the descending colon, 1 (2%) in the transverse colon, 3 (6%) in the caecum and ascending colon and that were more in rectum & sigmoid colon (26%). Other studies showed the incidence rate of colorectal carcinoma was more in rectum and sigmoid colon (22-28%)²¹⁻²⁴. So, it is established that the most common sites of colorectal carcinoma are rectum and sigmoid colon.

On histopathological examination adenocarcinoma was the commonest type (100%) as was found in all studies (87.5%) dealing with colorectal malignancies^{25,26}. On histological grading found well differentiated (25%), moderately differentiated (25%), poorly differentiated (20%) and others (10%) from distal part to proximal part of the colon. Researchers found well differentiated adenocarcinoma was the most frequent (50-55%) case from distal to proximal colon^{27,28}. So adenocarcinoma was the most common colorectal cancer in this study as well as other studies.

Conclusion

Guaiac based FOBT is a simple and less expensive test for identification of occult blood in stool. It is easily done with minimum cost and suitable test as a screening for early diagnosis of colorectal cancer. FOBT positive patient's fiber optic colonoscopy is a wonderful investigation for diagnosing the colonic lesion. Therapeutic procedures have already made a significant contribution to the management of a varied group of disorders like colonic polyp, angiodysplasia. Besides this, early diagnosis can also help us to treat the disease in the very early stage and in colonic cancer if it is treated early-stage prognosis is excellent.

In our country colonoscopic facilities are very limited, which are very much inadequate for the growing need of our people. It is hoped that facilities will be expanded to extend the services of both diagnostic, therapeutic and if possible, for screening the high-risk groups to all parts of the country.

Conflict of interest

The authors declared that they have no conflict of interest.

References

1. Winawer SJ, Zauber AG, O'Brien MJ, Ho MN, Gottlieb L, Sternberg SS, et al. Randomized comparison of surveillance intervals after colonoscopic removal of newly diagnosed adenomatous polyps. The National Polyp Study Workgroup. *N Engl J Med.* 1993; 328 (13): 901-6. DOI: 10.1056/NEJM199304013281301.
2. Parkin DM, Bray F, Ferlay J, Pisani P. Global cancer statistics, 2002. *CA Cancer J Clin.* 2005 Mar-Apr; 55 (2): 74-108. DOI: 10.3322/canjclin.55.2.74.
3. Arnold CN, Goel A, Blum HE, Boland CR. Molecular pathogenesis of colorectal cancer: implications for molecular diagnosis. *Cancer.* 2005; 104 (10): 2035-47. DOI: 10.1002/cncr.21462.
4. Hewitson P, Glasziou P, Irwig L, Towler B, Watson E. Screening for colorectal cancer using the faecal occult blood test, Hemoccult. *Cochrane Database Syst Rev.* 2007; 2007 (1): CD001216. DOI: 10.1002/14651858.
5. Levi Z, Rozen P, Hazazi R, Vilkin A, Waked A, Maoz E, et al. A quantitative immunochemical fecal occult blood test for colorectal neoplasia. *Ann Intern Med.* 2007; 146 (4): 244-55. DOI: 10.7326/0003-4819-146-4-200702200-00003.
6. US preventive services task force. Screening for colorectal cancer recommendation & rationale. *Ann Internal Med.* 2002; 137 (2): 129-41. DOI: 10.7326/0003-4819-137-2-200207160-00014.
7. Hardcastle JD, Chamberlain JO, Robinson MH, Moss SM, Amar SS, Balfour TW, et al. Randomised controlled trial of faecal-occult-blood screening for colorectal cancer. *Lancet.* 1996; 348 (9040): 1472-7. DOI: 10.1016/S0140-6736(96)03386-7.
8. Young GP, Rozen P, Levin B. How should we screen for early colorectal neoplasia? In: Rozen P, Young GP, Levin B, Spann SJ, Editors. *colorectal cancer in clinical practice. Prevention, Early detection and management.* 2nd ed., London: Taylor & Francis, 2005. pp 97-130.
9. Winawer SJ, Fletcher RH, Miller L, Godlee F, Stolar MH, Mulrow CD, et al. Colorectal cancer screening: clinical guidelines and rationale. *Gastroenterology.* 1997; 112 (2): 594-642.
10. Subramanian S, Amonkar MM, Hunt TL. Use of colonoscopy for colorectal cancer screening: evidence from 2000 National Health Interview Survey. *Cancer Epidemiol Biomarkers Prev.* 2005; 14 (2): 409-16. DOI: 10.1158/1055-9965.EPI-03-0493.
11. Lieberman DA, Weiss DJ. Veterans Affairs Cooperative Study Group 380. One-time screening for colorectal cancer with combined fecal occult blood testing and examination of the distal colon. *N Engl J Med.* 2001; 345 (8): 555-60. DOI: 10.1056/NEJMoa010328.
12. Berry DP, Clarke P, Hardcastle JD, Vellacott KD. Randomized trial of the addition of flexible sigmoidoscopy to fecal occult blood testing for colorectal neoplasia population screening. *Br J Surg.* 1997; 84 (4): 1274-6.
13. Mandel JS, Church TR, Bond JH, Ederer F, Geisser MS, Mongin SJ, et al. The effect of fecal occult-blood screening on the incidence of colorectal cancer. *N Engl J Med.* 2000; 343 (22): 1603-7. DOI: 10.1056/NEJM200011303432203.
14. Mandel JS, Bond JH, Church TR, Snover DC, Bradley GM, Schuman LM, et al. Reducing mortality from colorectal cancer by screening fecal occult blood. Minnesota Colon Cancer Control Study. *N Engl J Med.* 1993; 328 (19): 1365-71. DOI: 10.1056/NEJM199305133281901.
15. Kudo SE, Kashida H. Flat and depressed lesions of the colorectum. *Clin Gastroenterol Hepato.*

- 2005; 3 (7 supp 1): S33-S36. DOI: 10.1016/s1542-3565(05)00283-1.
16. Konishi F, Morson BC. Pathology of colorectal adenomas: a colonoscopic survey. *J Clin Pathol.* 1982; 35 (8): 830-41. DOI: 10.1136/jcp.35.8.830.
 17. Fuszek P, Horvath HC, Speer G, Papp J, Haller P, Fischer S, et al. Location and age at onset of colorectal cancer in Hungarian patients between 1993 & 2004. The high number of advanced cases supports the need for a colorectal cancer screening program in Hungary. *Anticancer Res.* 2006; 26 (1B): 527-31.
 18. Fazlei MS, Adel MG, Lebaschi AH. Colorectal carcinoma: a retrospective, descriptive study of Age, gender, subsite, stage and differentiation in Iran from 1995 to 2001 as observed in Tehran University. *Dis Colon Rectum.* 2007; 50 (7): 990-5. DOI: 10.1007/s10350-007-0248-z.
 19. Celestino A, Castillo T, Frisancho O, Contardo C, Espejo H, Tomioka C, et al. Colorectal cancer: study on 365 cases. *Rev Gastroenterol Peru.* 1996; 16 (3): 187-96.
 20. Allison JE, Feldman R, Tekawa IS. Hemoccult screening in detecting colorectal neoplasm: sensitivity, specificity and predictive value: long term follow up in a large group practice setting. *Ann Intern Med* 1990; 112 (5): 328-33. DOI: 10.7326/0003-4819-112-5-328.
 21. Ahlquist DA, Wieand HS, Moertel CG, McGill DB, Loprinzi CL, O'Connell MJ, et al. Accuracy of fecal occult blood screening for colorectal neoplasia: a prospective study using Hemoccult and HemoQuant tests. *JAMA.* 1993; 269 (10): 1262-7.
 22. St John DJ, Young GP, Alexeyeff MA, Deacon MC, Cuthbertson AM, Macrae FA, et al. Evaluation of new occult blood tests for detection of colorectal neoplasia. *Gastroenterology.* 1993; 104 (6): 1661-8. DOI: 10.1016/0016-5085(93)90643-q.
 23. Simon JB. Occult blood screening for colorectal carcinoma: a critical review. *Gastroenterology.* 1985; 88 (3): 820-37. DOI: 10.1016/0016-5085(85)90158-1.
 24. Whitlock EP, Lin JS, Liles E, Beil TL, Fu R. Screening for colorectal cancer: a targeted, updated systematic review for the U.S. Preventive Services Task Force. *Ann Intern Med.* 2008; 149 (9): 638-58. DOI: 10.7326/0003-4819-149-9-200811040-00245.
 25. Crespi M, Lisi D. Is colorectal cancer screening by fecal occult blood feasible? *Ann Oncol.* 2002; 13 (1): 47-50. DOI: 10.1093/annonc/mdf070.
 26. Strul H, Arber N. Fecal occult blood test for colorectal cancer screening. *Ann Oncol.* 2002; 13 (1): 51-6. DOI: 10.1093/annonc/mdf076.
 27. Sonnenberg A, Delcò F, Inadomi JM. Cost-effectiveness of colonoscopy in screening for colorectal cancer. *Ann Intern Med.* 2000; 133 (8): 573-84. DOI: 10.7326/0003-4819-133-8-200010170-00007.
 28. Levin B, Hess K, Johnson C. Screening for colorectal cancer. A comparison of 3 fecal occult blood tests. *Arch Intern Med.* 1997; 157 (9): 970-6.

Citation of this article

Haldar GC, Hoque AKMA, Das A, Majumder RC, Karmakar P. Evaluation of Fecal Occult Blood Test for Screening of Colorectal Carcinoma. *Eastern Med Coll J.* 2023; 8 (2): 48-53.