



Original Article

Evaluation of Computed Tomography Guided Fine Needle Aspiration Cytology of Lung Mass with Histological Correlation

Haldar GC¹, Saibal AA², Das RK³, Gupta JD⁴, Karmakar P⁵, Das U⁶

Abstract

Background: Lung cancer is the major cause of cancer related deaths all over the world. CT guided FNAC of lung mass is an effective modality to diagnose lung cancer. **Objective:** Aim of our study was to evaluate the pathological spectrum of diseases in the lesions of the lung through CT guided FNAC. **Materials and Methods:** This prospective study was carried out in Eastern Medical College Hospital and a specialized diagnostic center in Cumilla, Bangladesh. Fifty-three (53) patients were selected by convenience sampling. After informed consent CT guided lung FNACs were performed during period of 1 year from July 2021 to June 2022 and cytological diagnoses were made. Reported results and relevant data were recorded in the data sheet and then analyzed by standard statistical method. **Results:** Total number of cases was 53 and adequate samples were obtained in 100% cases. Among the adequate samples 39 (73.58%) were malignant and 14 (26.42%) were benign or nonmalignant lesions. Among the benign lesions, pulmonary TB cases were most common (8 cases, 57.14%) followed by lung abscess (2 cases, 14.29%). Adenocarcinoma (18 cases, 46.15%) was the most common type of bronchogenic carcinoma followed by squamous cell carcinoma (17 cases, 43.59%), small cell carcinoma (3 cases, 7.69%), NHL (1 case, 2.56%). In male cases, squamous cell carcinoma (41.03%) was the most common type of bronchogenic carcinoma, followed by adenocarcinoma (30.77%). In female cases, adenocarcinoma was the most common type (15 cases, 38%) of bronchogenic carcinoma, followed by squamous cell carcinoma (2 cases, 56%). **Conclusion:** FNAC is a safe method for the evaluation of lung mass and nodules, and it enables sub-classification of bronchogenic carcinoma in most cases. It is also useful for the diagnosis of tuberculous pulmonary nodules.

Keywords: Bronchogenic Carcinoma, FNAC, Lung Mass.

Received: October 15, 2022; **Accepted:** November 30, 2022

Introduction

Diseases of the lung can be conveniently divided into diffuse and nodular categories. The nodular or mass lesions are more amenable to diagnose with Fine Needle Aspiration (FNA) of the lung. Different studies showed it can diagnose malignancy in 93-96.6% cases^{1,2}. Computed tomography guided fine needle aspiration cytology (CT guided FNAC) is a well-known modality for characterization of lung masses³. It has been used to differentiate lung masses into benign, malignant, and inflammatory types⁴. Furthermore, its use has been extended in differentiating lung malignancy into different cytopathological types which aid in proper management of the malignant lesion³.

CT guided FNAC is widely recognized as an accurate and sensitive way for the diagnosis of Lung mass lesions⁵. It is a simple less invasive diagnostic

method of relatively low cost, with negligible mortality and limited morbidity⁶. In 1976 Haaga and Alfid reported CT guided biopsy and since then this procedure has been shown to be both effective and accurate⁷. The diagnostic accuracy is reported to be more than 80% in benign disease and more than 90% in malignant disease⁸. Relative contraindications to image guided FNAC are severe chronic obstructive airway disease, bleeding diathesis, contralateral pneumonectomy and pulmonary hypertension⁹.

The quality of a lung FNAC service can be evaluated by the overall percentage of diagnosis, the review of routine cases as well as the correlation with histological and clinical follow-up¹⁰⁻¹². In view of the relative paucity of published studies regionally, a prospective study of the lung FNAC diagnosis was performed to see the pattern of FNAC diagnosis of

¹Dr Ganesh Chandra Haldar, Associate Professor, Dept. of Medicine, Eastern Medical College & Hospital, Cumilla, Bangladesh.

²Dr Md Arif Akbar Saibal, Professor, Dept. of Medicine, Eastern Medical College & Hospital, Cumilla, Bangladesh.

³Dr Ruhini Kumar Das, Professor & Head, Dept. of Pathology, Eastern Medical College, Cumilla, Bangladesh.

⁴Dr Joydev Dutta Gupta, Professor & Head, Dept. of Pathology, Cumilla Medical College, Cumilla, Bangladesh.

⁵Dr Pijush Karmakar, Associate Professor, Department of Biochemistry, Eastern Medical College, Cumilla, Bangladesh.

⁶Dr Uma Dash, Consultant Sonologist, Moon Hospital, Cumilla, Bangladesh.

Address of correspondence: Dr Ganesh Chandra Haldar, Associate Professor, Dept. of Medicine, Eastern Medical College & Hospital, Cumilla, Bangladesh. Mobile: +8801711160427, Email: drgch53117415@gmail.com

lung lesions and to analyze and compare the data with published figures.

Materials & Methods

This prospective study was carried out in Eastern Medical College Hospital and a specialized diagnostic center in Cumilla, Bangladesh. Fifty-three (53) patients were selected by convenience sampling. After informed consent CT guided lung FNACs were performed during period of 1 year from July 2021 to June 2022 and cytological diagnoses were made. Reported results and relevant data were recorded in the data sheet and then analyzed by standard statistical method.

The period of study was one year, from July 2021 to June 2022. All the cases had nodular or mass lesions in the lung and underwent a CT guided FNAC. Before the FNAC, routine biochemical, hematological, and plain chest X-ray (anterior/posterior and lateral views) were carried out. Then CT-guided FNAC was carried out by a histopathologist as an outpatient procedure in lab after explaining the risks and benefits. Informed consent was obtained from every subject. Aspirations were performed using 20-to-25-gauge spinal needles attached to 10 ml syringe under CT guidance. If the first aspiration was considered of doubtful adequacy, a second FNA was performed. No patients were required to have more than two aspirations.

All the patients were kept under observation for four hours. Apart from minor chest pain, no complaints were noted. Patients were instructed to report if necessary. After aspiration smears were prepared in plain glass slides, dried in air, and fixed in alcohol for routine Papanicolaou staining. The stained slides were examined under the microscope and cytological diagnoses were made. In case of malignancy, cytological subclassification of bronchogenic carcinoma was done according to WHO classification. Benign lesions where exact cytological diagnoses were not possible, were labelled as negative for malignant cells. Reported results and relevant data were recorded in the data sheet and then analyzed by standard statistical method. For statistical analysis patients were divided into five age groups, each comprising of a decade except the first and the last group. The first

group consists of patients of 40 years or below and the last group consists of patients of 81 years and above.

Results

Among 53 cases, 41 were male and 12 were female with male female ratio 3.4:1. Age ranges from 20 years to 92 years with mean age 61.45±18.56 years. Cytological examination showed that 14 (26.42%) cases were benign, and 39 (73.58%) cases were malignant with benign malignant ratio 1:2.79. Age range of patients with benign lesions was 20–70 years with mean age 53±13.93 years (Table-I).

Among the benign lesions, pulmonary tuberculosis was the most common type (eight cases, 57.14%) followed by lung abscess (two cases, 14.29%) (Figure-1).

Table-I: Distribution of subjects in benign and malignant lung lesions according to age

Age	Benign	Malignant	Benign: Malignant
<40 years	2	2	1:1
41-50years	2	0	-
51-60years	6	13	1: 2.17
61-70years	4	17	1: 4.25
71-80years	0	5	-
81+ years	0	2	-
Total	14	39	1: 2.79

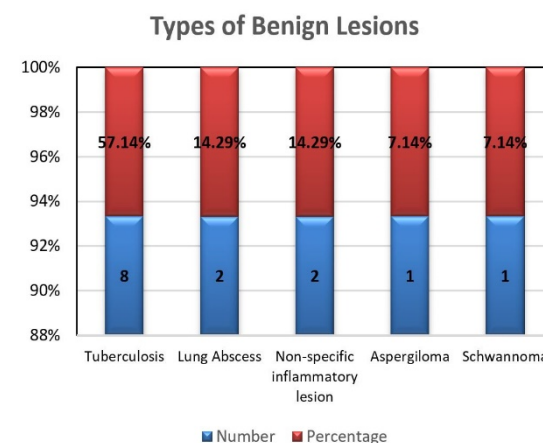


Figure-1: The types of benign lesions (n=14)

Table-II: Types of malignant lesions (n=39)

Type of lesions	Number (%)	Male (%)	Female (%)	M:F ratio
Adeno carcinoma	18 (46.15%)	12 (30.77%)	6 (15.38%)	2:1
Squamous cell carcinoma	17 (43.59%)	16 (41.03%)	1 (2.56%)	16:1
Small cell carcinoma	3 (7.69%)	1 (2.56%)	2 (5.13%)	1:2
Non-Hodgkin lymphoma	1 (2.56%)	1 (2.56%)	0	-

Malignant lesions were more common in male (30 cases out of 39 cases) with an M: F ratio 3.3: 1. Age range of subjects of malignant lesions was 35-92 years, mean age 64.49 ± 14.84 years. Adenocarcinoma was the most common type followed by squamous cell carcinoma. In male squamous cell carcinoma was the most common lesion (16 cases, 41.03%), followed by adenocarcinoma (12 cases, 30.77%) whereas in female adenocarcinoma was the most common (6 cases, 15.38%), followed by squamous cell carcinoma (1 case, 2.56%) (Table-II).

Discussion

Lung cancer is the most frequent cause of major cancer incidence and mortality worldwide^{13,14}. Lung cancer diagnosis is a multidisciplinary process requiring correlation with clinical, radiologic, molecular, and surgical information where histopathology is the backbone of this classification¹⁵. Different studies showed that in cytological diagnosis of lung lesions prevalence of malignancy ranges from 61% to 70.7% whereas prevalence of benign lesion ranges from 29.3% to 39%, excluding the inadequate samples^{16,17}. The prevalence of malignancy in our study was quite similar with the above studies but was significantly less than 81.8% and 80.5% found in another study done by Stewart CJ, et al¹⁶ and Sing J, et al¹⁸.

Present study showed a higher incidence of adenocarcinoma which was like the study of Stewart CJ, et al¹⁶ and Biswas MMA, et al¹⁹. However, Gouliamos AD, et al¹² found squamous cell carcinoma as the commonest diagnosis. Prevalence of small cell carcinoma of present study was quite like some other studies^{16,20}. The prevalence of adenocarcinoma in the present study could also be explained by the fact that adenocarcinomas are more often peripherally located and thus more amenable to diagnosis by transthoracic FNAC²⁰.

Wahbah et al²¹ also showed histologically adenocarcinoma was the most common type of bronchogenic carcinoma, followed by small cell carcinoma and large cell carcinoma. This study demonstrated that squamous cell carcinoma was the most common type of lung cancer in male whether adenocarcinoma was the most common type of lung cancer in female. These findings are like the findings of other studies^{16,17,20}.

Our study reaffirms the use of FNAC in the diagnosis of pulmonary tuberculosis (PTB). In series based on western populations, TB cases constituted 0.2-1.5% of all FNAC cases for lung nodules^{12,22}. In Singapore, TB was found in 5.3% of cases of lung FNAC¹⁹. In studies from India, the corresponding figures range from 2.1% to 20%¹¹. In our study TB was found in 57.14% of benign lung FNAC cases.

Clearly, TB figures prominently as an important differential diagnosis in the clinical problem of lung nodule, particularly in Asia.

FNAC is an accurate and safe method for the evaluation of lung nodules or masses, and it enables sub-classification of bronchogenic carcinomas in most cases and is also useful for the diagnosis of tuberculous pulmonary nodules²³.

Conclusion

CT guided FNAC can diagnose pulmonary mass and it enables sub-classification of bronchogenic carcinoma accurately leading to early diagnosis which causes less morbidity and mortality as treatment can be started early. It is also useful for the diagnosis of tuberculous pulmonary nodules.

Conflict of interest

The authors declared no competing interests.

References

1. DeMay RM. The Art and Science of Cytopathology, 2nd ed. Chicago: ASCP Press; 2012. pp 1161-73.
2. Khouri NF, Stitik FP, ErozanYS, Gupta PK, Kim WS, Scott WW, et al. Transthoracic needle aspiration biopsy of benign and malignant lung lesions. *Am J Roentgenol.* 1985; 144 (2): 281-8.
3. Martin HE, Ellis EB. Biopsy by needle puncture and aspiration. *Ann Surg.* 1930; 92 (2): 169-81.
4. Madan M, Bannur H. Evaluation of FNAC in lung diseases. *Turk J Path.* 2010; 26 (1): 1-6.
5. Gangopadhyay M, Chakrabarti I, Ghosh N, Giri A. Computed tomography guided fine needle aspiration cytology of mass lesions of lung: Our experience. *Indian J Med Paediatr Oncol.* 2011; 32 (4): 192-6.
6. Yang W, Sun W, Li Q, Yao Y, Lv T, Zeng J, et al. Diagnostic Accuracy of CT-Guided Transthoracic Needle Biopsy for Solitary Pulmonary Nodules. *PLoS One.* 2015; 10 (6): e0131373.
7. Haaga JR, Alfydi RJ. Precise biopsy localization by computer tomography. *Radiology.* 1976; 118 (3): 603-7.
8. Geraghty PR, Kee ST, Mc Farlane G, Razavi MK, Sze DY, Dake MD. CT-guided transthoracic needle aspiration biopsy of pulmonary nodules: needle size and pneumothorax rate. *Radiology.* 2003; 229 (2): 475-81.
9. Mohammad MG. CT guided fine needle aspiration cytology in the diagnosis of thoracic lesions. *J Indian Med Assoc.* 2001; 99 (10): 1-5.
10. Zarbo RJ, Fenglio-Preiser CM. Inter institutional database for comparison of performance in lung fine needle aspiration

- cytology. A college of American pathologist Q-probe study of 5264 cases with histological correlation. *Arch Pathol Lab Med.* 1992; 116 (5): 463-70.
11. Das DK, Pant CS, Pant JN, Sodhani P. Transthoracic (percutaneous) fine needle aspiration cytology diagnosis of pulmonary tuberculosis. *Tuber Lung Dis.* 1995; 76 (1): 84-9.
 12. Gouliamos AD, Giannopoulos DH, Panagi GM, Fletoridis NK, Deligeorgi-Politi HA, Vlahos LJ. Computed tomography- guided fine needle aspiration of peripheral lung opacities. An initial diagnostic procedure? *Acta Cytol.* 2000; 44 (3): 344-8.
 13. Boyle P, Levin B. *World Cancer Report 2008.* International Agency for Research on Cancer (IARC), Geneva, 2008. Available at: <https://publications.iarc.fr/Non-Series-Publications/World-Cancer-Reports/World-Cancer-Report-2008> [Accessed on May 11, 2022]
 14. Parkin DM, Bray F, Ferlay J, Pisani P. Global cancer statistics, 2002. *CA Cancer J Clin.* 2005; 55 (2): 74-108.
 15. Travis WD, Brambilla E, Noguchi M, Nicholson AG, Geisinger KR, Yatabe Y, et al. International Association for the Study of Lung Cancer/American Thoracic Society/European Respiratory Society International Respiratory Society International Multidisciplinary Class of Lung Adenocarcinoma. *J Thorac Oncol.* 2011; 6 (2): 244-85.
 16. Stewart CJ, Stewart IS. Immediate assessment of fine needle aspiration cytology of lung. *J Clin Pathol.* 1996; 49 (10): 839-43.
 17. Tan KB, Tamboo TP, Wang SC, Nilsson B, Rajwanshi A, Salto-Tellez. Audit of transthoracic fine needle aspiration of the lung: cytological sub classification of bronchogenic carcinomas and diagnosis of tuberculosis. *Singapore Med J.* 2002; 43 (11): 570-5.
 18. Sing J, Garg L, Setia V. Computed tomography (CT) guided transthoracic needle aspiration cytology in difficult thoracic mass lesions-not approachable by USG. *Indian J Radiol Imaging.* 2004; 14 (4): 395-400.
 19. Biswas MMA, Shirin A, Sikder AM, Saha R. CT-Guided FNAC of Lung Lesions and Cytological Sub-Classification of Bronchogenic Carcinoma of 246 cases at a Tertiary Care Hospital. *J Enam Med Col.* 2020; 10 (3): 169-73.
 20. Husain NA. The lung. In: *Robbins Pathologic basis of disease*, 9th ed. Philadelphia: Elsevier Saunders; 2014. pp 669-724.
 21. Wahbah M, Boroumand N, Castro C, El-Zeky F, Eltorkey M. Changing trends in the distribution of histologic types of lung cancer: a review of 4,439 cases. *Ann Diagn Pathol.* 2007; 11 (2): 89-96.
 22. Reilly PE, Brueckner J, Silverman JF. Value of ancillary techniques in fine needle aspiration cytology of the lung. *Acta Cytol.* 1994; 38 (2): 144-50.
 23. Mondal SK, Nag D, Das R, Mandal PK, Biswas PK, Osta M. Computed tomogram guided fine-needle aspiration cytology of lung mass with histological correlation: A study in Eastern India. *South Asian J Cancer.* 2013; 2 (1): 14-8.

Citation of this article

Haldar GC, Saibal AA, Das RK, Gupta JD, Karmakar P, Das U. Evaluation of Computed Tomography Guided Fine Needle Aspiration Cytology of Lung Mass with Histological Correlation. *Eastern Med Coll J.* 2023; 8 (1): 24-7.