



Case Report

Adenoid Cystic Carcinoma: A Case Report

Hossen I¹, Chowdhury FH², Shil NA³, Mirza Md AQ⁴, Chowdhury MA⁵, Ullah KM⁶

Abstract

A 52-year-old male patient attended on 13 July 2022 with the complaints of pain in right ear and voice change for 1 month and cough for 15 days, difficulty in swallowing along with weight loss for same duration of past 1 month. Examination revealed a swelling on the right side of neck over the submandibular region also with cervical lymphadenopathy (level IB). After all evaluation, all biochemical tests were normal, but Fiber Optic Laryngoscopy (FOL) revealed right vocal cord palsy, USG of neck revealed right submandibular mass and cervical lymphadenopathy, CT scan of Neck up to Mid-chest revealed no pathology and last but not the least pre-operative FNAC was done and revealed organizing abscess. After that patient underwent excision of the right submandibular mass and removal of few superficial group of lymph nodes. Post-operative histopathology revealed Adenoid Cystic Carcinoma (ACC). Patient presented to us with no complain about submandibular gland or fine needle aspiration cytology (FNAC) also doesn't indicate about malignancy, but our clinical suspicion was submandibular gland malignancy, that's why we have decided to publish this case report. After operation Patient was fine till his last follow-up.

Keywords: Abdominal wall mass, Benign mesenchymal tumor, Endometrioma, Desmoid tumor.

Received: November 10, 2022; **Accepted:** December 12, 2022

Introduction

Adenoid cystic carcinoma (ACC) of the head and neck is a rare epithelial malignant tumor arising from exocrine glands such as the major and minor salivary glands of paranasal sinuses or the external auditory canal¹. ACC was first described by three Frenchmen (Robin, Lorain and Laboulbene) in two articles published in 1853 and 1854². This carcinoma accounts for less than 1% of all head and neck malignancies and approximately 10% of all salivary gland neoplasms³. ACC was described by Conley and Dingman as one of the most biologically destructive and unpredictable tumors of the head and neck⁴. Though the tumor is slow growing compared to other carcinomas, the long-term prognosis is poor because of its high frequency of local recurrence and distant metastasis⁵.

It is demonstrated in different studies that facial nerve involvement is a classical finding of the disease⁶. In our case, there was a good distraction diagnosing the disease only by the biochemical and radiological findings. Even the FNAC and CT-SCAN neck up to mid chest couldn't possibly was conclusive or give us minimum clue towards the final diagnosis, but the suspicious findings were the right vocal cord palsy, weight loss and the palpation of the tumor was hard and fixed. Nevertheless, this type of case is such of those challenges that proves

to not always depend on the investigations and as a literature it will be beneficial for all head neck surgeons to never exclude malignancy from their list until final diagnosis.

Case report

A 52-years-old male patient non-diabetic, normotensive, came with the complaints of right sided earache, voice change, weight loss for 1 month and cough for last 15 days. He had no history of any family cancer or tuberculosis.

On clinical examination, there was a palpable small mass over the right sub mandibular region approximately about 2.5 cm x 2 cm x 2 cm. It was hard, globular in shape, fixed with underlying structure, free from overlying skin, normal in temperature, well defined margin, and non-tender. On bi-manual digital palpation the gland revealed no evidence of any stone. There were also palpable a few superficial cervical lymph nodes on the right submandibular region on level IB. No other neck nodes were palpable, nor any extra complaints of headache, body ache or any significant clue that could be suspicious for metastasis.

All the biochemical reports like complete blood count (CBC), serum creatinine, chest X-ray P/A

¹Dr Iqbal Hossen, Registrar ENT-HNS, Anwer Khan Modern Medical College, Dhaka, Bangladesh.

²Dr Farid Hossain Chowdhury, Resident Medical Officer, ENT-HNS, Square Hospitals, Dhaka, Bangladesh.

³Dr Niloy Ananda Shil, Medical Officer, ENT-HNS, Anwer Khan Modern Medical College, Dhaka, Bangladesh.

⁴Prof Dr Md Aminul Qader Mirza, Professor and Head of Anesthesiology, Anwer Khan Modern Medical College, Dhaka, Bangladesh.

⁵Prof M Alamgir Chowdhury, Professor and Head, ENT-HNS, Anwer Khan Modern Medical College, Dhaka, Bangladesh.

⁶Prof Dr Md Kalim Ullah, Principal and Professor of ENT, Eastern Medical College, Cumilla, Bangladesh.

Address of Correspondence: Dr Iqbal Hossen, Registrar ENT-HNS, Anwer Khan Modern Medical College, Dhaka, Bangladesh. Email: nobelhossenjenishan@gmail.com

view was normal, ECG and Echocardiography (LVEF 63%) were also normal. So, routine tests for GA fitness were all done and were non-significant. Due to the voice hoarseness, FOL was done and revealed right vocal cord palsy. Being suspicious CT scan of neck up to mid chest suspecting bronchogenic carcinoma was done but surprisingly revealed normal findings. The USG of neck revealed small right sub mandibular mass about 2.6 cm X 2 cm X 2 cm, along with few cervical lymphadenopathies. Finally, FNAC was done from the right sub mandibular swelling, and it revealed a report saying organizing abscess which was very unexpectedly misleading.

After that, as per the next step of treatment plan, patient undergone excision of right submandibular gland mass along with dissection of the palpable small superficial groups of cervical lymph nodes. No significant adhesion was found neither with any major vessels and midline structures. After operation, the specimen was sent for histopathology and was reported as adenoid cystic carcinoma (Figure-1).

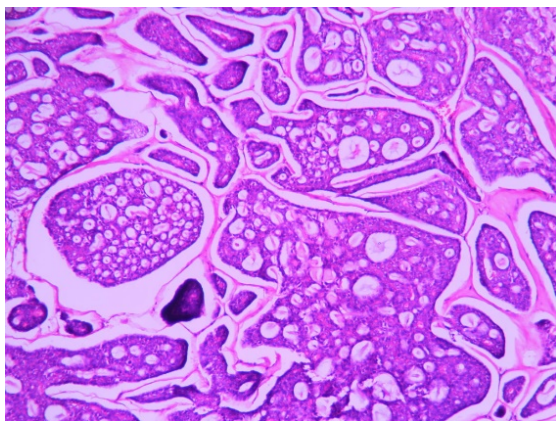


Figure-1: Photomicrograph of Adenoid Cystic Carcinoma (ACC) of salivary gland

Discussion

In research, it has been said that if 5,00,000 people are having cancer per year, 1,200 are ACC among them. Due to peri-neural invasion, pain is a general complaint, so as in our patient too in his right ear. So, pain is never should be uninvestigated properly and completely until the exact cause is found and in ACC although radical neck dissection is advised but not routinely done until and unless there are several neck nodes involvement. In patients with the spread of disease to the cervical lymph nodes, a modified radical neck dissection is the preferred route. However, despite good surgical techniques the median time of local recurrence is five years while distant recurrences oscillate around seven years, with the primary site of distant metastasis lung, followed by brain and bone^{6,7}. Skillful surgery along

with a big cuff of normal tissue around the tumor is necessary to prevent recurrence⁸.

Appropriate oral hygiene maintaining and smoking is discouraged to prevent oral cavity diseases and cancers⁹. Overall having a good survival rate, no family belonging, and less specific risk factors are the causes of nothing to worry about for this cancer now a day. Salivary gland cancers have a graph of still a high significance in our country as most people are habituate of various tobacco, betel nuts chewing¹⁰.

Adenoid cystic carcinomas are type of cancers that can occur apart from the head and neck region, also from glands in the breast, reproductive tract, skin, and trachea, have also been reported¹¹. Commonly it is the most familiar cancer of minor salivary glands, submandibular gland. As in our case it was of submandibular gland, difficult presentation and misleading investigation results can be a suffering to reach the diagnosis easily is the purpose to share this case.

Patients of ACC present with swelling in neck, difficulty in swallowing, hoarseness of voice, occasional fever and most importantly it has peri-neural invasion so that presents with pain or referred pain. Also, if facial nerve gets involved can present with facial palsy, facial pain but rarely. The good things are after surgery the survival rate is 10-20 years^{6,7}, having no specific risk factor or agent although oral hygiene maintenance and smoking avoidance is advised as always to prevent any salivary gland cancers.

On the follow-up visits the patient was stable and referred to oncologist for radiotherapy purpose and further management. As postoperative radiotherapy has been shown to reduce the risk of local recurrence and to avoid the need for radical surgery and many authors would consider this the standard of care^{12,13}.

Conclusion

Early diagnosis is important, but the key fact of this case is to understand the misguidance of investigations and Adenoid cystic carcinomas are still a case of interest in our low socio-economic country are not so easily diagnosed with financial limitations of patient and atypical presentations to distract. Our patient was good till the last follow-up.

Conflict of interest

The authors declare that there is no conflict of interests regarding the publication of this paper.

References

1. Dodd RL, Slevin NJ. Salivary gland adenoid cystic carcinoma: a review of chemotherapy

- and molecular therapies. *Oral Oncol.* 2006; 42 (8): 759-69.
2. Stell PM. Adenoid cystic carcinoma. *Clin Otolaryngol.* 1986; 11 (4): 267-91.
 3. Spiro RH, Huvos AG, Strong EW. Adenoid cystic carcinoma of salivary origin. A clinicopathologic study of 242 cases. *Am J Surg.* 1974; 128 (4): 512-20.
 4. Conley J, Dingman DL. Adenoid cystic carcinoma in the head and neck (cylindroma). *Arch Otolaryngol.* 1974; 100 (2): 81-90.
 5. Spiro RH, Huvos AG. Stage means more than grade in adenoid cystic carcinoma. *Am J Surg.* 1992; 164 (6): 623-8.
 6. Chen AM, Bucci MK, Weinberg V, Garcia J, Quivey JM, Schechter NR, et al. Adenoid cystic carcinoma of the head and neck treated by surgery with or without postoperative radiation therapy: prognostic features of recurrence. *Int J Radiat Oncol Biol Phys.* 2006; 66 (1): 152-9.
 7. Bouaichi A, Aimad-Eddine S, Mommers XA, Ella B, Zwetyenga N. Intra-mandibular adenoid cystic carcinoma. *Rev Stomatol Chir Maxillofac Chir Orale.* 2014; 115 (2): 100-4.
 8. Bruzgielewicz A, Osuch-Wójcikiewicz E, Majszyk D, Chęciński P, Nyckowska J, Zawadzka B, et al. Rak gruczołowato-torbielowaty głowy i szyi--doświadczenie 10 lat [Adenoid cystic carcinoma of the head and neck--a 10 years experience]. *Otolaryngol Pol.* 2011; 65 (5 Suppl): 6-11.
 9. McClure JB, Riggs KR, St John J, Cerutti B, Zbikowski S. Understanding oral health promotion needs and opportunities of tobacco quitline callers. *Public Health Rep.* 2012; 127 (4): 401-16.
 10. Wu F, Parvez F, Islam T, Ahmed A, Rakibuz-Zaman M, Hasan R, et al. Betel quid use and mortality in Bangladesh: a cohort study. *Bull World Health Organ.* 2015; 93 (10): 684-92.
 11. Chae YK, Chung SY, Davis AA, Carneiro BA, Chandra S, Kaplan J, et al. Adenoid cystic carcinoma: current therapy and potential therapeutic advances based on genomic profiling. *Oncotarget.* 2015; 6 (35): 37117-34.
 12. Shen C, Xu T, Huang C, Hu C, He S. Treatment outcomes and prognostic features in adenoid cystic carcinoma originated from the head and neck. *Oral Oncol.* 2012; 48 (5): 445-9.
 13. Garden AS, Weber RS, Morrison WH, Ang KK, Peters LJ. The influence of positive margins and nerve invasion in adenoid cystic carcinoma of the head and neck treated with surgery and radiation. *Int J Radiat Oncol Biol Phys.* 1995; 32 (3): 619-26.

Citation of this article

Hossen I, Chowdhury FH, Shil NA, Mirza Md AQ, Chowdhury MA, Ullah KM. Adenoid Cystic Carcinoma: A Case Report. *Eastern Med Coll J.* 2023; 8 (1): 28-30.