

Review Article

Pseudomyxoma peritonei: A Review

SM Kamal¹, MA Bakar², MY Ali³, MA Ahad⁴

Abstract :

Pseudomyxoma peritonei (PMP) is rare clinical entity characterized by abundant extracellular mucinous material in the peritoneal cavity and tumoural implants on the peritoneal surfaces. The origin of PMP is controversial. It often arises from the goblet cells of large bowel or appendix. There is increase in MUC-2 secreting cells and accumulation of excessive mucin secreted by these cells in the peritoneal cavity. A ruptured appendiceal mucinous adenoma is the most common origin. Low grade ovarian malignancy is often associated. Patient may present with growing abdominal masses associated with abdominal pain, nausea, vomiting, fatigue and weight loss. Ultrasonogram and CT scan of the abdomen have role in diagnosis but diagnosis is often difficult before laparotomy or laparoscopy. Debulking surgery with intraperitoneal hyperthermic chemotherapy is the treatment.

Key words: Pseudomyxoma peritonei, Mucinous material.

Introduction :

Pseudomyxoma peritonei (PMP) is an uncommon condition characterized by abundant extracellular mucinous material in the peritoneal cavity and tumoural implants on the peritoneal and epiploic surfaces. It was first described by Rokitsansky in 1842. Werth in 1884 observed an association with ovarian mucinous tumour and gave the name of Pseudomyxoma peritonei because of chemical differences with other types of mucin that has been analysed before. Biochemical analysis of the mucinous material of PMP revealed 95% water and 2% acetosoluble lipid. The remainder was composed of glycoprotein principally galactose and mannosamines¹. The clinical presentation of Pseudomyxoma peritonei

11. Dr. S M Kamal, FCPS (Medicine), MACP, Associate Professor, Department of Medicine, Khulna Medical College, Khulna.

2. Dr. Md. Abu Bakar, FCPS (Medicine), FRCP, Professor, Department of Medicine, Khulna Medical College, Khulna.

3. Dr. Md. Yusuf Ali, FCPS (Medicine), Professor, Department of Medicine, Faridpur Medical College, Faridpur.

4. Dr. Md. Abdul Ahad, FCPS (Medicine), MD (Gastroenterology), FACP, Professor, Department of Gastroenterology, Khulna Medical College, Khulna.

Address of correspondence :

Dr. S M Kamal, FCPS (Medicine), MACP, Associate Professor, Department of Medicine, Khulna Medical College, Khulna.
Mobile: +88-01716208746, Email: smkamal10@gmail.com

(PMP) is caused by overwhelming increase in MUC-2 secreting cells and accumulation of excessive mucin secreted by these cells in the peritoneal cavity with no place of drainage². The accumulated mucinous material gives the appearance of gelatinous masses. So the condition is called "Jelly belly". PMP present at laparotomy with septate gelatinous masses (Figure-1)³. PMP has the presenting features that mimic some common disease such as appendicitis. Ovarian tumour, growing abdominal mass, hydrocele and scrotal mass. After having many investigations, laparotomy often confirms the diagnosis. This review article aims to provide informations regarding the Pseudomyxoma peritonei (PMP), the disease of mucinous gelatinous ascites, which is a rare clinical entity.

Epidemiology :

PMP is a relatively rare condition. Incidence is one per million per year and encountered in 2 of 10,000 laparotomies with gelatinous masses. It is three to four times more in women than in men. The median age of presentation is 54 years⁴.

Aetiology :

The origin of PMP is very controversial. It often arises from goblet cells of large bowel or appendix. Over expression of the gene MUC-2 responsible for mucin

secretion is noted in PMP for which appendiceal origin has been demonstrated⁵. The association with a appendiceal cystic tumour was reported in 1901 by Franckel. Commonly it arises from the mucinous tumour of the appendix and occasionally from the ovary, colon, rectum, stomach, gall bladder, bile duct, small intestine, urinary bladder, urachus, lung, breast, pancreas and fallopian tube¹. Some times this condition arises from retroperitoneal tissue, which is known as pseudomyxoma extraperitonei⁶.

PATHOLOGY :

Pseudomyxoma peritonei is characterized by mucin accumulation in the peritoneal cavity and mucinous implants are found on all peritoneal surfaces and the omentum⁷. There is increase in MUC-2 secreting cells and accumulation of excessive mucin secreted by these cells in the peritoneal cavity with no place of drainage². The origin of the tumour is frequently undiscovered. The most common pathology is development of a mucinous adenoma in the appendix leading to obstruction and rupture of the appendix with dissemination of the tumour cells in the peritoneal cavity⁸. Peritoneal cavity is filled with septate gelly like fluid. The accumulated mucinous material gives the appearance of gelatinous masses. So the condition is called jelly belly. The peritoneum is studded with thick nodules full of gelly like material. Small intestine is spared but pelvic cavity is involved. Appendix and ovaries may not be visualized due to frozen structures⁴. The mucin sets on the peritoneal surfaces, give compression on the vessels, hepatic hilum, gastro intestinal tract and other abdominal structures. There is distortion and impaired function of the visceral organs in the abdomen^{7,9}. The gelatinous mucinous material may be diffusely distributed in the abdominal cavity. The gelatinous substance at hepatic hilum can cause obstruction of the biliary tract. Successively the mucus can solidify, generating an intestinal occlusion. On the liver surface there is plenty of solidified masses and the omentum looks like a white mass, very hard, like a stone. Sometimes the mucinous material can localize to the right iliac quadrant of abdomen. Histopathology can demonstrate well differentiated mucinous adenocarcinoma of the appendix and presence of areas of adenocarcinoma in the mucus⁷. This low grade malignancy can spread through the peritoneal cavity. Visceral invasion is rare and metastatic spread by haematogenous or lymphatic route is not seen. Metastatic spread to lungs by transdiaphragmatic seeding has been reported¹⁰.

The Tumoural Redistribution Phenomenon In PMP :

The benign and malignant histologies present different repartitions in the abdomen. Sugarbaker et al described this phenomenon. In PMP the origin of tumour is frequently undiscovered. The most frequent

pathological mechanism is development of a mucinous adenoma in the appendix. Subsequently there is obstruction and rupture of the appendix leading to dissemination of the tumoural cells in the peritoneal cavity. These cells bathe in the gelatinous material and they do not implant in the periappendiceal region. The tumoral cells are taken away by the peritoneal fluid circulation and accumulate in some abdominal and pelvic sites where peritoneal fluid resorption occurs. Some organs are spared, such as bowel, because of its peristalsis. Three less mobile sites are involved; these are antral and pyloric regions, the Bauhin valve region and the rectosigmoid region. Tumour implants occur on the greater and lesser epiploon and beneath the right hemi-diaphragm. Another cause of dissemination is gravity. It leads to frequent involvement of the cul-de-sac of Douglas, the retrohepatic space, the paracolic gutters and the region of the ligament of treitz⁸.

Classification of Peritoneal Gelatinous Disease :

Two classifications have been proposed (Table-1). The first one is proposed by sugarbaker et al who subdivided these diseases into four grades according to the degree of malignancy.

Classification of peritoneal gelatinous disease

Grade 0	Disseminated peritoneal adenomucinosis	<ul style="list-style-type: none"> - Mucin with no malignant cells - Due to rupture of an appendiceal mucinous cystadenoma 	
Grade 1	Peritoneal mucinous carcinomatosis	<ul style="list-style-type: none"> - Presence of tumoural cells - No severe atypia - No important mitosis 	
Grade 2		<ul style="list-style-type: none"> -Mucinous adenocarcinoma with at least 80% of mucine OR -“Classical” adenocarcinoma with smaller amount of mucine 	<ul style="list-style-type: none"> - Mitoses - Atypical cells - Pluristratfied disposition of peripheral cells
Grade 3		<ul style="list-style-type: none"> - Invasion of neighbouring organs by tumoural cells - Possible zones of necrosis - Severe cellular atypia - Intense mitotic activity 	

Grade 0- Disseminated peritoneal adenomucinosis. Mucin with no malignant cells. Due to rupture of an appendiceal mucinous cyst adenoma.

Grade 1- Peritoneal mucinous carcinomatosis. Presence of tumoural cells. No severe atypia. No important mitosis.

Grade 2- Peritoneal mucinous carcinomatosis. Mucinous adenocarcinoma with at least 80% of mucin or classical adenocarcinoma with smaller amount of mucin. Mitosis is present. Atypical cells are present. Pluristratified disposition of peripheral cells.

Grade 3- Peritoneal mucinous carcinomatosis. Invasion of neighboring organs by tumoural cells. Possible zones of necrosis, severe cellular atypia and intense mitotic actions is present¹¹.

The second classification makes the distinction between benign and malignant histologies. Benign cases are called "disseminated peritoneal adenomucinosis". They correspond to grade 0 of the first classification and are associated with ruptured appendiceal mucocele. When malignant features are present, the term "peritoneal mucinous carcinomatosis" is used and corresponds to the grade 1 to 3¹².

Ronnett et al proposed to reserve the term pseudomyxoma peritonei (PMP) for benign histologies and correspond to the disseminated peritoneal adenomucinosis. When malignant features are present, it would be classified as peritoneal mucinous carcinomatosis¹³.

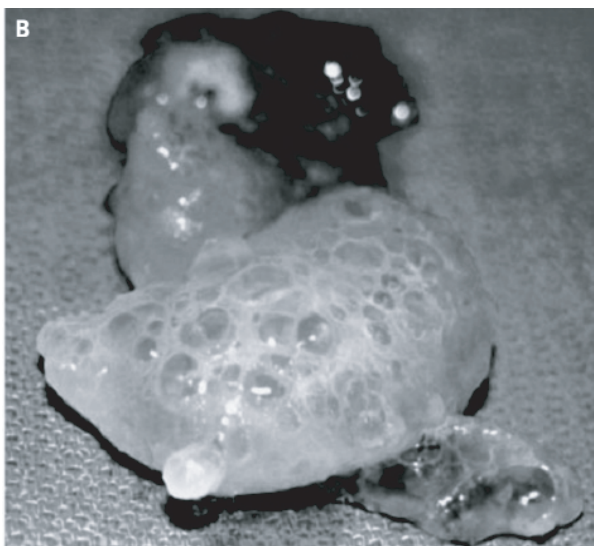


Figure 1: Gelatinous masses

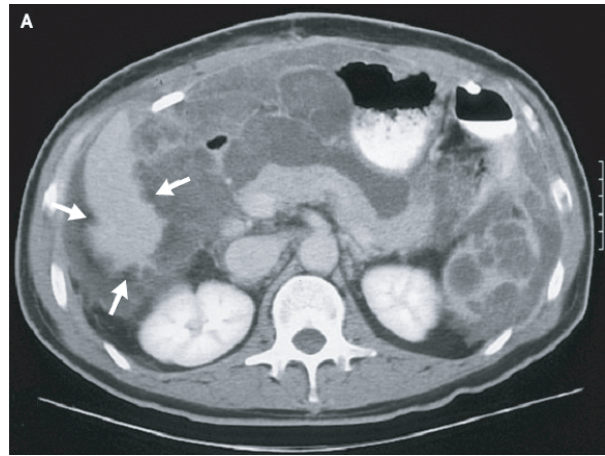


Figure 2: CT scan of the abdomen in PMP

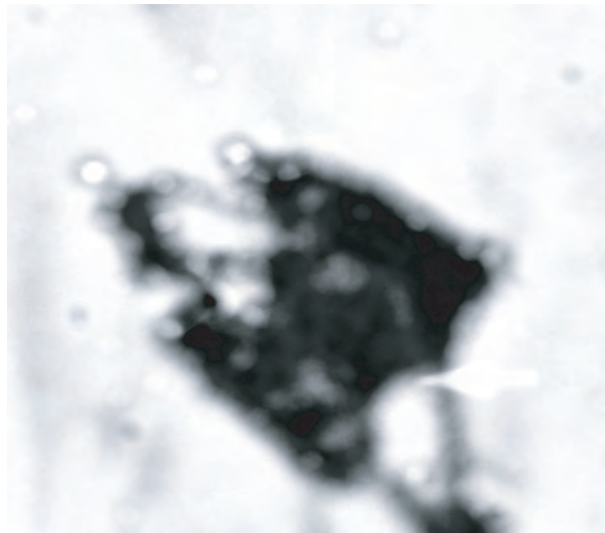


Figure 3: Mucin secreting malignant cells.

Clinical Features :

In a series of 217 cases of PMP, Esquivel et al found suspicion of acute appendicitis as the most common presentation of PMP (27% of cases). A growing abdominal mass was the first symptom in 23% of cases. For women exploration of an ovarian mass was the most common way to make the diagnosis of PMP (39% of cases). Few patients present with new onset inguinal hernia¹⁴. Nausea, vomiting, fatigue and urinary symptoms can occur. Patient may present with false hydrocele or a scrotal mass. Clinical examination can reveal an abdominal mass. An induration of the cul-de-sac of Douglas can be detected by the per rectal digital examination. Extra-peritoneal presentation such as in the pleura, the lung or the pericardial space are less common^{15,16}.

Investigation :

Diagnosis of PMP is often difficult to make before laparotomy or laparoscopy. Laparotomy can reveal a large, mesenteric, septate, gelatinous masses. Plain radiograph gives some features, such as central displacement of intestines, obliteration of psoas shadow, calcification within the gelatinous masses. Contrast radiograph shows the lack of bowel involvement and this describes the non-invasive behaviour of the PMP. Ultrasonography of abdomen detects immobile ascites. Gelatinous masses can mark the hepatic and splenic margins ("Scalloping") by extrinsic pressure¹⁷. Echoendoscopy can be useful. A computed tomographic (CT) scan of the abdomen reveals multiple septate, low attenuated masses throughout the peritoneal space with scalloping of the hepatic and splenic margin. The mucinous material has a similar density to fat. Sometimes progressive punctuate calcification can be found (Figure-II). FNAC will reveal the pathological character of the mucin secreting cells (Figure-III). MRI is useful in studying the involvement of the viscera³.

Tumour Markers :

The utility of tumour markers in PMP has not been largely studied. CEA and CA 19.9 is frequently elevated in PMP¹⁴. CEA is high in 75% cases and CA 19.9 is high in 58% cases. After treatment both markers are diminished but CA 19.9 is more sensitive for detecting the recurrence of the disease. Evidence in favour of an elevation of CA 125 levels in PMP is anecdotic¹⁸. Over expression of the gene MUC-2 responsible for mucin secretion is noted in PMP for which appendiceal origin has been demonstrated⁵.

Ascitic Fluid Analysis: Cytology :

Analysis of the ascitic fluid is often disappointing. Most of the time only low quantities of mucous can be harvested with a few cells. These cells often have benign features. The lack of malignant cells in the ascites does not exclude a carcinomatosis¹.

Management :

Debulking surgery

Debulking surgery has long been considered the treatment of choice for PMP. Most of the mucinous material has to be removed. An appendectomy is systematically performed with histopathological examination. Recurrences are frequent and more than one operation is often necessary. Subsequent operations

are difficult because of adhesions and septation of the gelatinous masses by fibrosis¹.

Ultraradical surgery

The entire peritoneum is inspected and every lesion is excised by diathermy. The expectation is total eradication of PMP lesions. Sugarbaker is the most fervent proponent of this mode of treatment. He frequently performs an antrectomy or a total gastrectomy a rectosigmoidectomy, a right hemicolectomy or a cholecystectomy. This ultra radical surgery is associated with systemic and intraperitoneal chemotherapy. The result is good with 5 years survival rate of 69% (all histological features included)¹⁹.

Laparoscopic surgery

Raj et al proposed laparoscopic surgery for the treatment of PMP. Appendectomy is performed and mucinous material is taken up with a cannula after introduction of a 5% dextrose solution and followed by intraperitoneal chemotherapy. It can be an alternative to laparotomy for first intention debulking surgery. Laparoscopic surgery also has the advantage of reducing any adhesions for possible further operation¹.

Systemic and intraperitoneal chemotherapy associated with surgery.

Smith et al did not observe any differences either with or without systemic chemotherapy associated with surgery. Cough et al noted a lower survival rate with the administration of systemic chemotherapy associated with surgery. This may be due to several factors. Most of the time the tumours are of low grade with a low rate of proliferation. The tumoural cells bathing in an abundant extracellular mucinous matrix have poor vascularization. For these reasons intraperitoneal chemotherapy (IPC) has been proposed. Intraperitoneal chemotherapy (IPC) allows high concentration of cytotoxic agents in the peritoneal cavity without important systemic unwanted effects. The tumoural cells involve abdominal viscera only superficially. Usually intraperitoneal chemotherapy (IPC) is associated with complete debulking surgery or even ultraradical surgery. Most authors agree that IPC improves the survival rate. Hyperthermy is often associated with IPC. Hyperthermic intraperitoneal chemotherapy (HIPC) is administered during operation, allowing the surgeon to facilitate the circulation of a chemotherapeutic agent solution with his hand. Sometimes IPC is given post operatively²⁰. Intraperitoneal chemohyperthermia is performed for 30 minutes at 41-42°C using cisplatin (100 mg/m²) and mitomycin-c (25mg/m²) or 5-fluorouracil and

mitomycin. Morbidity for HIPC has been estimated 39% with paralytic ileus for almost all patients, gastric and intestinal perforations, enteric fistula, pancreatitis, pulmonary embolism, abdominal pain and intra-abdominal abscess in some patients. Leucopenia and thrombocytopenia can occur but there occurs no nephrotoxicity and no cardiotoxicity. Leukocyte fall occurs two days after operation and resolve in three days using filgrastim^{7,21}.

Radiotherapy

External irradiation was previously used for PMP but the results were disappointing and the abdominal morbidity was intolerable. Cough et al observed a positive effect on the survival rate for the preoperative intraperitoneal administration of P¹⁵⁸ and Au⁷ radioisotopes²⁰.

Mucolytic Agents

Many authors recommend the use of mucolytic agents to allow easy drainage of the mucinous material during a palliative operation. Shyr et al tested dextrose 5% and 10% solution but observed no true mucolytic effects²².

Prognosis :

Prognosis is dependant on the histopathological features of the peritoneal gelatinous disease. The mayo clinic team high lights a global survival rate of 53% with a larger median time before recurrence when they performed a resection of all macroscopic tumours. Survival is negatively influenced by abdominal distension, the diffuse character of PMP and a history of loss of weight. Ronnett et al observed 75% and 68% of 5 and 10 years survival rate respectively for cases of diffuse peritoneal adenomucinosis, 14% and 3% for cases of peritoneal mucinous carcinomatosis²².

Conclusion :

Low incidence of PMP makes it difficult to study the disease and to evaluate the real efficiency of the various modalities of treatment. It is a disease of much morbidity and most of the patients die after 5 years of disease. Debulking surgery with hyperthermic intraperitoneal chemotherapy (HIPC) clearly improves survival rate in PMP. Ultra radical surgery could be an attractive mode of treatment.

References :

- Jacquemin G, Laloux P. Pseudomyxoma peritonei : Review on a cluster of peritoneal Mucinous Disease. *Acta chir belg.* 2005; 105:127-133.
- O'Connell JT, Tomlinson JS, Rotert AA, Mc Gonigle KF, Borsky SH. Pseudomyxoma peritonei is a disease of MUC-2 expressing goblet cells. *Am J Pathol.* 2002; 161:551-64.
- Barsky SH, Mc Gonigle K. Pseudomyxoma peritonei. *N Eng J Med.* 2004; 350:15.
- Saleem SM, Mehboob M, Qayyum A. Pseudomyxoma peritonei : A rare clinical entity. *Journal of Surgery Pakistan* 2008 ; 13 :139-140.
- O'Cannell JT, Hacker CM, Barsky SH. MUC 2 is a molecular marker for pseudomyxoma peritonei. *Mod Pathol.* 2002; 15:958-72.
- Solkar MH, Akhtar NM, Khan Z, Parker MC. Pseudomyxoma extraperitonei occurring 35 years after appendectomy: a case report and review of literature. *World J Surg oncol.* 2004; 2:19-25.
- Lanteri R, Samtangelo M, Rapisarda C, Racalbutto A, Cataldo AD, Licata A. Pseudomyxoma peritonei: a case report. *Cancer therapy* 2009; 7:31-34.
- Sugarbaker PH. Pseudomyxoma peritonei. A cancer whose biology is characterized by a redistribution phenomenon. *Am surg.* 1994; 219:109-11.
- Sugarbaker PH. Cytoreductive surgery and preoperative intraperitoneal chemotherapy as a curative approach to pseudomyxoma peritonei syndrome. *Eur J Surg oncol.* 2001; 27:239-43.
- Jaswal TS, Singh S, Agarwal R, Singh M, Khatri H L, Arora B. Pseudomyxoma Peritonei of Hernial Sac - A case report. *Indian J Pathol. Microbiol.* 2001; 44:151-152.
- Sugarbaker PM, Jablonski KA. Prognostic feature of 51 colorectal and 130 appendiceal cancer patients with peritoneal carcinomatosis treated by cytoreductive surgery and intraperitoneal chemotherapy. *Ann Surg.* 1995; 221:124-32.
- Costa MJ. Pseudomyxoma peritonei. Histologic predictors of patient survival. *Arch Pathol Lab Med.* 1994; 118:1215-9.
- Ronnet BM, Zahn CM, Kurman RJ, Kass ME, Sugarbaker PH, Shmookler BM. Disseminated peritoneal adenomucinosis and peritoneal mucinous carcinomatosis. A clinicopathologic analysis of 109 cases with emphasis on distinguishing pathologic features, site of origin, prognosis and relationship to pseudomyxoma peritonei. *Am J Surg pathol.* 1995; 19:1390-1408.
- Esquiver J, Sugarbaker PH. Clinical presentation of the pseudomyxoma peritonei syndrome *Br J Surg.* 2000; 87:1414-8.
- Elias D, Sabourin JC. Pseudomyxoma peritonei. *J chir.* 1999; 136:341-7.
- Baker WC, Goldman LB, DeVere white RW. Pseudomyxoma peritonei presenting as a scrotal mass. *J Urol.* 1998; 139:821-2.
- Walensky RP, Venbrux A, Prescott CA, Ostermam FA. Pseudomyxoma peritonei. *Am J Roentgenol.* 1996; 167:471-4.
- Van Ruth S, Hart AA, Bonfrer JM, Verwaal VJ, Zoentmulder FA. Prognostic value of baseline and serial carcinoembryonic antigen 19.9 measurements in patients with pseudomyxoma peritonei treated with cytoreduction and hyperthermic intraperitoneal chemotherapy. *Ann Surg oncol.* 2002; 9:961-7.
- Sugarbaker PH. Cytoreduction including total gastrectomy for pseudomyxoma peritonei. *Br J Surg.* 2002; 89:208-12.
- Butterworth SA, Panton ON, Klaassen DJ, Shah AM, Mc Gregor GI. Morbidity and mortality associated with intraperitoneal chemotherapy for pseudomyxoma peritonei. *Am J Surg.* 2002, 183:529-32.
- Witkamp AJ, De Bree E, Kaag MM, Van slooten GW, Van Coevorden F, Zoetmulder FA. Extensive surgical cytoreduction and intraoperative hyperthermic intraperitoneal chemotherapy in patients with pseudomyxoma peritonei. *Br J Surg.* 2001; 88:458-63.
- Ronnett BM, Yan H, Kurman RJ, Shmookler BM, WuL, Sugarbaker PH. Patients with pseudomyxoma peritonei associated with disseminated peritoneal adenomucinosis have a significantly more favourable prognosis than patients with peritoneal mucinous carcinomatosis. *Cancer* 2001; 92:85-91.