

## Case Report

### Hyperinfection with *Strongyloides stercoralis* in an Immunosuppressed Patient

H Masud<sup>1</sup>, MK Sarker<sup>2</sup>, MA Rana<sup>3</sup>, DS Ahmed<sup>4</sup>, MMSU Islam<sup>5</sup>, ASMA Raihan<sup>6</sup>

#### Abstract :

*Strongyloides stercoralis* is a common intestinal parasite in tropics and subtropics. In Bangladesh, prevalence is likely to be high due to poor sanitation. Clinical presentations are frequently nonspecific. However, in immunosuppressed individuals, infection becomes overwhelming and may disseminate and results in high rates of mortality. Unless a high index of suspicion, this readily treatable disease may be missed. Here we report a case of hyperinfection with *Strongyloides stercoralis* in a patient who was on corticosteroid treatment. A 45 years old male was admitted in Gastroenterology department of Bangabandhu Sheikh Mujib Medical University (BSMMU) with the complaints of abdominal pain, vomiting and diarrhea for 2 weeks. He was on prednisolone 60 mg with omeprazole 40 mg daily for 4 weeks for his eyelid drooping prior to the development of abdominal symptoms. Physical examination revealed a severely malnourished, moderately anemic patient with muscle wasting, angular stomatitis, desquamated skins of feet and hands. Abdominal examination revealed generalized tenderness with moderate ascites. Investigations revealed Hb-7.4 gm/dl with normal WBC count (eosinophil-11% before steroid therapy), S.albumin-19gm/l with prolonged prothrombin time and hypokalemia. USG of abdomen revealed moderate ascites. Endoscopy of upper GIT showed congestion and multiple erosions in the stomach and also in the duodenum. Biopsy from the duodenum revealed adult *Strongyloides stercoralis* on the surface, larva and ova in the duodenal crypts. The patient was treated with 10 days of oral ivermectin along with blood transfusion, correction of nutritional status and electrolyte imbalance. Patient was discharged home after a total of 20 days of hospitalization.

**Key words :** Strongyloidiasis, Immunosuppression, Hyperinfection, Ivermectin.

#### Introduction :

Strongyloidiasis is a parasitic disease caused by the *Strongyloides stercoralis*, an intestinal nematode of humans. It is estimated that ten millions of people are

1. Dr. Hasan Masud, MBBS, MD (Gastroenterology), Associate Professor, Department of Gastroenterology, Bangabandhu Sheikh Mujib Medical University, Dhaka.
2. Dr Md. Khalequzzaman Sarker, MBBS, MD Thesis Part Student, Department of Gastroenterology, Bangabandhu Sheikh Mujib Medical University, Dhaka.
3. Dr Mushtaque Ahmad Rana, MBBS, FCPS (Medicine), MD Thesis Part Student, Department of Gastroenterology, Bangabandhu Sheikh Mujib Medical University, Dhaka.
4. Dr. Dewan Saifuddin Ahmed, MBBS, FCPS (Medicine), MD (Gastroenterology), Associate Professor, Department of Gastroenterology, Bangabandhu Sheikh Mujib Medical University, Dhaka.
5. Dr. MM Shahin-Ul-Islam, MBBS, FCPS (Medicine), MD (Gastroenterology), Assistant Professor, Department of Gastroenterology, Faridpur Medical College, Faridpur.
6. Professor Dr. ASMA Raihan, MBBS, MD (Gastroenterology), Professor & Chairman, Department of Gastroenterology, Bangabandhu Sheikh Mujib Medical University, Dhaka.

#### Address of correspondence :

Dr. Hasan Masud, MBBS, MD (Gastroenterology), Associate Professor, Department of Gastroenterology, Bangabandhu Sheikh Mujib Medical University, Dhaka. Mobile:+88-01819223289, E-mail: hasangastro@yahoo.com.

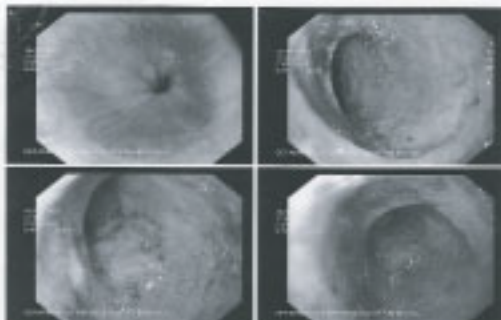
infected worldwide, although no precise estimate is available<sup>1</sup>. Endemic region for *Strongyloides* infection include the Southeastern United States, Eastern Europe, Southeastern Asia, Bangladesh, Pakistan, sub-Saharan Africa, the West Indies and South America<sup>2</sup>. The clinical symptoms and signs reported in strongyloidiasis are frequently nonspecific<sup>3</sup>. In many patients it may be totally asymptomatic and so remains undiagnosed. However, in some immunosuppressed individuals, the infection becomes overwhelming and may disseminate and results in high rates of mortality<sup>4</sup>. Here we report a case of hyperinfection with *Strongyloides stercoralis* in a patient who was immunosuppressed due to corticosteroid treatment.

#### Case report :

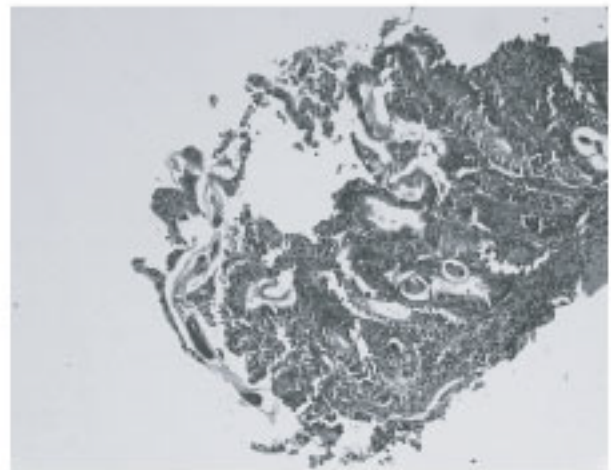
A 45 years old male, working in a lather processing factory at Hajaribag, Dhaka was admitted in our hospital with the complaints of abdominal pain, vomiting and diarrhea. According to the statement of the patient, he developed sudden drooping of the left upper eyelid one and a half month back. For this reason he consulted a neurologist and was evaluated with laboratory investigations and imaging of brain and was

prescribed prednisolone 60 mg daily with omeprazole 20 mg twice daily for 4 weeks. His eyelid drooping improved but he developed severe abdominal pain with diarrhea and vomiting. Then he consulted a gastroenterologist in a medical college hospital and was managed with intravenous fluids and antiemetics for two weeks but his condition did not improve. This time he underwent several investigations including endoscopy of upper GIT. The patient left that hospital and later was admitted in our hospital. On admission, physical examination revealed a severely malnourished patient with wasting of the muscles, angular stomatitis, desquamated skins in his feet and hands and was moderately anemic. Vital signs were as follows: blood pressure 100/50 mmHg, pulse rate 80/min, respiratory rate 20/min and body temperature 36°C. Abdominal examination revealed generalized tenderness with moderate ascites, no organomegaly, bowel sound was present.

We did some routine investigations and reviewed the investigations previously done. During the initial visit to the neurologist CBC revealed normal hemoglobin with eosinophilia (Hb- 14.7 gm/dl, WBC  $10.7 \times 10^9/l$ , neutrophil 50%, eosinophil-11%), MRI of brain was normal. During his consultation with gastroenterologist in a medical college hospital his blood report shows Hb-9.4 gm/l, WBC  $14.8 \times 10^9/l$ , neutrophil 73%, eosinophil 4%, electrolytes imbalance with hyponatremia and hypokalemia, serum albumin 27 gm/l, total protein 46 gm/l. SGPT, Alkaline phosphatase, S. creatinine, blood sugar were within normal limit. USG of whole abdomen was normal. Endoscopy of upper GIT revealed congestion with multiple erosions in the stomach and duodenum but no biopsy was taken. In our hospital, investigations revealed the followings-Hb-7.4 gm/dl with normal WBC count (eosinophil-3%), S.albumin-19gm/l with prolonged prothrombin time (Control-11.0 sec, Patient-17.6 sec) otherwise normal LFT, electrolytes imbalance in the form of hypokalemia. Anti-HIV serology was negative. USG of whole abdomen revealed moderate ascites. Endoscopy of upper GIT showed congestion and multiple erosions in the stomach and also in the duodenum (Figure-1). Biopsy was taken from the duodenum, histopathology of which revealed adult *Strongyloides stercoralis* on the surface, larva and ova within the duodenal crypts (Figure-2).



**Figure-1:** Endoscopy of upper GIT showing mucosal congestion and erosions in the antrum of the stomach.



**Figure-2:** Histopathology of duodenal mucosa showing larva and ova within the duodenal crypts and adult worm on the surface.

The patient was treated with ivermectin orally along with blood transfusion and intravenous albumin. Nutritional status was corrected with high protein diet and intravenous supplementation of available vitamins. Hypokalaemia was corrected with intravenous potassium. After 10 days of oral ivermectin, antiparasitic therapy was discontinued. Patient general conditions showed significant improvement. Skin condition returned to normal and there was no ascites. Patient was discharged home after a total of 20 days of hospitalization.

#### Discussion :

*Strongyloides stercoralis* is a common parasite of the intestinal tract, especially in tropical and subtropical areas<sup>3,6</sup>. In Bangladesh due to poor sanitation facilities its prevalence is likely to be high. To our knowledge few cases of duodenitis due to *strongyloides stercoralis* infection have been reported in our country<sup>7,8</sup>.

*S. stercoralis* is unique by its ability to replicate in the human host with a lifecycle encompassing both free-living and parasitic stages. Adult females, embedded in the intestinal mucosa, lay eggs that hatch internally. Rhabditiform larvae are excreted in the feces and develop into filariform larvae in the soil. Humans are infected transcutaneously when the filariform larvae penetrate intact human skin (usually the feet when people walk barefoot), travel through the bloodstream to the lungs, migrate up the respiratory tract, are swallowed and thus reach the small intestine. There, the larvae mature into adults that penetrate the mucosa of the small bowel. The adult female worms reproduce by parthenogenesis, as adult males do not exist. Eggs hatch and rhabditiform larvae pass with the feces into

the soil. Rhabditiform larvae can develop directly into filariform larvae without leaving the host. This maturation results in autoinfection and continuation of parasitism<sup>9-12</sup>. Autoinfection can result in continual infection for years up to 64 years in 1 report<sup>13</sup>.

The clinical syndromes of strongyloidiasis comprise a wide spectrum ranging from asymptomatic, acute or chronic infection to hyperinfection or dissemination. Strongyloidiasis is often asymptomatic in otherwise healthy hosts. Acute strongyloidiasis is defined by symptoms from local reactions at the site of larva entry which occur almost immediately and may last up to several weeks. Chronic strongyloidiasis is mainly asymptomatic with occasional mild symptoms manifesting in the pulmonary and gastrointestinal systems. During the asymptomatic stage, eosinophilia is the only clinical indicator<sup>14</sup>. Our patient was probably was in chronic stage as he had occasional dyspepsia, periumbilical pain and loose stool and the blood picture showed 11% eosinophil in the initial investigation done prior to corticosteroid therapy.

The term "hyperinfection" or "overwhelming infection" is defined by signs and symptoms attributable to large amounts of larvae migration. The hallmark of hyperinfection is development or exacerbation of gastrointestinal and pulmonary symptoms and increase numbers of larvae in stool and/or sputum. Larvae in hyperinfection are confined to the organs involved in the pulmonary auto-infective cycle such as lung, gastrointestinal tract and peritoneum<sup>14</sup>. Gastrointestinal symptoms include abdominal bloating, abdominal cramps, diarrhea, vomiting, and weight loss. Hematochezia or melena is caused by extensive intestinal ulceration found in heavy infection. The intestinal manifestations can mimic an acute surgical abdomen such as small bowel obstruction, paralytic ileus or perforating peptic ulcers<sup>14</sup>. In our case, the patient presented with intractable emesis, abdominal pain and diarrhea with significant weight loss, features of malnutrition with ascites as a consequence of hypoalbuminaemia. Hematochezia was not reported by the patient but the rapid fall in hemoglobin status may signify occult GIT bleeding. Our patient did not have any pulmonary symptoms.

Disseminated infection is the migration of larvae to organs beyond the range of the autoinfective cycle (lungs and gastrointestinal tract) and is often complicated by Gram-negative sepsis. Such organs include the skin, liver, central nervous system as well as virtually every other organ<sup>15</sup>. Immunosuppression is the greatest threat for hyperinfection and dissemination. In our case, the patient received corticosteroid for one month in high dose which may be the cause of hyperinfection in the background of chronic asymptomatic carrier stage.

The laboratory diagnosis of strongyloides is usually made by the finding of rhabditiform larvae in the fecal specimens, however, a routine stool examination may fail to find larvae, when the intestinal worm burden is very low and the output of larvae is minimal. It also needs to be remembered that worm may not be found in a routine examination of a small quantity of feces. To improve chances of finding parasites, repeated examinations of stool specimens should be done<sup>3</sup>. In our case, we could not find any larvae in the routine stool examination. Repeat examination was not done which should have been done. However, it is important to understand that not identifying larvae in the stool does not imply an absence of infection. Upper and lower endoscopy can also establish the diagnosis of strongyloidiasis, as larvae may be seen on biopsies of the affected mucosa<sup>4</sup>. The larvae can be identified in bronchoalveolar lavage fluid and bronchial washings and brushings<sup>3</sup>. In our case endoscopic biopsy was necessary to find the evidence of strongyloidiasis.

Deciding to biopsy the duodenum based on the congested and eroded appearance of the mucosa was the key step in making the correct diagnosis which was not done during the initial endoscopy. In the literature, endoscopic findings of the duodenum in strongyloidiasis include normal mucosa, edema, erythema, erosion, swollen folds, granule, ulcer, polyp, hemorrhage, megaduodenum, deformity and stenosis<sup>15</sup>. As there is no pathognomonic finding in the stomach and duodenum, it is important to maintain a high index of suspicion and to take a biopsy from relatively normal appearing bowel on endoscopy, especially in immunocompromised patients<sup>3</sup>.

Many immunodiagnostic assays have been used over the years, including indirect immunofluorescence analysis of fixed larvae and gelatin particle agglutination. It is believed and shown in population-based studies that stool examination generally underestimates the prevalence of *S. stercoralis* infection, whereas serological studies overestimate it<sup>4,6</sup>. In our case no serological test was done.

While prompt diagnosis is important, clinicians must have a high suspicion of *S. stercoralis* infection when clinical signs and symptoms are present, as strongyloidiasis is difficult to diagnose and delaying therapy can have fatal consequences. In uncomplicated strongyloidiasis, thiabendazole 25 mg/kg twice a day for 3 days (2 days in the United States) was first-line therapy for many years but this protocol produced undesirable side effects, especially nausea and dizziness and had a high relapse rate<sup>16,2</sup>. Ivermectin 200 µg/kg once a day for 2 days is better tolerated and has a higher cure rate than thiabendazole<sup>2</sup>. Ivermectin is the drug of choice in the World Health Organization's

list of necessary drugs for the treatment of *S. stercoralis*<sup>6</sup>. In disseminated disease, hyperinfection syndrome and the immunocompromised patients, ivermectin is given daily until symptoms cease and stool samples are negative for *S. stercoralis* larvae for at least 2 weeks (1 autoinfection cycle). There is no generally agreed-upon regimen, as data are limited. Some experts recommend combining ivermectin with albendazole but evidence is limited<sup>2</sup>. In our patient ivermectin was continued for 10 days.

### Conclusion :

Immunocompromised conditions have been associated with hyperinfection and disseminated infection with strongyloidiasis. Physicians should be aware of these unusual manifestations of strongyloidiasis. Through this case report, we intend to emphasize the importance of doing endoscopy and endoscopic biopsy when investigating the etiology of gastrointestinal symptoms in immunocompromised patients. Unless a high index of suspicion is maintained, strongyloidiasis, a readily treatable disease, may be missed.

### References :

- Grove DI. Historical introduction. In: Grove DI (editor), *Strongyloidiasis: a major roundworm infection of man*. Philadelphia: Taylor & Francis; 1989. p. 1-9.
- Segarra-Newnham M. Manifestations, diagnosis and treatment of *Strongyloides stercoralis* infection. *Annals of Pharmacotherapy* 2007; 41(12):1992-2001.
- Kim J, Joo H, Kim D, Lim H, Kang Y, Kim M. A case of gastric strongyloidiasis in a Korean patient. *Korean J. Parasitol.*2003; 41(1):63-67.
- Kakati B, Dang S, Heif M, Caradine K, McKnight W, Aduli F. *Strongyloides Duodenitis: Case report and review of literature*. J National Med Assoc. 2011; 103(1):60-62.
- Genta RM. Global prevalence of Strongyloidiasis: critical review with epidemiologic insights into the prevention of disseminated disease. *Rev Infect Dis.* 1989; 11:755-67.
- Siddiqui AA, Berk SL. Diagnosis of *Strongyloides stercoralis* infection. *Clin Infect Dis.* 2001; 33:1040-47.
- Raihan ASMA, Miah RMA, Majumder TK, Rahman MM, Hasan M. Severe strongyloidiasis-a case report. *Bangladesh J Medicine* 2005;16:93-5.
- Khaled A, Ara N, Choudhry LL, Nasir TA. Strongyloidiasis in gastrointestinal biopsy. *Pulse* 2009; 3(1):27-8.
- Maguire JH. Intestinal nematodes (roundworms). In: Mandell GL, Bennett JE, Dolin R, editors. *Mandell, Douglas, and Bennett's Principles and Practice of Infectious Diseases*. 7th ed. Philadelphia: Elsevier Churchill Livingstone; 2010.p.3577-86.
- Concha R, Harrington W, Rogers AI. Intestinal strongyloidiasis: recognition, management, and determinants of outcomes. *J Clin Gastroenterol.* 2005;39:203-11.
- Lim S, Katz K, Krajden S, Fuksa M, Keystone JS, Kain KC. Complicated and fatal *Strongyloides* infection in Canadians: risk factors, diagnosis and management. *CMAJ.* 2004;171:479-84.
- Keiser PB, Nutman TB. *Strongyloides stercoralis* in the immunocompromised population. *Clin Microbiol Rev.*2004;17:208-17.
- Hauber HP, Galle J, Chiodini PL. Fatal outcome of a hyperinfection syndrome despite successful eradication of *Strongyloides* with subcutaneous ivermectin. *Infection.* 2005;33:383-86.
- Amornvipas P, Nattee P, Chongsrisawat V, Pongpunlert W, Wisedopas PY. Overwhelming strongyloidiasis. *Asian Biomedicine* 2009;3(5):531-36.
- Kishimoto K, Hokama A, Hirata T, Ihama Y, Nakamoto M, Kinjo N, et al. Endoscopic and histopathological study on the duodenum of *Strongyloides stercoralis* hyperinfection. *World J Gastroenterol.* 2008;21(11):1768-73.
- Genta RM. Global prevalence of strongyloidiasis: critical review with epidemiologic insights into the prevention of disseminated disease. *Rev Infect Dis.* 1989;11:755-67.