

## Original Article

# Evaluation of Results of Fixation of Unstable Distal Radial Fractures by Volar Locking Plating System

MM Uddin<sup>1</sup>, AR Mondal<sup>2</sup>, NC Karmakar<sup>3</sup>, MM Rahman<sup>4</sup>, SAU Alam<sup>5</sup>

### Abstract:

Distal radial fractures are most common fractures accounts 15% of whole skeletal injuries, as high as 40% to 49% are considered to be unstable that requires surgical fixation. The purpose of the study was to ascertain good functional hand by using volar locking plate & screws, as with locking system, distal screws are locked to the plate, which stabilized the screws against lateral movement (toggle effect), thus providing a "single bone-plate-screws construct" which producing a scaffold in the mostly cancellous distal radial metaphysis, so preventing from collapse. This study was done from January 2007 to December 2008 at National Institute of Traumatology & Orthopaedic Rehabilitation (NITOR). Total numbers of cases were 17. All patients were admitted in hospital & most of them returned home within 4 days. Most patients were managed early within 1-10 days of injury. Most patients were Fernandez type 1, type 2, and type 3. Most patients were in the age group of 4<sup>th</sup> decade. All patients were followed up for a period of at least 3 months, mean follow up period was 6 months. Results showed that wrist pain, wrist stiffness, reduced grip strength were minimum with volar locking plate & screws as there is minimal radial shortening, radial angulation, volar tilt & ulnar variance and wrist flexion, wrist extension, ulnar deviation, supination, pronation were very good. So, the trauma surgeons can safely use this procedure.

**Key words:** Fixation, Volar Locking Plating System.

### Introduction:

Most elegant tool of human being is "The Hand". Without proper treatment of unstable distal radial fracture, may compromise hand function<sup>1</sup>. For unstable distal radial fracture needs skeletal fixation<sup>2</sup>. Five factors of Instability are (a) Initial dorsal angulation greater than 20<sup>0</sup> (b) Dorsal metaphyseal comminution (c) Intra-articular disruption (d) Associated ulnar fracture (e) Patient over 60 years of age with massive osteoporosis<sup>3</sup>.

1. Dr. Md. Maiyeen Uddin, MBBS, MS (Ortho), D-Ortho, Senior Consultant (Orthopaedic surgery), General Hospital, Faridpur.
2. Dr. Anadi Ranjan Mondal, MBBS, MS (Orth), Asst Prof., Dept. of Orthopaedics, Faridpur Medical College, Faridpur.
3. Dr. Narayan Chandra Karmakar, MBBS, MS (Ortho), Assistant Professor, Department of Orthopaedic surgery, Tangail Medical College, Tangail.
4. Dr. Md. Masudur Rahman, MBBS, MS (Ortho), Junior Consultant (Ortho Surgery), Faridpur Medical College Hospital, Faridpur.
5. Dr. Syed Asif Ul Alam, MBBS, D Ortho. MS (Ortho), Junior Consultant, General Hospital, Faridpur.

### Address of correspondence :

Dr. Md. Maiyeen Uddin, MBBS, MS (Ortho), D-Ortho, Senior Consultant (Orthopaedic surgery), General Hospital, Faridpur.  
Mobile: +88-01756707707, E-mail: mahzuza.s@gmail.com

Indications for skeletal fixations are: (a) Apex volar angulation >10<sup>0</sup> (b) Radial Inclination >15<sup>0</sup> (c) Radial height <10mm (d) Intra-articular step of >2mm. (e) Immobilization of the limb with pin & plaster<sup>2</sup>. Several methods of skeletal fixation of unstable distal radial fractures are: (a) Close reduction & percutaneous pinning, (b) Immobilization of the limb with pin & plaster, (c) External fixation, (d) Intramedullary nailing, (e) Volar fixed angle plating, (f) Combination of internal, percutaneous pinning & plaster casting, (g) Volar locking plating<sup>4-14</sup>.

The best treatment of unstable distal radial fractures is not well established. So the treatment of unstable distal radial fractures continues to improve as better method of fixation & soft tissue management are more to be developed<sup>3</sup>. Late problems associated with distal radial fractures are: (a) Articular incongruity leading to early osteoarthritis, (b) Pain syndromes secondary to small degrees of radial malalignment both in sagittal and coronal plane, (c) midcarpal instability, (d) instabilities of distal radio-ulnar joint, (e) loss of radial height<sup>15-19</sup>.

Volar buttress plating & dorsal plating without locked screws, can't prevent lateral movement (toggle effect),

screw purchase in distal radius is poor due to limited stock of cortical bone. But in locking plating, distal screws are locked to the plate, which stabilizes the screws against lateral movement (toggle effect). This provides augmentation to the strength of fixation by producing "Single bone-plate-screws construct" which producing a scaffold in the mostly cancellous distal radial metaphysis & also under distal radial articular surface<sup>3</sup>.

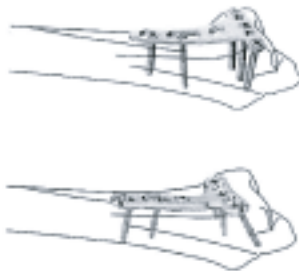


Fig-1: Volar Locking Plate fixed on distal radius (www.synthes.com)



Fig-2: Locking plate and screws for distal radius.




Fig-3: Low-contact dynamic compression locking plate. Each hole has option of either dynamic compression or locking plate function. Threaded hole section for locking screw (A). Dynamic compression section for standard screws (B). Locking screw in place (C). Cortical screw in compression section of hole (D). (Synthes, Paoli, Pa, Campbell's Operative Surgery 11<sup>th</sup> Edn).

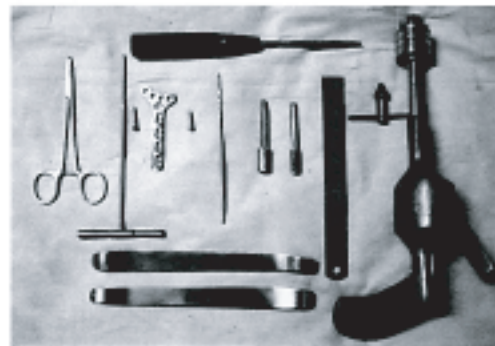


Fig-4: Instruments for fixation of distal radius by Volar Locking Plate and Screws.

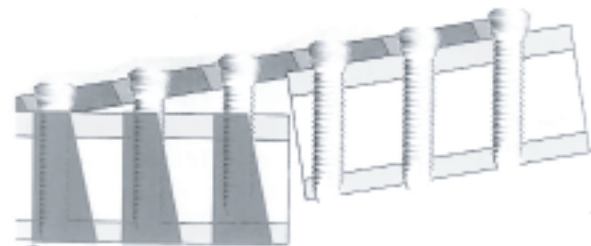


Fig-5: Higher resistance against bending loads and higher pull-out strength. (www.zimmer.com)

#### Materials & Methods:

This prospective observational study was carried out at National Institute of Traumatology & Rehabilitation (NITOR), Dhaka, Bangladesh, during the period of Jan 2007 to Dec 2008. Objectives of the study was to find out a satisfactory method of treatment of unstable distal radial fractures regarding any postoperative complications during management procedures & in follow up period by carrying out clinical and radiological evaluation, functional outcome results and to propose a protocol for such cases.

Among the 17 patients, finally 15 patients with unstable distal radial fractures were taken for study for follow-up for a period of at least 3 months. Follow up given on clinical and radiological basis from 6 weeks to 9 months. Mean follow up period was 6 months. Study was based on Fernandez classification of distal radial fractures.

#### Operative technique:

An 8 cm incision is made on the radial border of Flexor Carpi Radialis (FCR) tendon. The V-shape of the distal part of the incision provides better access to the articular surface. The incision is carried out through the FCR tendon sheath. The forearm fascia on the radial border of FCR is incised. The forearm fascial incision was made along radial border of FCR tendon to secure palmar cutaneous branch of median nerve. The attachment of flexor pollicis longus (FPL) to radius is

incised & partially detached for full view of pronator quadrates (PQ). An L-shaped incision was made over the radial border of PQ to prevent full elevation of PQ from radius. After full exposure of the fracture site, fracture was reduced. For ease of reduction an osteotome was inserted into the fracture, over the distal cortex, to completely disimpact distal radial fragment. The specially designed plate simulating distal radial end contour was placed on volar aspect of distal radius. A screw was placed in central distal hole & then the remaining screws are placed. When the distal fracture fragment was being reduced into anatomic position, it was important for an assistant to apply traction continually to the fingers to maintain radial height. If compression was needed, instead of locking screw a cortical screw were used in non-threaded part of combihole. Finally a 3.5 mm was placed in each of the proximal holes. The wound was then closed keeping a drain in situ. A short arm back slab was given.

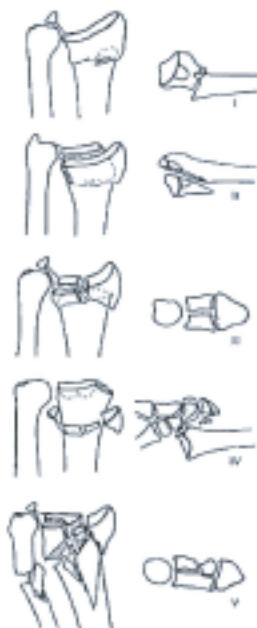

Fig-6: Fernandez classification of fractures of distal radius classified by mechanism of injury. I. Bending, II. Shear, III. Impaction, IV. Avulsions with fracture-dislocation, V. High velocity. (Campbell's operative Orthopedics 11<sup>th</sup> Edn, Vol-3, p-3442)

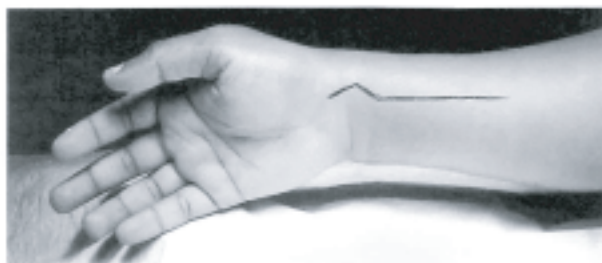

Fig-7 : Incision for Volar locking plate fixation along FCR (Chung and Petruska, JBJS, 2007, vol. 89-A, p. 258).

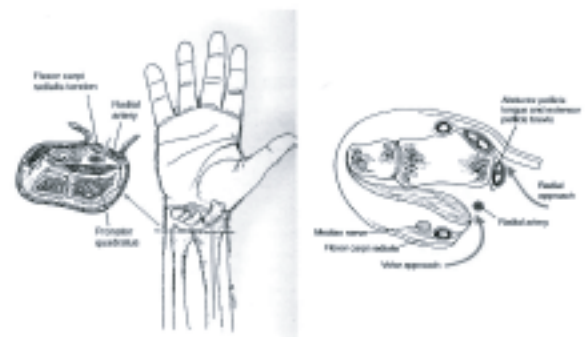


Fig- 8: Volar approach to distal radius (Campbell's Operative Surgery 11<sup>th</sup> Edn).

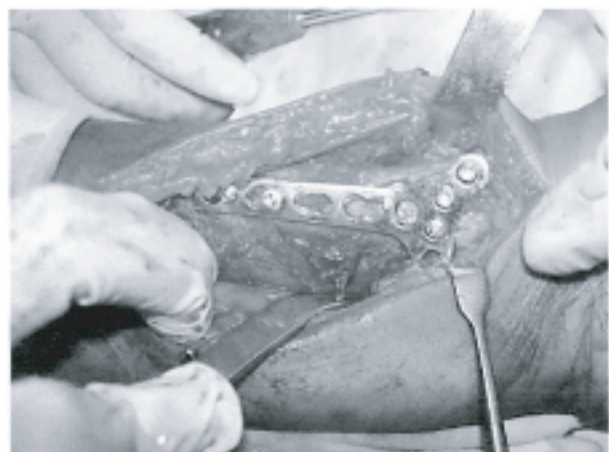


Fig- 9: Volar Locking Plate fixed on distal radius.

**Results:**

This prospective study of treatment of unstable distal radial fractures by volar locking plate & screws was carried out on 15 patients to find out the common causes of fracture, age and sex incidence and to propose a protocol for treating such cases.

**Anatomic results:** Evaluated by radiological means in AP & lateral views of the involved wrist joint & then compared with that of normal side. Anatomical results of 3 patients were excellent. Good anatomical results were in 9 cases. Unsatisfactory (fair & poor) results were in 3 cases.

Table I: Overall assessment of anatomical outcome

Result	No of Patients (%)
Satisfactory (Excellent and good)	12 (80)
Unsatisfactory (Fair and poor)	3 (20)
<b>Total</b>	<b>15</b>

**Functional results:** Functional results based on grip strength, pinch strength, clinical outcomes were-wrist flexion, wrist extension, ulnar deviation, supination, and pronation. Excellent functional results were in 3 cases, 9 cases good, 2 fair & 1 poor.

**Table II:** Overall assessment of the functional outcome

Result	No of Patients (%)
Satisfactory (Excellent and good)	12 (80)
Unsatisfactory (Fair and poor)	3 (20)
<b>Total</b>	<b>15 (100)</b>

#### Discussion:

The best treatment of unstable distal radial fracture is not yet well established<sup>3</sup>. Conservative management often includes the acceptance of some degree of displacement of fragments and emphasis is concentrated on hand function. The choice of treatment is frequently determined by surgeon's opinion on the correlation between anatomical and functional end results<sup>20</sup>. Initial radial shortening is the best predictor of future instability, so that more importance is given on prevention of radial shortening than on reduction of dorsal angulation & radial deviation<sup>21,22</sup>. It is not very difficult to achieve radial height by closed manipulation to the original value but is fairly difficult to maintain it before fracture healing is complete especially if such fractures are protected by only cast immobilization. It may need cancellous bone grafting and fixation<sup>23</sup>.

The locking screws in the volar locking plating system offer additional advantage over previous implants<sup>3</sup>. With previous volar plate designs involving non-locking screws, screw purchase in the metaphysis of distal part of radius often poor because of limited amount of cortical bone in this location<sup>24,25</sup>. With the new design, the distal screws are locked to the plate, which stabilizes the screws against lateral movement (toggle) and resists loosening. This provides additional strength to the fixation by constructing a scaffold under the distal radial articular surface and producing "single bone-plate-screws construct"<sup>3</sup>.

A number of complications were observed in this study. One case was reduced and fixed well but after 4 weeks showed features of late collapse. Wrist stiffness was minimum. Reduced grip and pinch strength improved with physiotherapy except in one case. No step of 2 mm was seen at the end of the study in most of the cases.

Tendon inflammation due to larger screws in two patients were seen which gradually regressed. Two cases needed per operative bone grafting for metaphyseal collapse<sup>21</sup>. Plate related complications did not occur in this series. Pronator quadratus provided muscular coverage to the plate and shielded the flexor tendons from the plating system. Hard labourer, office worker, dominant handed people if treated with Volar Locking Plate and Screws at the expense of cost of implant and cost of operation, should have an excellent functional hand.

#### Conclusion:

Open reduction and internal fixation of distal radial fractures with Volar Locking Plate and Screws can result good to excellent outcomes in most of the cases with a limited number of complications. This series was conducted only in 15 cases and mean follow-up period was 6 months. So further prospective study with larger sample and longer duration of follow up is recommended.

#### References :

1. Fernandez DL, Palmar AK. Fractures of the distal radius. In: Green DP, Hotchkiss RN, Pederson WC, editors. Green's operative Hand Surgery. New York: Churchill-Livingstone; 1999. p.929-80.
2. Abbaszadegan H, Jonson V. Prediction of instability of Colles' fracture. Acta Orthop Scand. 1989; 60:646-50.
3. Chung KC, Petruska EA. Treatment of unstable distal radial fractures with volar locking plating system. JBJS 2007; 89:256-66.
4. Clancey GJ. Percutaneous kirschner wire fixation of Colles' fracture. JBJS 1984; 66:1008-14.
5. Cooney WP, Dobyn JH, Linsched RL. External pin fixation for unstable Colles' fracture. JBJS 1979; 61:840-50.
6. Cooney WP, Dobyn JH, Linsched RL. External pin fixation for unstable Colles' fracture. JBJS 1979; 35:641-58.
7. Kaukonen JP, Karaharizu E, Luthie P, Porras M. Ext-fixation in Colles' fracture. Acta Orthop Scand. 1989; 60:54-56.
8. Chong C, Elizabeth T. Management of severely comminuted fractures. JBJS 2007; 70:210-26.
9. Ballmer MF. The small AO external fixator for fractures of distal radius and other application. AO/ASIF 1966; 125:63.
10. Smith DW, Henry MH. Volar fixed angle plating of the distal radius. J Am Acad Orthop Surg. 2005; 13:28-36.
11. Sarmiento A, Zagorski JB, Sinclair WF. Colles' fracture: Functional bracing in supination. JBJS 1975; 57:311-5.
12. Sarmiento A, Zagorski JB, Sinclair WF. Functional bracing of Colles' fracture: a prospective study of immobilization in supination and pronation. Clin orthop. 1980; 50:581-696.
13. Clyburn TA. Dynamic external fixation for comminuted intra-articular fractures of distal end of radius. JBJS 1987; 69:248.

14. Bacorn, Kurtzke JF. Colles' fracture: a study of two thousand cases from New York state workmen compensation Board JBJS 1953; 60:646-58.
15. Cooney WP, Dobyn JH, Linsched RL. Complications of Colles' fractures. JBJS 1953; 35:643-58.
16. Frykman G. Fracture of distal radius including sequeale: a clinical and experimental study. Acta Orthop Scand. 1967; 108:1-55.
17. Gartland JJ, Werly C. Co evaluation of healed Colles' fracture. JBJS(LAM) 1951; 33:895-907.
18. Orbay JL, Fernandez DL. Volar fixation for dorsally displaced fracture of distal radius: a preliminary report. J Hand Surgery America 2002; 27:205-15.
19. Hulten O. Uber anatomische Variationen der Hand-Gelenkknochen. Acta Radiol. 1928; 9:155-69.
20. Palmer AK, Werner FW. Biomechanics of distal radio ulnar joint. Clin Orthop. 1984; 187:26-34.
21. Orbay JL, Fernandez DL. Volar fixed angle plating for unstable distal radial fractures in the elderly. J Hand Surgery America 2004; 29:96-102.
22. Leung F, Tu Y, Chew YC, Chow S. Comparison of external and percutaneous pin fixation with plate fixation for intra-articular distal radial fractures. JBJS 2008; 90:16-22.
23. Cannegieter DM, Juttman JW. Cancellous grafting and external fixation for unstable Colles' fracture. JBJS 1997; 79:428-32.
24. Bartosh RA, Saldana MJ. Intraarticular fractures of the distal radius: a cadaveric study to determine if ligamentotaxis restores radiopalmar tilt. J Hand Surg (Am) 1990; 15:18-21.
25. Jupiter JB, Huber MM. Operative management of distal radial fractures with 2.4mm locking plate. JBJS 2009; 91:55-65.