

Case Report

OHVIRA Syndrome: A Case Report

D Zeba¹, F Zesmin², R Roy³

Abstract:

OHVIRA syndrome or Herlyn-Werner-Wunderlich syndrome is a rare congenital anomaly of female urogenital tract which is represented by the triad of uterine didelphys, obstructed hemivagina and ipsilateral renal agenesis. This rare variant of Müllerian duct anomalies represent failure of vertical and the lateral fusion of Müllerian ducts around 9 weeks of gestation. OHVIRA syndrome comprises about 2-3% of Müllerian abnormalities.

A 13 years old girl got admission in FMCH on 15.3.2018 with lower abdominal pain and acute retention of urine. Her menarche was established 6 months back with regular cycle and associated with dysmenorrhoea. Imaging studies revealed uterine didelphys, highly dilated cervix with hematocolpos and absence of right kidney. The vaginal septum was excised. The patient recovered fully and was under follow up for 6 months. There was no evidence of further outflow tract obstruction.

Key words: Hemivagina, OHVIRA syndrome, Renal agenesis.

Introduction:

A triad of uterine didelphys, obstructed hemivagina and ipsilateral renal agenesis, known as OHVIRA syndrome is a rare congenital anomaly^{1,2}. The incidence is reported about 2-3% of Müllerian abnormalities³. Herlyn-Werner-Wunderlich syndrome (HWW) is due to defect in vertical and lateral fusion of paramesonephric duct resulting uterine didelphys and obstructed hemivagina^{4,5}. The vagina and genital system arises from a common ridge of mesoderm along the dorsal body wall⁶. Therefore, paramesonephric duct abnormalities are often associated with mesonephric duct abnormalities (43%)⁷. Ipsilateral renal agenesis is the most common association⁸. It is usually diagnosed in puberty as lower abdominal pain due to menstrual outflow tract obstruction. Due to its rarity and regular menstruation by other half of uterus with patent outflow tract, there is often a delay in diagnosis⁹.

It increases the risk of complications like endometriosis and infertility¹⁰. Here, we describe the case of a 13 years old girl diagnosed as OHVIRA syndrome admitted with lower abdominal pain and acute retention of urine.

Case report:

A 13 years old unmarried girl admitted in Gynae and obs department of Faridpur Medical College Hospital on 15th March 2018 with acute retention of urine and lower abdominal pain. Pain was not related to fever, vomiting, dysuria or loin pain. The day before admission, she experienced same type of complaints and was admitted in a local hospital where she was treated by catheterization. For the second time development of urinary retention, she was referred to this higher centre. She had no history of any urinary complaints before this incidence. Her menstruation was established 6 months back with regular cycle, scanty flow and associated with dysmenorrhea.

On admission, the patient was hemodynamically stable and afebrile. After immediate catheterization, a tender mass (about 8×6 cm) was palpable in lower abdomen with restricted mobility and get below of the swelling was not possible. Transabdominal ultrasonography revealed a (8×8) cm cystic lesion with internal echoes suggestive of endometriosis. As she was a regularly menstruating girl, it was unusual to think about hematometra due to outflow tract obstruction. On the other hand, such a large chocolate cyst is not common in a girl with a history of menarche 6 months back.

1. Dr. Dilruba Zeba, MBBS, DGO, MCPS, FCPS (Gynae & Obst), Associate Professor, Department of Gynae and Obst, Faridpur Medical College, Faridpur.

2. Dr. Fahmida Zesmin, MBBS, FCPS (Gynae & Obst), Assistant Professor, Department of Gynae and Obst, Faridpur Medical College, Faridpur.

3. Dr. Rajib Roy, MBBS, DGO, Registrar, Department of Gynae and Obst, Faridpur Medical College Hospital, Faridpur.

Address of correspondence :

Dr. Dilruba Zeba, MBBS, DGO, MCPS, FCPS (Gynae & Obst), Associate Professor, Department of Gynae and Obst, Faridpur Medical College, Faridpur, Bangladesh. Mobile: +8801712090825, E-mail: dilruba_zeba@yahoo.com

Laboratory test result including complete blood count, S creatinine and urinalysis was normal. A second transabdominal ultrasonography of the whole abdomen showed bicornuate uterus with hugely dilated cervix with hematocolpos having internal echoes. Right kidney was absent and left kidney was normal. Our clinical diagnosis was uterine didelphys where left half is functioning well with patent outflow tract, for which reason the patient is regularly menstruating. But in right half there is obstruction in some level producing hematocolpos.

After proper counseling with patient's family a pervaginal examination was done under anesthesia, which revealed a mass in right side of lower abdomen bulging through vagina. Cervix could not be identified. A cruciate incision was made over vaginal wall. Huge amount (about 1.5 litre) of inspissated blood was escaped out. After that, a part of vaginal wall was excised. A Folley's catheter was introduced through cervix to keep patency of the outflow tract. In surgical exploration, a patent vaginal cavity and cervix was felt in left side.

Patient was discharged on third postoperative day with antibiotics and intrauterine catheter. She came for follow up after 14 days when catheter was removed. The patient came for follow up after 3 months and 6 months. Her menstruation was regular with normal flow and duration.

Discussion:

During embryogenesis, the Müllerian (Paramesonephric) duct differentiates into fallopian tubes, uterus, cervix and the upper part of the vagina. Non development or defects of the Müllerian ducts consist of a) agenesis or hypoplasia, b) defect of the vertical fusion; or c) defect of the lateral fusion⁴⁻⁶. OHVIRA syndrome is a combination of 2nd and 3rd group. Approximately 75% of patient with didelphys uterus have a complete or partial vaginal septum¹¹. But in OHVIRA or HWW syndrome, there is lateral fusion between the inferior portion of the two Müllerian ducts that ultimately causes hematocolpos and gradual accumulation of inspissated blood in the cervix and the uterus.

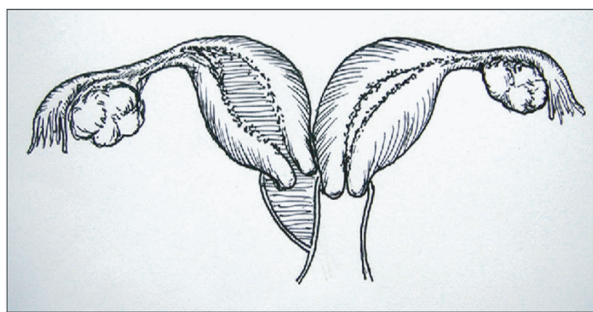


Figure 1: A diagram of OHVIRA syndrome. Here, obstruction in the right half of the vagina in a didelphys uterus producing hematocolpos and hematometra.

An early failure of the metanephric diverticulum to develop from the mesonephric duct results in agenesis of ureteric bud, leading to ipsilateral agenesis of the ureter and kidney.

HWW is commonly diagnosed at the time of menarche. The most common presentation is pelvic pain (90%), abdominal mass (40%) and pressure symptoms like urinary retention¹². Due to the lack of awareness and rarity of OHVIRA syndrome, usually there is a delay in diagnosis. Ultrasonography is helpful but MRI is conclusive for diagnosis. Laparoscopy may be done to describe the uterine anomaly clearly. In neglected cases, hematocolpos may produce hematometra and hematosalpinges. So, endometriosis is a frequent association. Early recognition is important to avoid complications like retrograde tubal reflux producing endometriosis as well as subfertility. One case has been reported where patient presented at a later age with foul smelling vaginal discharge due to pyocolpos¹². Surgical procedure like excision of the vaginal septum is enough to make a pathway to escape the accumulated blood. But after excision of the vaginal septum, precaution must be taken to keep the outflow tract patent¹³.

During the last 8 years in our hospital, 5 cases of OHVIRA syndrome were notified. Among them, 3 cases were successfully operated by excision of vaginal septum. In one case, the clinical diagnosis was endometriosis with large chocolate cyst. After laparotomy, we found double uterus with large hematometra in one side. Then, an incision was given in lower part of the uterus and inspissated blood was sucked out. By the guidance of finger, a passage was made vaginally. In another case, septal resection was not possible and unilateral hysterectomy was required.

Conclusion:

OHVIRA is a rare syndrome of Müllerian and Wolffian duct abnormalities. Due to its rarity and lack of awareness, it is often misdiagnosed or diagnosis is delayed. A regular menstrual history is always makes a confusion in diagnosis of outflow tract obstruction. A simple excision of vaginal septum is enough to relieve the symptoms and fertility preservation.

References :

1. Beer WM, Carstairs SD. Herlyn Werner Wunderlich syndrome: an unusual presentation of acute vaginal pain. *J Emerg Med.* 2013;45:541-3.
2. Gholoum S, Puligandla PS, Hui T, Su W, Quiros E, Laberge JM. Management and outcome of patients with combined vaginal septum, bifid uterus, and ipsilateral renal agenesis (Herlyn-Werner-Wunderlich syndrome). *J Pediatr Surg.* 2006; 41:987-92.
3. Resetkova N, Christianson M, Kolp L. Uterinedidelphys With Obstructed Hemivagina and Ipsilateral Renal Agenesis Presenting With Hydronephrosis. *Fertil Steril.* 2012;97(3):s30-S1.

4. Capito C, Echaieb A, Lortat-Jacob S, Thibaud E, Sarnacki S, Nihoul-Fé'ké'te' C. Pitfalls in the diagnosis and management of obstructive uterovaginal duplication: A series of 32 cases. *Pediatrics* 2008;122:e891e7.
5. Herlyn U, Werner H. Simultaneous occurrence of an open Gartner-duct cyst, a homolateral aplasia of the kidney and a double uterus as a typical syndrome of abnormalities. *Geburtshilfe Frauenheilkd*1971;31:340e7 [In German].
6. Wunderlich M. Unusual form of genital malformation with aplasia of the right kidney. *Zentralbl Gynakol* 1976;98:559e62 [In German].
7. Troiano RN. Magnetic resonance imaging of mullerian duct anomalies of the uterus. *Top Magn Reson Imaging*. 2003;14:269-79.
8. Mandava A, Prabhakar RR, Smitha S. OHVIRA syndrome (obstructed hemivagina and ipsilateral renal anomaly) with uterus didelphys, an unusual presentation. *J Pediatr Adolesc Gynecol*. 2012; 25:e23-5.
9. Epelman M, Dinan D, Gee MS, Servaes S, Lee EY, Darge K. Müllerian duct and related anomalies in children and adolescents. *Magn Reson Imaging Clin N Am*. 2013; 21(4):773-89.
10. Anghong W, Visetsripong M, Amornvithayachan O, Varavithya V. Herlyn- Werner - Wunderlich syndrome emphasizes ultrasonographic and MR findings: a case report and review of the literatures. *J Med Assoc Thai*. 2012; 95(Suppl 12):S129-33.
11. Wang J, Zhu L, Lang J, Liu Z, Sun D, Leng J, et al. Clinical characteristics and treatment of Herlyn-Werner-Wunderlich syndrome. *Arch Gynecol Obstet*. 2014;290(5):947-50.
12. Christianson MS, Yates MM, Woo I, Khafagy A, Garcia JE, Young RH. Obstructed hemivagina and ipsilateral renal anomaly (OHVIRA): diagnostic features and management of a frequently misdiagnosed syndrome. *Fertil Steril* 2012;98:222.
13. Cetinkya SE, Kahraman K, Sonmezer M, Atabekoglu C. Hysteroscopic management of vaginal septum in a virginal patient with uterus didelphys and obstructed hemivagina. *Fertil Steril* 2011;96:16-8.

Image Source:

- Zhu L, Chen N, Tong JL, Wang W, Zhang L, Lang JH. New classification of herlyn-werner-wunderlich syndrome. *Chinese medical journal*. 2015 Jan 20;128(2):222.