

Case Report

Urinary Bladder Tuberculosis – A Case Report

MY Ali¹, SA Fattah², MM Islam³, MM Haque⁴, AK Biswas⁴, MA Hossain⁴

Abstract

Genito-urinary tuberculosis is an infrequent but not uncommon condition in countries with high incidence of tuberculosis like Bangladesh. A female patient of 25 years was admitted into Faridpur Medical college Hospital with acute retention of urine with history of haematuria, dysuria, fever and difficulty in urination for about three years. USG revealed few masses in the urinary bladder, later proved by histopathological examination as granulomatous lesion consistent with tuberculosis. Anti-TB treatment was given and the masses were removed surgically. With this treatment recovery of the patient is satisfactory and symptoms are disappearing. The aim of this study to make internist more efficient to diagnose the disease by strong clinical suspicion and relevant laboratory investigation, otherwise such uncommon disease and its complications may endanger life of such patient.

Introduction

Genito-urinary tuberculosis is the second most common form of extra-pulmonary tuberculosis comprising 3-5% of all tuberculosis cases¹. Bangladesh ranks 5th among the 22 countries with high incidence of tuberculosis globally but genito-urinary tuberculosis are diagnosed relatively infrequently². Mycobacterium tuberculosis reaches the urinary tract via the blood stream from a primary focus in the lung or bowel, occasionally as tertiary spread from a lesion in the bone. From the pelvicalyceal system of the infected kidney, tubercle bacilli reach the urinary bladder through ureters. In the urinary bladder granulomatous lesion develops in the form of tumor-like mass or ulcer³. If not detected or treated early, it may cause obstructive uropathy. Extensive fibrosis of the urinary bladder may lead to a shrunken small urinary bladder (thimble bladder). Irritative voiding symptoms, painless haematuria and persistent sterile pyuria are the common presenting features. Constitutional symptoms may be less prominent than the local symptoms. History of

pulmonary tuberculosis or co-existing pulmonary tuberculosis may be present in few cases. Recurrent urinary tract infection with presence of plenty of pus cells in absence of positive urine culture for usual pathogens in acid urine always raise the suspicion of urinary tract tuberculosis⁴. Additional presence of frank haematuria or passage of blood clot in urine may suggest urinary bladder involvement. Complete blood count, urine routine examination and ordinary culture, MT, IVU, USG of urinary tract give the initial diagnostic clue. Detection of AFB by culture or PCR⁵ and histopathological examination confirms the diagnosis of tuberculosis.

In addition to medical treatment with usual Anti-TB drugs, surgical intervention often plays an important role in the management of urinary tuberculosis. Any obstructive lesion needs early detection and intervention to save kidneys. Sometimes medical treatment cures tuberculosis but resulting fibrosis warrants surgical procedure. Relapse after initial cure is also reported in few cases⁶. So close follow up and monitoring should be continued throughout the treatment period and also for few years afterwards.

Case report

A female patient of 25 years, housewife, non-diabetic, normotensive, hailing from Kotowali, Faridpur, was admitted into Faridpur Medical College Hospital on 24/04/10 with the complaints of retention of urine for one day, and recurrent attack of dysuria, increased frequency of micturition, frank haematuria, difficulty in urination and lower abdominal pain for three years. She

1. Dr. Md. Yusuf Ali, FCPS (Medicine), Associate Professor, Dept. of Medicine, FMC, Faridpur.
2. Dr. Sk. Abdul Fattah, DTCD, FCPS (Medicine), Assistant Professor, Dept. Of Medicine, FMC, Faridpur.
3. Dr. Md. Muzahidul Islam, MBBS, Registrar, Dept. of Medicine, FMCH, Faridpur.
4. Dr. Md. Majharul Haque, MBBS, Dr. Ananta Kumar Biswas, MBBS, Dr. Md. Azmol Hossain, MBBS, Assistant Registrar, Dept. of Medicine, FMCH, Faridpur.

Address of the correspondence

Dr. Md. Yusuf Ali, FCPS (Medicine),
Associate Professor, Dept. of Medicine, FMC, Faridpur.
Phone: +88-01711425121.

had history of fever, dry cough and loss of body weight for the same duration. Repeated courses of different antibiotics failed to relieve her symptoms – rather the situation gradually worsen. Physical examination revealed marked anaemia, temperature 100^oF and lower abdominal distention. There was no lymphadenopathy, organomegaly or chest abnormality. Complete blood count showed Hb-49%, ESR- 85 mm in 1st hour, on urine R/E - trace albumin, plenty of pus cells and RBCs were found. Ordinary urine culture yielded no organism. Urine culture for AFB was not done due to lack of facility. X-ray chest P/A view, RBS, Blood urea and serum creatinine were normal. USG of the whole abdomen revealed bilateral moderate hydronephrosis more marked on the right side and few small solid masses on the right wall of the urinary bladder.

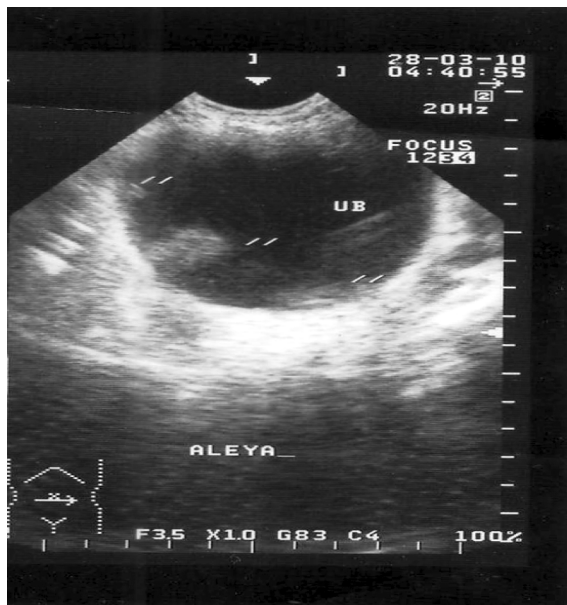


Figure 1: Ultrasonographic image of Urinary bladder tuberculosis, multiple nodular shadows in urinary bladder.

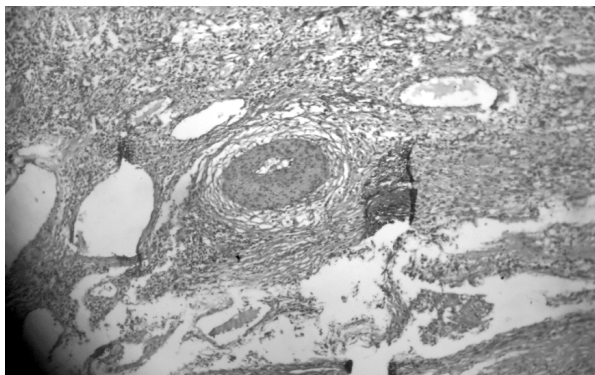


Figure 2: Histopathological film of urinary bladder tuberculosis

Histopathological examination of tissue from the urinary bladder mass after diathermic fulguration revealed granulomatous inflammatory lesion consistent with tuberculosis. Category-I anti-tuberculous drugs with four drug regimen started along with prednisolone 30mg/day, omeprazole and pyridoxine. Initial retention was relieved by catheterisation. The patient is now on anti-TB drugs, under regular follow up and improving satisfactorily.

Discussion

Genito-urinary tuberculosis although less common, but it is not a rare entity in Bangladesh. It affects mainly the young people like pulmonary TB and bears the same risk factors⁷. Persistence cystitis unresponsive to antibiotics, urinary frequency, dysuria, haematuria along with general symptoms of tuberculosis are the main presenting features. Usually the infection arises insidiously and progresses over a long period without any symptoms. Coexistence of pulmonary tuberculosis or past history of tuberculosis may be present in some cases. The presented patient is a young female of 25years suffering from recurrent urinary symptoms and haematuria for about 3 years unresponsive to different antibiotics. Although she had cough and low grade fever for 3 years but no sputum production or haemoptysis and her X ray chest was normal, yet suspicion of co-existent pulmonary tuberculosis cannot be ruled out.

Persistent sterile pyuria in acidic urine with absence of any organism on ordinary urine culture is the main clue of diagnosis of urinary tract tuberculosis⁴. In this case the same feature was found. In addition she had lower abdominal pain, retention of urine, hesitancy, frank haematuria and plenty of RBCs in routine urine examination. These raised the suspicion of urinary bladder involvement. USG of whole abdomen revealed bilateral hydronephrosis with few masses in the urinary bladder wall but no localized stricture was suggested. History of prolonged symptoms in a young patient like this case made malignant lesion unlikely. Histopathological examination of the masses ruled out malignancy and suggested tuberculous lesion. Urinary culture for AFB or PCR detection of mycobacterial DNA was not done due to lack of facility. Normal blood urea and serum creatinine suggested functionally intact kidneys. IVU was not done during initial diagnosis but it was planned to be done during follow up visits to rule out any localized stricture formation⁷.

Treatment of the patient was initiated with anti-tuberculous chemotherapy comprising 4-drugs and it will be continued for at least 9 months⁷. The patient is now on treatment under regular follow up and is improving satisfactorily.

Conclusion

Tuberculosis of the urinary tract should be strongly considered in any young patient with persistent or recurrent UTI, sterile pyuria and painless haematuria. Lack of facility for detection of AFB in urine is a major obstacle to the early detection of urinary tract tuberculosis. Once detected, close supervision by physician and surgeon is very important for diagnosis and management of any obstructive complication. Sometimes reconstructive surgery is also required for extensive fibrotic complications. Strong suspicion in relevant situations is the main stay of diagnosis of this infrequent but not uncommon disease.

References

1. Wise GJ, Marella VK. Genitourinary manifestations of tuberculosis. *Urol Clin North Am* 2003;30:111-21.
2. World Health Organization. Tuberculosis in the South East Asia Region, 50 years commemorative series 4. New Delhi: WHO (Regional Office for the South East Asia), 1998.
3. Clinman AC. Genitourinary tuberculosis. *Urology* 1982;20:353.
4. Benchekroun A, Lachkar A, Soumana A, Farih MH, Belahnech Z, Marzouk M, et al. Urogenital tuberculosis: 80 cases. *Ann Urol (Paris)* 1998;32:89-94.
5. Dye C, Hosseini M, Watt C. Did we reach the 2005 targets for tuberculosis control? *Bull World Health Organ* 2007;85:364-9.
6. Wong SH, Lau WY, Poon GP. The Treatment of Urinary tuberculosis. *J Urol.* 1982;131:297.
7. Akbar MA, Rashid H, Islam MS. Genitourinary Tuberculosis- A Retrospective study of 30 (Thirty) cases. *Bangladesh Armed Forces Medical Journal* 2002;XXIX:41-45.