

## Case Report

### " Lutembacher's Syndrome " - A Case Report

SY Ali<sup>1</sup>, M Rahman<sup>2</sup>, M Islam<sup>3</sup>, RC Barman<sup>4</sup>, MY Ali<sup>5</sup>, MMSU Islam<sup>6</sup>

#### Abstract

Lutembacher's Syndrome is a rare heart disease comprises ASD (congenital) secundum with Mitral stenosis (Rheumatic origin). The patient Md. Mosharraf Hossain, 72 years old man, non diabetic, non hypertensive, smoker admitted in FMCH on 10.10.2010 with the complaints of respiratory distress and chest pain for 10 days. He had a previous history of Rheumatic fever in early childhood. There was history of recurrent attack of Rheumatic fever. Subsequently he developed MS from Rheumatic carditis. ASD was congenital in origin. If diagnosis could be done earlier, surgical closure of ASD with replacement of mitral valve bears a good prognostic value. Our patient is in elderly age and already developed pulmonary hypertension, operative procedure is not suitable. So the patient should be kept in conservative treatment.

Key words: Lutembacher's syndrome, Atrial Septal Defect, Mitral stenosis, Septum primum, Septum secundum.

#### Introduction

Heart disease comprises - congenital heart disease and acquired heart disease. There are many heart diseases which are very complex form, that is combination of congenital and acquired in origin. Lutembacher's syndrome is one of the complex heart diseases and its incidence is very rare<sup>1</sup>. It comprises Atrial Septal Defect (ASD) Secundum with Mitral stenosis (MS). Inter-atrial septum develops from two sources-septum primum and septum secundum. If defect in the formation of septum primum-it

forms ASD (Primum) and If defect in the formation of septum secundum it forms ASD (secundum). Mitral stenosis is an acquired heart disease develops due to recurrent attack of Rheumatic carditis. So, for the development of Lutembacher's syndrome defect in the formation of septum secundum and recurrent Rheumatic carditis are required.

1. Dr. SK. Yunus Ali, MD (Cardiology), Assistant Professor, Dept. of Cardiology, FMC, Fardipur.
2. Dr. Md. Mustafizur Rahman, D.Card, Assistant Professor, Dept. of Cardiology, FMC, Fardipur.
3. Dr. Md. Muzahidul Islam, MBBS, Registrar, Dept. of Medicine, FMCH, Fardipur.
4. Dr. R.C. Barman, DTCD, Assistant Professor, Dept. of Respiratory Medicine, FMC, Fardipur.
5. Dr. Md. Yusuf Ali, FCPS (Medicine), Associate Professor, Dept. of Medicine, FMC, Fardipur.
6. Dr. M. M. Shahin-Ul-Islam, FCPS (Medicine), MD (Gastro), Assistant Professor, Dept. of Gastroenterology, FMC, Faridpur.

#### Address of Correspondence:

Dr. SK. Yunus Ali, MD (Cardiology), Assistant Professor, Dept. of Cardiology, FMC, Fardipur. Mob: +88-017-11208966  
E-mail: drskyunusali@gmail.com

#### Case Report

Md. Mosharraf Hossain 72 years old, non diabetic, non hypertensive, smoker, Farmer, hailing from Goalanda, Rajbari was admitted in Faridpur Medical College Hospital on 10.10.2010 with the complaints of respiratory distress and chest pain for 10 days. Respiratory distress is more in lying position and also during exertion. His respiratory distress status is qualified as NYHA-G-III (New York Heart Association.) and within last 2 years he developed several episodes of respiratory distress. On examination pulse was 80 beats/min, irregularly irregular, BP - 100/70 mm of Hg, Jugular Venous Pressure (JVP) was raised, ankle oedema present. Precordial examination reveals early systolic murmur on pulmonary area and mid diastolic murmur on mitral area. Respiratory system examination reveals bilateral basal crepts.



Per abdominal examination reveals enlarged and tender liver.

**Investigations done -**

1. 12 lead ECG - shows Right Bundle Branch Block with Atrial Fibrillation
2. RBS - 5 mmol/L
3. Blood Urea - 27 mg/dl
4. S. creatinine - 0.9 mg/dl
5. S. cholesterol - 190 mg/dl
6. X-ray chest PA view - shows gross Cardiomegaly with Pulmonary Congestion with fullness of Pulmonary conus
7. Echocardiography - shows Severe Mitral stenosis with large ASD with Pulmonary hypertension.

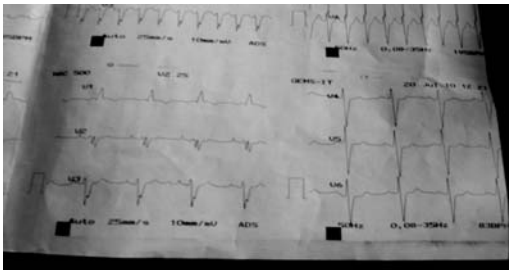

Fig - ECG

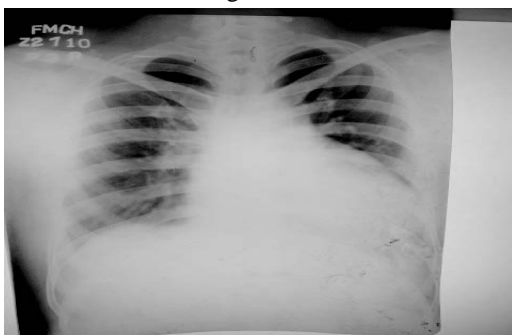

Fig - X- ray chest PA view

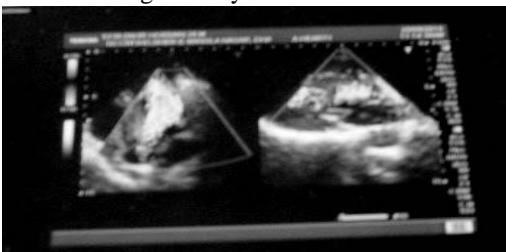


Fig - Echocardiography

Diagnosis - Severe Mitral stenosis with ASD (Lutembacher's Syndrome) with heart failure with Atrial fibrillation.

Patient was treated conservatively with Digoxin, Diuretics, ACE inhibitor, Esomeprazole and Tranquilizer. With the above conservative treatment patient was improved significantly.

**Discussion**

Lutembacher's syndrome comprises Mitral Stenosis with ASD. Its incidence is very rare. In one study published in American Heart Journal in 1997, it is found that the incidence of Lutembacher's syndrome is-0.001/10,00000. Early diagnosis and surgical treatment bears a good prognostic value. If patient is diagnosed at late stage, pulmonary hypertension and heart failure develops and the prognosis is bad<sup>2</sup>. If the patient is diagnosed earlier before the development of pulmonary hypertension and heart failure - ASD closure with Mitral valve replacement bears a good prognosis and prolongs survival. Our patient, Md. Mosharraf Hossain is an elderly patient and already developed pulmonary hypertension, so operative treatment is not possible and the patient is kept in conservative treatment-optimizing medical therapy with adequate control of heart failure and with Rheumatic prophylaxis.

**Summary and Conclusion**

Lutembacher's syndrome is a rare, complex, congenital heart diseases. Early diagnosis and operative treatment has a good prognostic value but late diagnosis and development of heart failure bears bad prognosis. Most of the patients die subsequently due to heart failure, cardiac arrhythmias and thrombo-embolic cerebro vascular diseases<sup>3</sup>. Early diagnosis and management can reduce morbidity and mortality.

**References**

1. Bashi VV, Ravikumar E, Jairaj PS, Andrews K, Edward F, Boimean PJ, et al. Coexistent mitral valve disease with left to right shunt at the atrial level : clinical profile, haemodynamics and surgical consideration in 67 consecutive patients. Am Heart J 1987;114:1406.
2. Levin AR, Spach MS, Boimeau JP, Cropton M, Edward Andrews, Clerk J, et al. Atrial Pressure flow dynamics and atrial septal defects (Secundum type). Circulation 1968;37:476.
3. Suzuki K, Ho SY, Anderson RH, Selman D, Richard K, Macmaham D, et al. Morphometric analysis of atrio-ventricular septal defect with common valve orifice. J Am Cardiol 1998;31:217.