

# Measurement of Peak Systolic Velocities and End Diastolic Velocities of Common Carotid, Internal Carotid and Vertebral Arteries of Healthy Adult Subjects by Duplex Colour Doppler Sonography : A Study of 100 Cases

Jamil Haider Chowdhury<sup>1\*</sup> Krishna Kishore Saha<sup>2</sup>

## ABSTRACT

**Background :** Duplex Colour Doppler Sonography is a well-accepted non invasive means for diagnosis and evaluation of carotid and vertebral artery disease. As these arteries are the main supply of brain, determination of their percentage of stenosis accurately is very much important. The accuracy of measurement of percent stenosis using doppler technique depends significantly on measured blood flow velocities in these arteries. As a result, a normal reference value of peak systolic velocity and end diastolic velocity for these arteries are needed upon which the calculation of percentage stenosis depends. At this context, this study was done with the following objectives: To measure Peak Systolic Velocities and End Diastolic Velocities of common carotid, internal carotid and vertebral arteries of healthy adult subjects by duplex colour doppler sonography, to estimate the velocity difference in extra - cranial neck vessels of right and left side and to observe the velocity difference between males and females.

**Materials and methods :** This cross-sectional study was conducted among Bangladeshi healthy adult subjects in the Department of Radiology and Imaging, Bangabandhu Sheikh Mujib Medical University (BSMMU) from January 2009 to December 2009. 100 Bangladeshi healthy adult subjects were selected which included 50 males and 50 females. All the subjects underwent duplex colour doppler scanning of their Common Carotid Artery (CCA) Internal Carotid Artery (ICA) and Vertebral Arteries (VA) on both sides. Peak Systolic Velocities (PSV) and End-Diastolic Velocities (EDV) of the above arteries on both sides were recorded for analysis.

**Results:** In case of male subjects, mean PSV of common carotid, internal carotid and vertebral arteries on the right side are 66, 57 and 30 cm/sec and on the left side are 72, 58 and 32 cm/sec consecutively. In the case of male subjects, mean EDV of common carotid, internal carotid and vertebral arteries on the right side are 19, 16 and 10 cm/sec and on the left side are 21, 21 and 15 cm/sec consecutively.

In case of female subjects, mean PSV of common carotid, internal carotid and vertebral arteries on the right side are 62, 57 and 29 cm/sec and on the left side are 65, 57 and 30 cm/sec consecutively. In the case of female subjects, mean EDV of common carotid, internal carotid and vertebral arteries on the right side are 20, 19 and 14 cm/sec and on the left side are 21, 17 and 14 cm/sec consecutively.

**Conclusion:** From this study, we have provided reference values of peak systolic velocity and end diastolic velocity for these arteries (CCA, ICA & VA) in Bangladeshi population.

**Key words:** Common Carotid Artery (CCA); End Diastolic Velocities (EDV); Internal Carotid Artery (ICA); Peak Systolic Velocities (PSV); Vertebral Arteries (VA).

## Introduction

Among the various imaging tools in the Department of Radiology and Imaging, use of Duplex Colour Doppler

Sonography is gaining increasing popularity for assessment of blood vessels in various disease processes around the world. Vessel assessment is now much easier than ever before without the need for radiation as well as contrast media. Out of various referrals of Doppler examinations in the Department of Radiology and Imaging, duplex colour doppler sonography of carotid and vertebral arteries contains the majority percentage at present. There are many neurological symptoms that suggest the need for a duplex colour doppler examination of the extra - cranial neck vessels. Amaurosis fugax, transient ischemic attack, stroke, bruit in the region of carotid bifurcation, a palpable mass in the neck may be included as the common neurological manifestations. Duplex colour doppler ultrasonogram is also used to evaluate cerebrovascular flow prior to surgical procedures, such as a cardiac operation, to ensure adequate

1. Associate Professor of Radiology and Imaging  
Chattogram Maa-O-Shishu Hospital Medical College, Chattogram.
  2. Assistant Professor of Radiology & Imaging  
Southern Medical College, Chattogram.
- \*Correspondence : **DR. Jamil Haider Chowdhury**  
Cell : +88 01711 56 69 42  
Email : chowdhuryjamil@hotmail.com

Date of Submission : 10th May 2021  
Date of Acceptance : 20th June 2021

perfusion of the brain in the event of a drop in blood pressure during anesthesia. There is 17% increase of stroke during surgery in patients with a carotid artery stenosis of 60% or greater<sup>1</sup>. The progress of carotid artery disease in the asymptomatic patient can also be followed by duplex colour doppler sonography, since in most institutions surgical intervention is post-poned until either the patient becomes symptomatic or stenosis exceeds 80%<sup>2</sup>. Duplex colour doppler sonography is the follow up technique of choice for patients who have already underwent carotid end - arterectomy. Many patients redeveloped stenosis with in the next 2 years. For detection and quantification of carotid artery stenosis, seven velocity parameters were determined with doppler spectra and compared with angiographic findings - the peak systolic and peak end diastolic velocities in the internal and common carotid arteries, the ratio of peak systolic and peak end diastolic velocities between the internal and common carotid arteries, and the ratio of peak systolic velocity in the internal carotid artery to peak end diastolic velocity in the common carotid artery. It was concluded that the peak systolic velocity in the internal carotid artery is the best single velocity parameter for quantifying a stenosis and for detecting a 70% or greater stenosis<sup>3</sup>. The doppler measurement of blood flow velocities is central to estimate of carotid and vertebral stenosis with ultra sonogram. These measured velocities can be altered by a variety of technical and physiological factors such as age, sex and disease process<sup>4</sup>. One persistent problem with duplex evaluation of the extra cranial neck vessels is that, different institutions use Peak Systolic Velocities (PSV) ranging from 130 cm/sec to 325 cm/sec to diagnose greater than 70% internal carotid artery stenosis. Many factors are involved in creating these discrepancies including technique and equipment. This wide range of PSV reinforces the need for individual ultra sonogram laboratories to determine which doppler parameters are most reliable in their own institution<sup>5</sup>.

In this context, this study is undertaken to measure the Peak Systolic Velocity (PSV) and End Diastolic Velocities (EDV) of common carotid, internal carotid and vertebral arteries of healthy adult subjects by duplex colour doppler sonography.

#### Materials and methods

This study was conducted among Bangladeshi healthy adult subjects in the Department of Radiology and Imaging, BSMMU from January to December, 2009. 100 subjects were selected which included 50 males and 50 females.

Bangladeshi healthy adult subjects were selected with the following inclusion criteria: Age > 18 years, No H/O drug intake within 7 days prior to examine the adult

subject, No H/O HTN/DM, No H/O other congenital/acquired illness, Intima-Media (IM) thickness of carotid artery < 0.8 mm, Lipid profile: Normal, Blood sugar: Normal.

All the adult healthy subjects underwent duplex colour doppler scanning of their Common Carotid Artery (CCA) Internal Carotid Artery (ICA) and Vertebral Arteries (VA) on both sides after appropriate consent. A competent radiologist re-evaluated each scan.

Peak Systolic Velocities (PSV) and End-Diastolic Velocities (EDV) of the above arteries on both sides were recorded for analysis. The velocities were recorded in three different places of each artery both proximal and distal to a point and mean value of these three were taken out as a round figure and posted on the data sheet. After measuring Peak Systolic Velocities (PSV) and End-Diastolic Velocities (EDV) of CCA, ICA and VA on both sides in the above manner, all the data sheets were checked if there was any posting error. From the data sheets, mean PSV and mean EDV of both sides were calculated for (50) male and (50) female subjects. The mean value of PSV and EDV of both sides were posted in the final data analysis sheet separately for male and female subjects.

Ethical consideration: Prior to commencement of this study, the research protocol was approved by thesis committee of BSMMU.

#### Results

Out of 100 cases, male were 50(50.0%) cases and female were 50(50.0%) cases (Table-I).

In case of male subjects, mean PSV of common carotid, internal carotid and vertebral arteries on the right side are 66, 57 and 30 cm/sec and on the left side are 72, 58 and 32 cm/sec consecutively. In the case of male subjects, mean EDV of common carotid, internal carotid and vertebral arteries on the right side are 19, 16 and 10 cm/sec and on the left side are 21, 21 and 15 cm/sec consecutively (Table-II).

In case of female subjects, mean PSV of common carotid, internal carotid and vertebral arteries on the right side are 62, 57 and 29 cm/sec and on the left side are 65, 57 and 30 cm/sec consecutively. In the case of female subjects, mean EDV of common carotid, internal carotid and vertebral arteries on the right side are 20, 19 and 14 cm/sec and on the left side are 21,17 and 14 cm/sec consecutively (Table-III).

**Table I** Demographic characteristic of the study patients (n=100)

Variables	Frequency	Percentage
Sex		
Male	50	50.0
Female	50	50.0
Total	100	100.0
Age (Mean±SD) years		45.7±12.3

**Table II** Comparison between the right and left side of Peak Systolic Velocities (PSV) and End Diastolic Velocities (EDV) of Common Carotid, Internal Carotid and Vertebral arteries of male subjects

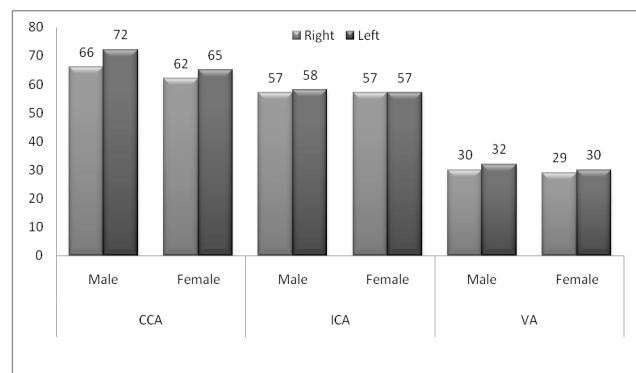
Artery	PSV (cm/sec)	
	Right	Left
Common Carotid	66	71
Internal Carotid	57	58
Vertebral arteries	30	32
	EDV (cm/sec)	
Common Carotid	19	21
Internal Carotid	16	21
Vertebral arteries	10	15

**Table III** Comparison between the right and left side of Peak Systolic Velocities (PSV) and End Diastolic Velocities (EDV) of Common Carotid, Internal Carotid and Vertebral arteries of female subjects

Artery	PSV (cm/sec)	
	Right	Left
Common Carotid	62	65
Internal Carotid	57	57
Vertebral arteries	29	30
	EDV (cm/sec)	
Common Carotid	20	21
Internal Carotid	19	17
Vertebral arteries	14	14

**Table IV** Comparison between male (M) and female (F) subjects: Peak systolic Velocity

Artery	Right	Left
A.CCA	M-66 F-62	M-72 F-65
B.ICA	M-57 F-57	M-58 F-57
C.VA	M-30 F-29	M-32 F-30

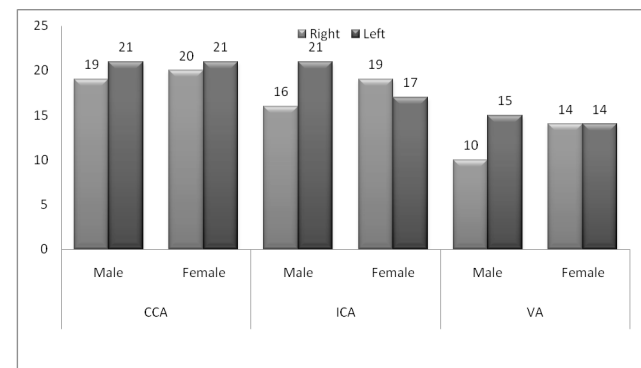


**Figure 1** PSV: Comparison of male and female

In case of CCA, ICA and VA, PSV of male subjects are higher than the females on both sides except the internal carotid artery on the right side. In the right sided ICA, the mean PSV is same for both male and female.

**Table V** Comparison between male (M) and female (F) subjects End Diastolic Velocity

Artery	Right	Left
ACCA	M-19 F-20	M-21 F-21
BICA	M-16 F-19	M-21 F-17
CVA	M-10 F-14	M-15 F-14



**Figure 2** EDV: Comparison of male and female

In case of common carotid artery, EDV of female (20 cm/sec) is higher than male (19 cm/sec) on the right side but equal on the left side (21cm/sec). Regarding internal carotid artery, EDV of female (19 cm/sec) is also higher than male (16 cm/sec) on the right side but reverse on the left side (Male 21 cm/sec and female 17 cm/sec). In vertebral artery, EDV of female (14 cm/sec) is also higher than male (10 cm/sec) on the right side but reverse on the left side (Male 15 cm/sec and female 14 cm/sec).

**Discussion**

From the study, it was found that the PSV and EDV of CCA was higher than the ICA in male and female subjects. This was probably due to increased pressure gradient in CCA from the heart than the more distal ICA. Moreover, the PSV and EDV of VA are much less than the CCA or ICA. This is due to dominant arterial blood supply to brain through the carotid vessels rather than vertebrobasilar system.

Overall, in both male and female subjects, the left sided mean PSV is higher on the left side. However, Mean EDV is higher on the left side in case of male but variable in case of female subjects. This is probably due to more direct communication of left sided vessels with

the arch of aorta than the right. The mean EDV of most of the vessels are also higher on the left side than the right, possibly due to same reason.

Overall, in case of male and female subjects, mean PSV of male is higher than the female on both sides, possibly due to increased systolic pressure difference between male and female. But the mean EDV is variable in male and female subjects on both sides which indicates lack of difference/ fluctuation of diastolic blood pressure in between male and female subjects.

A study was found on standardization of duplex velocity criteria for measurement of carotid stenosis. The study recommends that, angle should be kept at 60 degrees when measuring peak systolic velocity. To avoid incorporating errors in the reading of X-ray angiogram into the velocity criteria, the researcher proposed a theoretical approach to select velocity thresholds. The researcher recommended, each institution should validate their data against X-ray angiography to determine the agreement in their institution. Acceptable limits of reproducibility and accuracy should be defined to enable accreditation of USG operation<sup>6</sup>.

Ability to accurately assess the degree of stenosis has become important with studies like Asymptomatic Carotid Atherosclerosis Study (ACAS) and North American Symptomatic Carotid Endarterectomy Trial (NASCET). Carotid endarterectomy has been proven to be more beneficial than medical therapy in symptomatic patients with a severe (70-99%) internal carotid artery stenosis. More recently, the asymptomatic carotid atherosclerotic study has also demonstrated a reduced ipsilateral stroke risk following carotid endarterectomy in asymptomatic patients with a more than 60% ICA stenosis<sup>7</sup>.

Accurate diagnosis of hemodynamically significant stenosis is critical to identify patients who would benefit from surgical intervention. Duplex sonography, combining high resolution imaging and Doppler spectrum analysis has proven to be popular, non-invasive, accurate and cost effective means of detecting and assessing carotid disease. Carotid sonography has largely replaced angiography for suspected extra-cranial carotid atherosclerosis<sup>8</sup>. In this study, accurate measurement of normal PSV and EDV of carotid and vertebral arteries of healthy adult male and female subjects are identified which can be used for accurate measurement of stenosis in future for Bangladeshi people.

It was found that color doppler assisted duplex ultrasonogram of the carotid arteries to be an accurate, rapid and reproducible means of depicting significant internal carotid artery stenoses. The accuracy, rapidity, and reproducibility of color doppler assisted duplex sonography

in the diagnosis of significant internal carotid artery stenosis were prospectively evaluated. Only the point of maximal color shift on the color map was used for spectral analysis. When compared with angiography in 60 carotid bifurcations, a measured peak systolic velocity above 1.25 m/sec was 87% accurate in the detection of significant internal carotid artery stenoses greater than 50%. Determination of maximal internal carotid artery velocity was 40% faster with color doppler assisted duplex sonography than with non-assisted duplex ultrasound. The authors conclude that the color flow map is an accurate and reproducible means of depicting the point of maximal stenosis within the internal carotid artery<sup>9</sup>. In this study, all the velocity measurement of carotid and vertebral arteries were done using the colour flow map so that accurate measurement of velocity can be identified from the correct point of the vessel.

A study group developed two new criteria for significantly diseased vessels, the ratio of the right to left peak systolic average velocities in the common carotid arteries (Vrcca/ Vlcca) of less than 0.7 or greater than 1.3 and a peak systolic average velocity in the common carotid artery (Vcca) of less than 25 cm/Sec<sup>10</sup>. From this study, normal vessel was found in both male and female subjects using the above criteria. In case of male and female subjects, the ratio of right to left PSV in the common carotid arteries (Vrcca/ Vlcca) are within 0.7 – 1.3 and Peak Systolic Velocity is > 25 cm/sec.

#### Limitations

PSV and EDV of normal healthy adult male and female subjects in carotid and vertebral arteries are very important to obtain as a reference value which can help measure the percentage of stenosis in disease process. The findings of normal mean PSV and mean EDV of male and female subjects in this study was identified only by duplex colour Doppler scan. The findings of each Doppler scan were not correlated with x-ray angiography. If the result of each individual subject could be correlated with invasive angiography, the result would be more accurate as a reference value.

Considering the time to prepare this project, only 100 subjects were selected by inclusion criteria out of which 50 were male and the rest were female. To create standard velocity reference criteria, a large statistically significant sample size with wide duration of time frame is required.

#### Conclusion

From the study, it can be concluded that:

#### In case of male subjects: (Unit of velocity cm/sec)

- PSV of CCA on the right and left: 66 & 72
- PSV of ICA on the right and left: 57 & 58
- PSV of VA on the right and left: 30 & 32
- EDV CCA on the right and left: 19 & 21
- EDV of ICA on the right and left: 16 & 21
- EDV VA on the right and left: 10 & 15



**In case of female subjects: (Unit of velocity cm/sec)**

- PSV of CCA on the right and left: 62 & 65
- PSV of ICA on the right and left: 57 & 57
- PSV of VA on the right and left: 29 & 30
- EDV CCA on the right and left: 20 & 21
- EDV of ICA on the right and left: 19 & 17
- EDV VA on the right and left: 14 & 14

**Comparison between right and left:**

In comparison of right and left side, the mean PSV is higher on the left side in both male and female. However, Mean EDV is higher on the left side in case of male but variable in case of female subjects.

**Comparison between male and female:**

In comparison of male and female subjects, mean PSV of male is higher than the female on both sides. But the mean EDV is variable in male and female subjects on both sides.

**Disclosure**

The authors declared no competing interest.

**References**

1. Roger C. Sanders. Clinical sonography: A practical guide 3<sup>rd</sup> Edition Lippincott- Raven Publishers. 1998.
2. Paul L. Allan, Paul A Dubbins, Myron A. Pozniak, W Norman McDicken Clinical Doppler Ultrasound 2<sup>nd</sup> Edition Elsevier Limited. 2006.
3. Hunink MGM, Polak JF, Barlan MM, O' Leary DH. Detection and quantification of carotid artery stenosis: Efficacy of various Doppler velocity Parameter AJR. 1993; 160:619-625.
4. Carroll BA Carotid sonography. Radiology. 1991; 178:303-313.
5. Rumack CM, Wilson SR, Charboneau JW Diagnostic ultrasound 3<sup>rd</sup> Edition Mosby, Missouri. 2005.
6. N. Thomas, K.B. Modaresi & T.S. Padayachee. Ultrasonic Angiology lab, Division of Radiological Science, UMDS, Guy' Hospital, London, UK. Standardisation of Duplex Velocity Criteria for Measurement of Carotid Stenosis. 2007.
7. North American Symptomatic Carotid Endarterectomy Trial collaborators- Beneficial effect of carotid endarterectomy in symptomatic patients with high grade carotid stenosis. N England J Med. 1991; 325: 445-453.
8. Chaubal N, Padwal M. Carotid Doppler. Kodak. 2000;4-15.
9. Polak JF, Dobkin GR, O' Leary DH, Wang AM, Cutler SS. Internal Carotid artery stenosis: Accuracy and reproducibility of Colour Doppler assisted Duplex Imaging Radiology. 1989; 173: 793-798.
10. Viasman U, Wojeiechowski M. Carotid artery disease. New criteria for evaluation by sonographic duplex scanning. Radiology. 1986;158:253-255.