

# Choledochal Cyst: Experience from A Tertiary Level Hospital of Bangladesh

Adnan Bacha<sup>1\*</sup> Arif Salam Khan<sup>2</sup> Arup Kumar Biswas<sup>3</sup> Zulfikar Rahman Khan<sup>4</sup>

## ABSTRACT

**Background :** Choledochal cysts are rare, congenital abnormal dilatations of the intrahepatic biliary channels of uncertain origin. It may clinically manifest at any age. Biochemical tests are not diagnostic but imaging modalities help in accurate diagnosis. Surgery in the form of complete excision of the cyst with diversion is the treatment of choice and decreases the risk of dreaded complication of cholangiocarcinoma. The aim of this study is to demonstrate the sex distribution, symptomology, biochemical presentation, radiological findings and outcome of surgery in Bangladeshi population.

**Methods and materials:** A total of 12 cases were considered for this study which included all the cases that were admitted at Bangabandhu Sheikh Mujib Medical University (BSMMU) during June 2013 to May 2014. The study also covered the incidence of the type of the cyst, post-operative complications and follow up of the patient for 5 years at least.

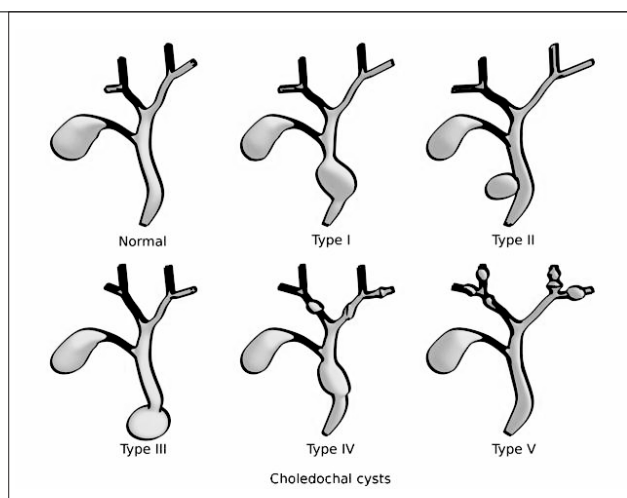
**Results:** 9 of the patients were female and the median age of presentation was 17. Todani type I was the most common type. Patients attended hospital with upper abdominal pain (100%) alongwith other symptoms like vomiting, jaundice, etc. S. bilirubin and alkaline phosphatase were raised in most of the patients. Radiological diagnosis was done effectively by ultrasonography, CT (Computer Tomography) scan and MRCP (Magnetic Resonance Cholangiopancreatography). All the patients underwent complete excision of the Choledochal cyst with cholecystectomy with Roux en Y hepaticojejunostomy and post-operative complications include wound infection (n=2) scar pain and recurrent cholangitis (16.67% each).

**Conclusion:** Surgery is the treatment of choice and decreases the risk of cholangiocarcinoma. Long term follow is required in these patients.

**Key words:** Caroli's disease; Choledochal cyst; ERCP; Hepaticojejunostomy; MRCP.

## Introduction

Choledochal cyst is the cystic dilatation of intra-hepatic or extra-hepatic or both parts of the biliary tract. It is a rare congenital but not familial anomaly and may occur singly or in multiple numbers. The incidence is higher in Asian population 1:1000 compared to 1:100,000 to 1:150,000 in western population<sup>1,2</sup>. Although congenital, symptoms appear in the later part of life. Choledochal cysts also have an unexplained female: male predominance, commonly reported as 4:1 or 3:1<sup>2,3</sup>. In 1977, Todani classified choledochal cyst into five types and subtypes (Figure 1).



**Figure 1** Classification of Choledochal cyst

The most common (50 -80%) is Type I with diffuse or segmental fusiform dilatation of the extra-hepatic biliary channels<sup>4</sup>. Type II saccular diverticulum accounts for only 2% while Type III 1.4 to 4.5% is the cystic dilatation of the intramural part of the CBD also called choledochoceles. Type IV, the second most common (15 -35%) is the multiple dilations of both intra and extra hepatic biliary system and Type V accounts for about 20% of total cases and is characterized by multiple dilations of the intrahepatic biliary ducts and is also called Caroli's disease<sup>5</sup>.

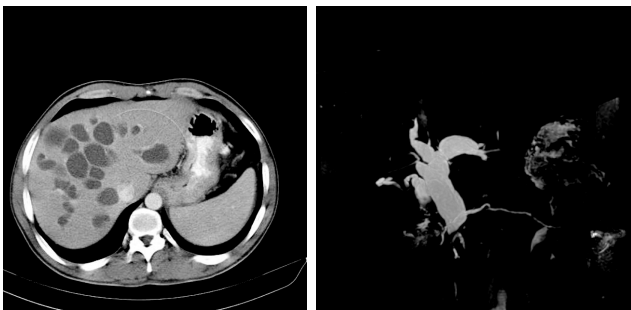
1. Assistant Professor of Surgery  
Southern Medical College, Chattogram.
2. Associate Professor of Surgery  
Bangabandhu Sheikh Mujib Medical University (BSMMU) Dhaka.
3. Medical Officer of Surgery  
Bangabandhu Sheikh Mujib Medical University (BSMMU) Dhaka.
4. Professor of Surgery  
Bangabandhu Sheikh Mujib Medical University (BSMMU) Dhaka

\*Correspondence : **Dr. Adnan Bacha**  
Cell : +88 01873 01 57 47  
Email : adds.adnaan13@gmail.com

Date of Submission : 3rd June 2021  
Date of Acceptance : 15th June 2021

Etiology of choledochal cyst is still unclear, although many theories have been put forth. The most commonly proposed theory is Babbitt's theory, where choledochal cysts are supposed to be caused by an Abnormal Pancreatico-Biliary Duct Junction (APBDJ)<sup>6,7</sup>. Obstruction of the distal CBD is another theory which is supported by studies on animal models<sup>8</sup>. Some authors also suggest pure congenital theory in which abnormally a few ganglionic cells are seen in the distal CBD in the patients with choledochal cyst resulting in proximal dilatation in the same manner as achalasia of oesophagus and Hirschsprung's disease<sup>9</sup>.

Choledochal cysts most commonly present in childhood and about 25% patients present in adulthood. The classical triad of symptoms, which include abdominal pain, palpable abdominal mass and jaundice, are seen in less than 20% of cases. About 85% of children have at least 2 features of classic triad, whereas only 25% of adults present with 2 features of the classic triad<sup>10</sup>. Improved imaging techniques have made diagnosis of choledochal cyst possible, and can be diagnosed even antenatally. Abdominal ultrasonography is the first imaging modality generally used and is considered as the test of choice for the diagnosis of choledochal cyst<sup>11</sup>. Other useful imaging modalities include CT (Computer Tomography) scan, MRI (Magnetic Resonance Imaging) of the abdomen and Magnetic Resonance Cholangiopancreatography (MRCP). MRCP is regarded as the "gold standard" for the diagnosis of choledochal cyst with sensitivity for diagnosis as high as 90 -100%<sup>12</sup> (Figure 2).



**Figure 2** CT scan picture showing multiple intrahepatic cystic dilations and dilatation of the CBD (Caroli's disease) & MRCP image showing fusiform dilation of the CBD (Type 1)

Cholangiocarcinoma is the most feared risk, but early diagnosis and appropriate surgical intervention with complete removal of the cyst appears to decrease the risk of development of malignancy. Perforation is another complication of the choledochal cyst and might mimic perforation of hollow viscus<sup>13</sup>. Management of Choledochal cyst has undergone a lot of development

in past years. McWhorter first described cyst excision and hepaticojejunostomy in 1924 but was soon abandoned because of multiple complications. Other strategies that evolved with time include cyst marsupialization with choledochorrhaphy and cystenterostomy, which were once popular procedures for the management of the disease. High risk of malignancy in the cyst helped regain excision of the cyst with Roux en Y hepaticojejunostomy to become the surgery of choice for choledochal cysts<sup>14</sup>. Laparoscopic resection of Choledochal cyst has been widely used recently, but in spite of advantages like less bleeding, shorter fasting time and shorter hospital stay pose disadvantages like technical differences and frequently inevitable complications<sup>2</sup>.

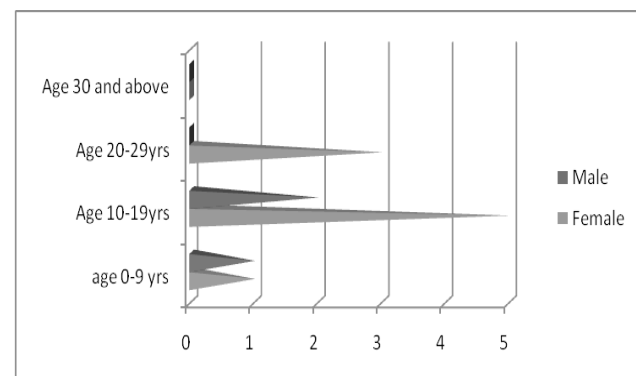
### Methods and materials

A prospective study was carried out at Bangabandhu Sheikh Mujib Medical University (BSMMU) Dhaka, Bangladesh from May 2013 to June 2014. A total of 12 patients were admitted for choledochal cyst and evaluated.

Patients were included if they had been diagnosed with choledochal cyst and underwent surgery, but the patient underwent drainage procedure were not considered for the study. Statistical analyses were performed with Statistical Package for Social Sciences (SPSS 19.0 software).

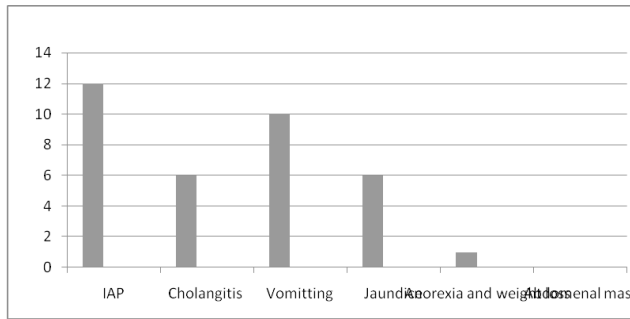
### Results

A total of twelve (12) patients were treated for choledochal cyst, of whom 9 (75%) were female with a male female ratio of 1:3 (Figure 3).



**Figure 3** Pyramidal graph representing sex and age distribution of the Choledochal cyst

The mean age of presentation was 16, and median 17. The presenting complaints varied, however all the patients presented with intra-abdominal pain (100%) while half of them presented with cholangitis and half with jaundice. Vomiting was second most common presentation (83.33%). The symptoms are summarized in Figure 4.

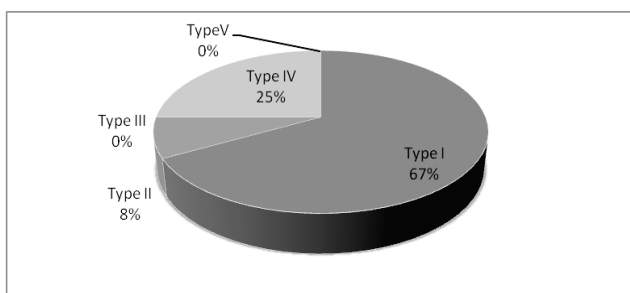


**Figure 4** Presenting symptoms of the patients with Choledochal cyst

Laboratory findings demonstrated neutrophilic leucocytosis in 4 patients (33.33%). Liver function tests were done in which SGPT was elevated in 33.33% (n=4) and SGOT in 8.33% (n=1), while alkaline phosphatase was increased in 66.67% (n=8). S. Albumin was less in (50%) 6 patients but was unexpectedly more in one patient. Serum bilirubin was increased in 11 patients (91.67%). Tumor marker was done to correlate with malignancy, it was normal in all the cases except 1 (8.33%) which too was not significantly high. Prothrombin time and INR was seen to be normal in all the cases. Findings are summarized in Table I.

**Table I** Biochemical results of patients presenting with Choledochal cyst

S. No.	Blood Test	Levels		
		Normal	Increased	Decreased
1.	CBC			
	Leucocytosis	8	4	-
	Neutrophilia	8	4	-
	LFT			
2.	SGPT	8	4	-
	SGOT	11	1	-
	Alkaline Phosphatase	4	8	-
	S. Bilirubin	1	11	-
	S. Albumin	5	1	6
	3.	CA19-9	11	1
4.	PT/INR	12	-	-



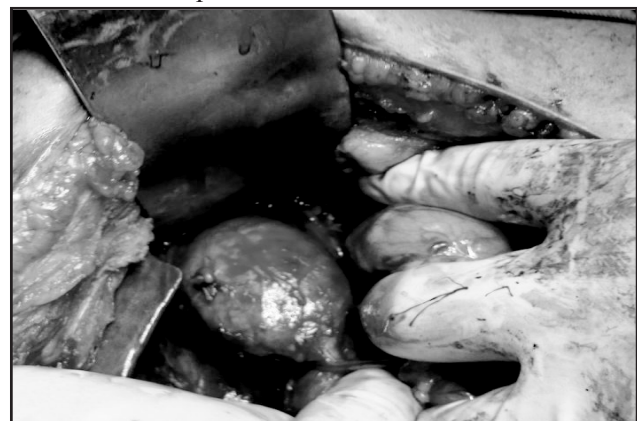**Figure 5** Pie chart showing frequency of different Types of Choledochal cysts in Bangladeshi population

In our case series we have considered Ultrasonography (USG) Computer Tomography (CT) and Magnetic Resonance Cholangio-Pancreaticography (MRCP) for all the cases in order to come to a pre-operative diagnosis, classification and hence planning of the surgery. All the three imaging modalities were seen to be effectively able to diagnose and classify Choledochal cyst. Out of 12 cases, 8 (66.67%) were type I, 3 (25%) were type IV and 1 (8.3%) were diagnosed as type II choledochal cyst (Figure 5).

Strikingly it was seen that in all the 12 (100%) cases, some sort of stone disease in the form of cholelithiasis or choledocholithiasis or hepaticolithiasis or combination of two or all were present.

Our approach was through a right subcostal or a roof top incision. Complete excision of the cyst with cholecystectomy and Roux-en Y hepaticojejunostomy was done in all 12 cases (100%). Irrigation and choledoscopic extraction of the stones was done where ever required. Specimen were sent for histopathological examination which revealed chronic cholecystitis and features compatible with choledochal cyst (n=12). None of the specimen was positive for malignancy.

The early post-operative complication was that only two patients developed wound infection, which was managed by regular dressing, broad spectrum antibiotics based on culture sensitivity report and later secondary closure of the wound. The median duration of the hospital stay was 12 days (Range 6 to 36 days). No post-operative mortality was seen within 30 days of follow up. Planned follow up at the interval of 1 month, 6 months, 12 months, 3 years and 5 years was done using tools like physical examination, ultrasonography of whole abdomen and CA19-9. During follow up 2 (16.67%) patients complained of mild scar pain treated effectively by mild to moderate analgesics while as another 2 patients had features of recurrent cholangitis, both of them were treated conservatively by antibiotics. Ultrasonography revealed retained stone in one patient. No evidence of malignancy or anastomotic stricture was seen on follow up.



**Figure 6** Per-operative picture of Choledochal cyst

### Discussion

Choledochal cyst is an abnormal dilatation of the biliary channel. Worldwide incidence is less than 1:13000 persons but it appears to be a little commoner in Japan with an incidence of about 1:200<sup>1</sup>. No such data is available for Bangladesh. This is much common in female 4:1, which is somewhat similar to the result of our study where female: male ratio was 3:1.<sup>(2, 3)</sup> It can affect any age, but is common in children and younger age group. In this study (n=7) the age group was between 10 -14 years<sup>10</sup>. Etiology is still unclear, although many theories have been put forth. The most commonly proposed is the Babbit's theory of long common channel<sup>6,7</sup>. The classical triad of symptoms jaundice, abdominal pain and abdominal mass is not always present, however two of the symptoms are present in most of the patients. The most common presentation is intra-abdominal pain<sup>10</sup>. In our study all the patients presented with intra-abdominal pain while none presented with intra-abdominal mass. Type I choledochal cyst fusiform dilatation of the extra-hepatic biliary channels is the most common variety of the disease (60-80%)<sup>4</sup>. Which is similar to our study where 8 (66.67%) patient were diagnosed as Type I disease. Although ultrasonography can detect the cyst in almost all the cases, MRCP and CT Scan should be done to diagnose any intra- hepatic cyst or dilatation and for pre-operative planning for surgery<sup>10</sup>. Relationship between the stone disease and choledochal cyst is not established but it appears that there is a very high chance of development of some sort of stone (Choledocholithiasis / Hepaticolithiasis) in choledochal cysts as all of our patients had some sort of stone disease associated. This probably may be related to repeated attacks of cholangitis and stasis of bile within the cyst. All the imaging diagnostic tools proved to be equally effective in diagnosis and determination of the type of the disease.

Cholangiocarcinoma is the most feared risk but early diagnosis and appropriate surgical intervention with complete removal of the cyst appears to decrease the risk of development of malignancy<sup>11</sup>. All the patients in this study where below the age of 30 years and none had any evidence of malignancy histopathologically. Surgical approach for choledochal cyst has evolved over the years from cystoenterostomy to complete excision with hepaticojejunostomy. Further minimal access technique (ERCP) is the treatment of choice for the type III choledochal cyst. Laparoscopic techniques have been increasingly applied in recent years, although their use in complex hepatobiliary procedures has been constrained<sup>15</sup>. Hence treatment depends upon the type of the choledochal cyst. Some controversies are present with the treatment of type IV and type V choledochal

cyst. As a rule extrahepatic cyst should be removed in totality, while as intrahepatic cyst if localized should be considered for hepatectomy<sup>16</sup>. Complete excision of the cyst with cholecystectomy and Roux-en Y hepaticojejunostomy was done in all the patients through open approach at our center.

Early post-operative complications like anastomotic leak, pancreatitis, biliary peritonitis, anastomotic stricture are minimal nowadays from a good surgical technique, but the operation should be done by a dedicated hepato-biliary team at higher center<sup>2</sup>. Wound infection still remains a problem and was treated with antibiotics after culture sensitivity. During the follow up time none of the patients developed complications like malignancy or hepaticolithiasis.

### Conclusion

Although rare, choledochal cyst remains an interesting and somewhat challenging clinical problem because of its late and non-specific presentation. Hence it should be considered as a differential diagnosis for obstructive jaundice. Biochemical markers are non-specific but imaging may lead to specific diagnosis and pre-operative planning of surgery. Complete excision of the cyst with Roux-en Y hepaticojejunostomy is the treatment of choice. Specimen should be sent for histopathological examination to exclude malignancy which may warrant further investigations and treatment.

### Recommendations

Further long time follow up is required, to prove that complete excision of the cyst removes all the risk of development of cholangiocarcinoma.

### Disclosure

All the authors declared no conflict of interest.

### References

1. Yamaguchi M: Congenital choledochal cyst. Analysis of 1,433 patients in the Japanese literature. *Am J Surg.* 1980;140:653-657.
2. Zhang B, Wu D, Fang Y et al. Early complications after laparoscopic resection of choledochal cyst. *Pediatr Surg Int.* 2019;35:845-852. <http://doi/10.1007/S00383-019-04489-Y>.
3. Liu CL, Fan ST, Lo CM, Lam CM, Poon RT, Wong J. Choledochal cysts in adults. *Arch Surg.* 2002;137:465-468.
4. Todani T, Watanabe Y, Narusue M, Tabuchi K, Okajima K: Congenital bile duct cysts: Classification, operative procedures and review of thirty-seven cases including cancer arising from choledochal cyst. *Am J Surg.* 1977;134:263-269.
5. Gorenstein L, Strasberg SM. Etiology of choledochal cysts: Two instructive cases. *Can J Surg.* 1985;28:363-367.

6. Babbitt DP. Congenital choledochal cyst: New etiological concept based on anomalous relationships of the common bile duct and pancreatic bulb. *Ann Radiol (Paris)*. 1969;12:231-240.
7. Saeed A, Assiri A. Choledochal cyst and biliary stone. *J Ayub Med Coll Abbottabad*. 2018;30(1):127-129.
8. Spitz L. Experimental production of cystic dilatation of the common bile duct in neonatal lambs. *J Pediatr-Surg*. 1977;12:39-42.
9. Kusunoki M, Saitoh N, Yamamura T, Fujita S, Takahashi T, Utsunomiya J. Choledochal cysts oligoganglionosis in the narrow portion of the choledochus. *Arch Surg*. 1988;123:984-986.
10. Levy AD, Rohrmann CA Jr, Murakata LA, Lonegan GJ. Caroli's disease: Radiologic spectrum with pathologic correlation. *AJR Am J Roentgenol*. 2002;179:1053-1057.
11. Levy AD, Rohrman CA. Biliary cystic disease. *CurrProblDiagnRadiol*. 2003;32:233-263.
12. Park DH, Kim MH, Lee SK et al. Can MRCP replace the diagnostic role of ERCP for patients with choledochal cysts? *GastrointestEndosc*. 2005;62:360-366.
13. Kim SH, Cho YH and Kim HY. Perforated Choledochal Cyst: Its clinical implications in Paediatric patients. *PediatrGastroenterolHepatolNutr*. 2020; 23(3):259-265. <http://doi.org/10.5223/pghn.2020.23.3.259>.
14. Kasai M, Asakura Y, Tamia Y. Surgical treatment of Choledochal cyst. *Ann Surg*.1970;172:844-851.
15. Arra A, Bascombe N, Smith BL, Bartholomew M and Dan D. Choledochal cyst mimicker- When small bowel length matters. *Int J of Surgery Case Reports*. 2020;68:132-135. <http://doi.org/10.1016/j.ijscr.2020.02.061>.
16. Pandit N, Deo K, Yadav TN et al. Choledochal Cyst: A Retrospective study of 30 Cases from Nepal. *Cureus*. 2020; 12(11):e11414. DOI 10.7759/cureus.11414.