

## ORIGINAL ARTICLE

# Percutaneous Transvenous Mitral Commissurotomy: In-hospital Outcome of Patients with Mitral Stenosis

Syed Dawood Md. Taimur<sup>1</sup>, Md. Rezaul Karim<sup>2</sup>, M. Maksumul Haq<sup>3</sup>, Md. Liaquat Ali<sup>4</sup>, Mahbub Mansur<sup>5</sup>, Mashhud Zia Chowdhury<sup>6</sup>, Saidur Rahman Khan<sup>7</sup>

### ABSTRACT

**Background & objectives:** Percutaneous transluminal mitral commissurotomy (PTMC) is a popular procedure for treatment of a selective group of patients with mitral stenosis of rheumatic origin. Short and mid-term follow-up results using Inoue balloon technique are well recognized in our setting. Though echo-scoring by echocardiography is a popular method of patient selection, it does not always correlate well with a good post-procedural outcome. The aim of this study was to evaluate the results after percutaneous transluminal mitral commissurotomy (PTMC) in Bangladeshi patients.

**Methods:** This prospective observational study was carried out in the Department of Cardiology, Ibrahim Cardiac Hospital & Research Institute, Dhaka, Bangladesh, over a period of 2 years from April, 2008–April, 2010, on 61 patients of mitral stenosis who underwent PTMC to see immediate outcome of the patients. Successful outcome was defined as an increase in mitral valve area (MVA)  $> 1.5 \text{ cm}^2$  or  $> 50\%$  increase in preprocedural MVA.

**Results:** The immediate clinical follow-up of 61 patients who underwent PTMC resulted in an increase in mitral valve area from  $0.83 \pm 0.15$  to  $2.02 \pm 1.06 \text{ cm}^2$  ( $p < 0.0001$ ). The peak pressure gradient (PPG), mean pressure gradient and pulmonary arterial systolic pressure (PASP) were observed to be significantly reduced from their pre-PTMC state ( $26.8 \pm 6.4$  vs.  $8.9 \pm 3.1$  mm Hg,  $p < 0.00$ ;  $15.1 \pm 3.9$  vs.  $4.0 \pm 1.5$  mm Hg,  $p < 0.001$ ;  $60.0 \pm 21.0$  vs.  $38.7 \pm 9.5$  mm Hg,  $p < 0.001$ ). There was 1(0.5%) in-hospital death. Emergency mitral valve replacement (MVR) was required in 1(0.5%) patient and pericardial tamponade occurred in 1(0.5%) patient. Overall procedural success was 95%.

**Conclusion:** Our data suggest that PTMC is a safe and effective treatment for a selective group of patients of mitral stenosis. However, it is a difficult task to select those patients with mitral stenosis who will be the best candidate for PTMC without any or fewer procedure-related complications.

**Key words:** Percutaneous transluminal mitral commissurotomy; mitral stenosis; rheumatic heart disease.

### Introduction

Mitral stenosis (MS) is one of the commonest long term complications of rheumatic fever<sup>1</sup> and approximately 25% of all patients with rheumatic heart disease have pure mitral stenosis. A female preponderance is observed in patients of rheumatic mitral stenosis.<sup>2</sup> Mitral stenosis is defined as mild, moderate and severe according to existing mitral valve area. If mitral valve area is

$> 1.5 \text{ cm}^2$ , it is mild, if  $1-1.5 \text{ cm}^2$  it is moderate and if  $< 1 \text{ cm}^2$  it is considered as severe mitral stenosis.<sup>3</sup> Medical treatment is indicated in mild to moderate stenosis,<sup>4</sup> while surgical treatment and percutaneous transvenous mitral commissurotomy (PTMC) is indicated in severe mitral stenosis.<sup>5,6</sup> The role of PTMC in the management of patients with rheumatic mitral stenosis has continued to evolve during the last two decades.

### Authors' Information:

1. Dr. Syed Dawood Md. Taimur, Department of Cardiology, Ibrahim Cardiac Hospital & Research Institute, 122, Kazi Nazrul Islam Avenue, Shahbag, Dhaka.
2. Dr. Md. Rezaul Karim, MBBS (DU), D-Card (London), Associate Professor and Consultant, ICHRI, Dhaka.
3. Professor M Maksumul Haq, MBBS, FCPS, FRCP, FACC, Professor & Head of the Department, Cardiology Department, ICHRI, Dhaka.
4. Professor Md Liaquat Ali, MBBS, MRCP, Professor and Sr. Consultant, ICHRI, Dhaka.
5. Dr. Mahbub Mansur, MBBS, MD (Card), Associate Professor & Senior Consultant, Chief Cardiologist, Ibn Sina Specialized Hospital.
6. Dr. Mashhud Zia Chowdhury, MBBS, DTCD, MD (Card), Associate Professor and Consultant, Ibrahim Cardiac Hospital & Research Institute, Dhaka.
7. Dr. Saidur Rahman Khan, MBBS, MD, Ph.D, Associate Professor and Consultant, ICHRI, Dhaka.

**Correspondence:** Dr. Syed Dawood Md. Taimur, Department of Cardiology, Ibrahim Cardiac Hospital & Research Institute, 122, Kazi Nazrul Islam Avenue, Shahbag, Dhaka-1000, Mobile: +8801712801515, Email: sdmtaimur@gmail.com.

Patients selection is fundamental in predicting the immediate results of PTMC.<sup>7</sup> The evaluation and selection of candidates for PTMC require a precise assessment of mitral valve morphology.<sup>7,8</sup> The Echocardiographic score is presently the most widely used technique for the evaluation of morphological characteristics of the mitral valve.<sup>9</sup> Immediate, short and long-term follow-up studies have shown that patients with echo score  $\leq 8$  have superior immediate results and significantly greater survival and freedom from combined events than patients with echo score  $> 8$ .<sup>10</sup> In Bangladesh few studies have been carried out in different centres on PTMC in patients with severe mitral stenosis.<sup>11-13</sup> We designed this study to describe the in-hospital clinical, echocardiographic and interventional outcome of PTMC in patients of moderate to severe mitral stenosis at the Department of Cardiology, Ibrahim Cardiac Hospital & Research Institute (ICHRI), Dhaka.

### Material and Methods

This retrospective observational study was carried out in the Department of Cardiology, Ibrahim Cardiac Hospital & Research Institute (ICHRI), Dhaka, Bangladesh between April, 2008 and April, 2010 on 61 patients of symptomatic mitral stenosis who underwent PTMC. The study commenced after obtaining consent from the patients (if they were 18 or  $> 18$  years old) or from their legal guardians (if they were minor) and Ethical Clearance from the concerned authority. Patients of either sex, up to the age of 60 years having symptomatic mitral stenosis with mitral valve area  $< 1.5 \text{ cm}^2$  and total echocardiographic score  $< 10$  were included in the study. Patients with re-stenosis after closed mitral commissurotomy having favourable mitral valve morphology were also included. Patients having mitral stenosis with mitral regurgitation grade II, having other significant valve lesions requiring surgical treatment, or evidence of left atrial thrombus, congenital heart diseases, e.g. atrial septal defect (ASD), or patients having contraindication to transseptal puncture, e.g. very thick IAS, aneurysm of inter atrial septum, etc. or patients with significant renal impairment were excluded from the study.

**Procedure:** PTMC was done with all aseptic precaution through femoral venous approach under local anaesthesia. Pressure in aorta, left ventricle (LV) and pulmonary artery (PA) was recorded, and LA/LV gradient was calculated. A simple balloon sizing method, based on body height, for selection of appropriate sized balloon catheter was determined using following formula.

$$\text{Balloon size (mm)} = \frac{\text{Height (cm)}}{10} + 10$$

**Post-procedural evaluation:** 2-D, M-mode, PW, CW Doppler and color flow imaging were done to calculate the mitral valvular area, peak pressure gradient (PPG), mean pressure gradient (MPG) and pulmonary arterial systolic pressure (PASP) before PTMC. Measurements on same variables were taken 24 hours after PTMC to observe the changes in those variables. Successful procedures was defined as increase in mitral valve area (MVA)  $> 1.5 \text{ cm}^2$  or  $> 50\%$  increase in pre-procedural MVA. Complications like cardiac tamponade, mitral regurgitation, CVA and acute pulmonary oedema were recorded.

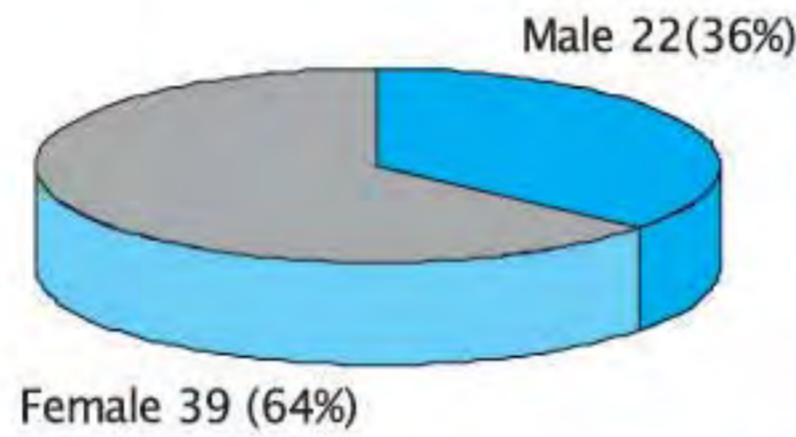
### Results

About one-third (32.8%) of the patients was 40 – 50 years old followed by 24.6% 30 – 40 years and 23.1% 20 – 30 years old. Over 10% of the patients were  $> 50$  years and 8.2%  $< 20$  years old. A female predominance was observed in the series with female to male ratio being roughly 2:1. About 64% of the patients were categorized as NYHA functional Class-III, 14.8% Class-II, 13.1% Class-I and 8.2% Class-IV (Fig. 3). Changes in echocardiographic variables are illustrated in table II. Mitral valvular area was significantly increased following PTMC ( $0.83 \pm 0.15$  vs.  $2.02 \pm 1.06 \text{ cm}^2$ ,  $p < 0.001$ ). The PPG, MPG and PASP were observed to be significantly reduced from their pre-PTMC state ( $26.8 \pm 6.4$  vs.  $8.9 \pm 3.1$  mm Hg,  $p < 0.00$ ;  $15.1 \pm 3.9$  vs.  $4.0 \pm 1.5$  mm Hg,  $p < 0.001$ ;  $60.0 \pm 21.0$  vs.  $38.7 \pm 9.5$  mm Hg,  $p < 0.001$ ) (Table II). Of the 61 patients one died during the procedure. Emergency mitral valve replacement (MVR) was required in 1(0.5%) case and pericardial tamponade occurred in 1(0.5%) case. Thus successful outcome was found in 58(95%) cases (Table III).

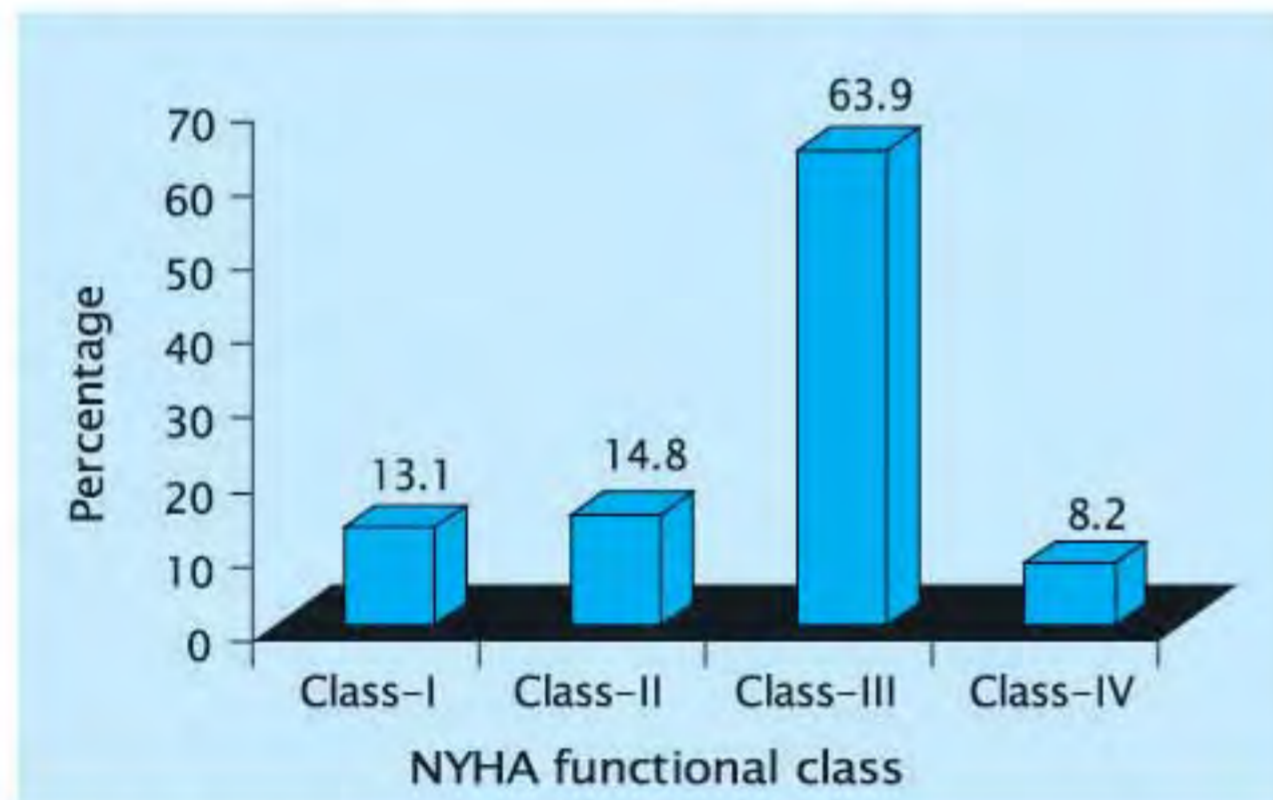
**Table-I. Age distribution of study patients (n=61)**

Age (yrs)*	Frequency	Percentage
< 20	05	8.2
20 – 30	14	23.1
30 – 40	15	24.6
40 – 50	20	32.8
≥ 50	07	11.5

\*Mean±SD=35.2±11.6 years; range = 17–60 years.



**Fig. 1: Distribution of patients by their gender.**

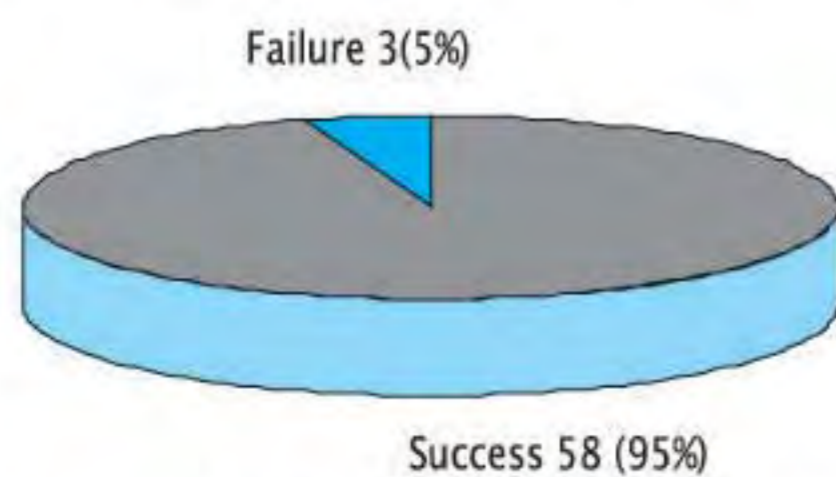


**Fig. 2: Distribution of patients by NYHA functional class.**

**Table-II. Changes in echocardiographic variables following PTMC.**

Variables*	Group		p-value
	Before PTMC (n = 60)	After PTMC (n = 60)	
MVA (cm <sup>2</sup> )	0.83 ± 0.15	2.0 ± 1.0	< 0.001
PPG (mmHg)	26.8 ± 6.4	8.9 ± 3.1	< 0.001
MPG (mmHg)	15.1 ± 3.9	4.0 ± 1.5	< 0.001
PASP (mmHg)	60.0 ± 21.0	38.7 ± 9.5	< 0.001

\*Data were analysed using Paired-sample t-Test and were presented as mean±SD.



**Fig. 3: Distribution of patients by success of PTMC (n = 61).**

**Table-III. Complications developed following PTMC**

Variables	Frequency	Percentage
MVR	01	1.7
Cardiac tamponade	01	1.7
Mortality	01	1.7

**Discussion**

Mitral stenosis is one of the commonest long-term complications of rheumatic fever<sup>1</sup> and approximately 25% of all patients with rheumatic heart disease have pure mitral stenosis.<sup>2</sup> The role of PTMC in the management of patients with rheumatic mitral stenosis has continued to evolve.

In our study procedural success rate was 95% in patients undergoing percutaneous mitral balloon valvuloplasty (PMBV) in our center due to symptomatic moderate-to-severe MS. In three cases in whom the procedure failed, MVA was lower and the frequency of moderate-severe tricuspid regurgitation was significantly higher before the procedure.

Percutaneous mitral balloon valvuloplasty draws our attention as a standard treatment for moderate-severe MS patients with symptomatic or significant pulmonary hypertension. In short-term and long-term success, surgery has demonstrated results to be comparable to closed commissurotomy.<sup>14</sup> However, successful outcome lies in appropriate patient selection, experience of the center and of physicians performing the procedure. In the studies performed, the factors affecting immediate success of the procedure include age, pre-procedural MVA and Wilkins score.<sup>15-18</sup>

Previously, PTMC had been performed only in patients with pliable, non-calcified valves.<sup>14</sup> Although Wilkins score has the impact on PTMC results, it does not predict the results alone.<sup>19</sup> In previous studies, many patients who had been excluded as worse candidates for PTMC based on Wilkins score today undergo PTMC with commendable success rates.<sup>20</sup>

The complication rates are lower in PTMC with Inoue balloon catheter than the use of double-balloon catheter.<sup>21</sup> Inoue balloon procedure was

undertaken in all patients in our center. In several studies, acute complications have been reported at rates ranging from 1–2% such as cerebrovascular events induced by the procedure, cardiac tamponade and procedure-related death.<sup>22</sup> These complications were encountered even in studies from which patients especially with Wilkins score above 8 had been excluded.<sup>15,16</sup> Although in the present study, all patients had Wilkins score above 8, these complications were not observed in any patients except one. We ascribe this success to performance of the procedure by experienced physicians in our center and we think that the experience of the operator is, perhaps, even more important than the selection of patients.

A similar situation applies to the development of severe MR after the procedure. Though the rate of severe MR was reported to be 8.2%<sup>23</sup> in a center, only 1(1.7%) patient developed grade 3–4 MR in our study. The most important reason for the development of severe MR after percutaneous mitral balloon valvuloplasty is mitral leaflets' or of cords' tears.<sup>24,25</sup> On the other hand, MR seen after PMBV does not often cause serious clinical symptoms. In some studies, it was observed that almost in half of the patients MR decreased or disappeared completely within a few months.<sup>24,25</sup> The most likely causes of reversible MR include stretching of the mitral annulus during the procedure, a decrease of leaflet coaptation or papillary muscle ischemia.<sup>26</sup> Therefore, surgical decision for patients who develop MR after the procedure but without worsening heart failure should be considered after observing the patient for a while.

### Study Limitations

The most important limitation of the study is that it is a retrospective study. All data of patients were collected from in-hospital file records. Older patients were excluded from the study either for their co-morbidity or denial of the procedure. As a result, outcome of the procedure could not be assessed in the elderly patients (more than 60 years old).

### Conclusion

PTMC is a treatment option with excellent results in the treatment of moderate to severe MS especially when performed by experienced operators. It can be comparable to surgery with regard to its event-free survival even in the long-term. However, to determine its exact place against surgery prospective randomized controlled trials will be more valuable.

### References

1. Olson LJ, Subramanian R, Ackermann DM. Surgical pathology of the mitral valve: a study of 712 cases spanning 21 years. *Mayo Clin Proc* 1987; 62: 22–7.
2. Delahaye F, Delahaye J, Echocard R. Influence of associated valvular lesions on long-term prognosis of mitral stenosis: a 20 years followup of 202 patients. *Eur Heart J* 1991; 12(Suppl B): 77–82.
3. Bonow RO, Carabello B, de Leon AC Jr. ACC/AHA guidelines for the management of patients with valvular heart disease. *J Am Coll Cardiol*. 1998; 32: 1486–1588.
4. Fuster V, Ryden LE, Asinger RW. ACC/AHA/ESC guidelines for the management of patients with atrial fibrillation. *J Am Coll Cardiol*. 2001; 38: 1231–65.
5. Hammermeister K, Sethi GK, Henderson WG. Outcomes 15 years after valve replacement with a mechanical vs. bioprosthetic valve: final report of the VA randomized trial. *J Am Coll Cardiol*. 2000; 36: 1152–8.
6. Palacios IF, Sanchez PL, Harrell LC. Which patients benefit from percutaneous mitral balloon valvuloplasty? Prevalvuloplasty and postvalvuloplasty variables that predict long-term outcome. *Circulation*. 2002; 105:1465–71.
7. Inoue K, Okawi T, Nakamura T, Kitamura F, Miyamoto N. Clinical application of transvenous mitral commissurotomy by a new balloon catheter. *J Thorac Cardiovasc Surg* 1984; 87: 394–402.
8. Cheng TO, Holmes DR Jr. Percutaneous balloon mitral valvuloplasty by the Inoue balloon technique: the procedure of choice for treatment of mitral stenosis. *Am J Cardiol*. 1998; 81: 624–8.
9. Trevino AJ, Ibarra M, Garcia A, Uribe A, de la Fuente F, Bonfil MA, et al. Immediate and long-term results of balloon mitral commissurotomy for rheumatic mitral stenosis: comparison between Inoue and double balloon techniques. *Am Heart J* 1996; 131: 530–6.
10. Stenfanadis CI, Stratos CG, Lambron SG. Retrograde nontransseptal balloon mitral valvuloplasty: immediate results and intermediate long-term outcome in 441 cases. A multicenter experience. *J Am Coll Cardiol*. 1998; 32: 1009–16.

11. Kabir MS, Majumder AS, Bari MS, Chowdhury AW, et al. Echo Scoring Involving the Individual Parameter without Total Echo Scoring may be the Determining Factor for the Immediate Outcome of the Results of Percutaneous Transluminal Mitral Commissurotomy. *Dinajpur Med Col J* 2009 Jan; 2 (1): 17–22.
12. NAM Momenuzzaman, F Begum, F Malik, N Ahmed, et al. Long term results after successful mitral balloon valvoplasty—experience of 1033 patients. *Bangladesh J Cardiology*; 1(3): 194–200.
13. M Rahman, APM Sohrabuzzaman, SDM Taimur, et al. Value of parial echocardiographic score in prediction of mitral regurgitation during Balloon mitral valvuloplasty. *Bangladesh J Cardiology*; 1(2): 110–5.
14. Fawzy ME, Mimish L, Sivanandam V, Lingamanaicker J, al-Amri M, Khan B, et al. Advantage of Inoue balloon catheter in mitral balloon valvotomy: experience with 220 consecutive patients. *Cathet Cardiovasc Diagn* 1996; 38: 9–14.
15. Vahanian A, Michel PL, Cormier B, Vitoux B, Michel X, Slama M, et al. Results of percutaneous mitral commissurotomy in 200 patients. *Am J Cardiol* 1989; 63: 847–52.
16. Abascal VM, Wilkins GT, O'Shea JP, Choong CY, Palacios IF, Thomas JD, et al. Prediction of successful outcome in 130 patients undergoing percutaneous balloon mitral valvotomy. *Circulation* 1990; 82: 448–56.
17. Multicenter experience with balloon mitral commissurotomy. NHLBI Balloon Valvuloplasty Registry Report on immediate and 30– day follow-up results. The National Heart, Lung, and Blood Institute Balloon Valvuloplasty Registry Participants. *Circulation* 1992; 85: 448–61.
18. Inoue K, Owaki T, Nakamura T, Kitamura F, Miyamoto N. Clinical application of transvenous mitral commissurotomy by a new balloon catheter. *J Thorac Cardiovasc Surg* 1984; 87: 394–402.
19. Trevino AJ, Ibarra M, Garcia A, Uribe A, de la Fuente F, Bonfil MA, et al. Immediate and long-term results of balloon mitral commissurotomy for rheumatic mitral stenosis: comparison between Inoue and double-balloon techniques. *Am Heart J* 1996; 131: 530–6.
20. Hernandez R, Bañuelos C, Alfonso F, Goicolea J, Fernández-Ortiz A, Escaned J, et al. Long-term clinical and echocardiographic followup after percutaneous mitral valvuloplasty with the Inoue balloon. *Circulation* 1999; 99: 1580–6.
21. Fawzy ME, Mimish L, Sivanandam V, Lingamanaicker J, al-Amri M, Khan B, et al. Advantage of Inoue balloon catheter in mitral balloon valvotomy: experience with 220 consecutive patients. *Cathet Cardiovasc Diagn* 1996; 38: 9–14.
22. Fawzy ME, Ribeiro PA, Dunn B, Galal O, Muthusamy R, Shaikh A, et al. Percutaneous mitral valvotomy with the Inoue balloon catheter in children and adults: immediate results and early follow-up. *Am Heart J* 1992; 123: 462–465.
23. Chmielak Z, Kruk M, Demkow M, K?opotowski M, Konka M, Ruzy??o W. Long-term follow-up of patients with percutaneous mitral commissurotomy. *Kardiol Pol* 2008; 66: 525–530.
24. Essop MR, Wisenbaugh T, Skoularigis J, Middlemost S, Sareli P. Mitral regurgitation following mitral balloon valvotomy. Differing mechanisms for severe versus mild-to-moderate lesions. *Circulation* 1991; 84: 1669–1679.
25. Kaul UA, Singh S, Kalra GS, Nair M, Mohan JC, Nigam M, et al. Mitral regurgitation following percutaneous transvenous mitral commissurotomy: a single-center experience. *J Heart Valve Dis* 2000; 9: 262–266.
26. Krishnamoorthy KM, Radhakrishnan S, Shrivastava S. Natural history and predictors of moderate mitral regurgitation following balloon mitral valvuloplasty using Inoue balloon. *Int J Cardiol* 2003; 87: 31–36.