

REVIEW ARTICLE

Tricuspid Valve Replacement on Beating Heart with a Bioprosthetic Valve: A case report

Rahman MZ¹, Biswas SK², Sharifuzzaman M³, Ahmed F⁴

ABSTRACT

Background: We report a successful surgical replacement of tricuspid valve with a bioprosthetic valve in a 45-year-old patient with severe tricuspid valve regurgitation. Septal leaflet of tricuspid valve was not significantly displaced toward RV apex and was tethered to IVS, posterior leaflet was found normal and anterior leaflet with a cleft causing severe TR; RA and RV were dilated and there were no associated cardiovascular anomalies and the coronary arteries appeared normal. The operation consisted of tricuspid valve replacement with a bioprosthetic valve in the heart beating under cardiopulmonary bypass. The postoperative echocardiogram showed no TV regurgitation, AV dissociation did not occur. The postoperative course was uneventful and the patient was discharged on the 10th postoperative day. We consider this procedure to be widely applicable in consideration of the favorable results obtained after surgical treatment.

Key words: Heart failure, tricuspid regurgitation, valve replacement

Introduction

The tricuspid valve is often considered in the workup of heart failure only after more prominent cardiac pathologies such as aortic, mitral, and coronary atherosclerotic disease have been discussed and as such it has been referred to as the 'forgotten valve.' The sequelae of tricuspid regurgitation can be significant however and include ascites, hepatosplenomegaly, pleural effusions, and peripheral edema. Tricuspid regurgitation is usually secondary to left-sided valvular pathology (commonly the mitral valve) causing elevated pulmonary pressures with subsequent dilation of the tricuspid annulus. Rheumatic disease, Ebstein's anomaly, and endocarditis are other important causes of tricuspid incompetence. When significant tricuspid incompetence exists, that we do not feel, will resolve after left-sided reparative procedures. Our preference is to repair the valve with a formal ring annuloplasty. If valve repair is not possible, then valve replacement is necessary.

Case Report

A 45-year-old man with a tricuspid valve anomaly and severe tricuspid valve (TV) regurgitation was referred to our hospital with dyspnea on effort and palpitation which was graded as New York Heart Association (NYHA) functional class grade III. The patient remained mild to moderately symptomatic until referral. He had been treated with a diuretic for one year previous to surgery. A grade III/IV systolic ejection murmur was present along the left sternal border at 3-4th intercostals space. In chest radiograph the cardiothoracic ratio was 0.54. The electrocardiogram revealed fast ventricular rate with atrial fibrillation. Laboratory tests revealed no remarkable changes.

The echocardiogram revealed that septal leaflet of tricuspid valve was not significantly displaced toward RV apex and was tethered to IVS, posterior leaflet was found normal and anterior leaflet with a cleft causing severe TR, dilated RA and RV and no PFO (Fig. 1). Angiocardiograms found no associated cardiovascular anomalies and the coronary arteries appeared normal.

Authors' Information:

1. **Rahman MZ, MS**, Registrar, Department of Cardiac Surgery, National Heart Foundation Hospital & Research Institute.
2. **Biswas SK, MS**, Assistant Professor and Consultant, Department of Cardiac Surgery, National Heart Foundation Hospital & Research Institute.
3. **Sharifuzzaman M, MS**, Associate Professor and Senior Consultant, Department of Cardiac Surgery, National Heart Foundation Hospital & Research Institute.
4. **Ahmed F, MS**, Head & Professor, Department of Cardiac Surgery, National Heart Foundation Hospital & Research Institute, Mirpur, Dhaka.

Correspondence: Mizanur Rahman, E-mail: mz.rahman75@yahoo.com)

A standard anesthetic for cardiac procedures was utilized. A central venous catheter was placed via the right internal jugular vein. Aortic and bi-caval cannulation was accomplished with direct cannulation of the superior vena cava (SVC) and inferior vena cava (IVC). We utilized vacuum assistance up to -40 mmHg as it allows for smaller cannulae. Drainage was adequate using a 24 Fr wire wrapped right angle cannula in the SVC and a 26 Fr wire wrapped right angle cannula in the IVC. There was no patent foramen ovale and we performed tricuspid procedure with the heart beating and perfused after all other aspects of the case requiring aortic crossclamping had been performed. Caval tapes were snared around the IVC and SVC to achieve right heart isolation.

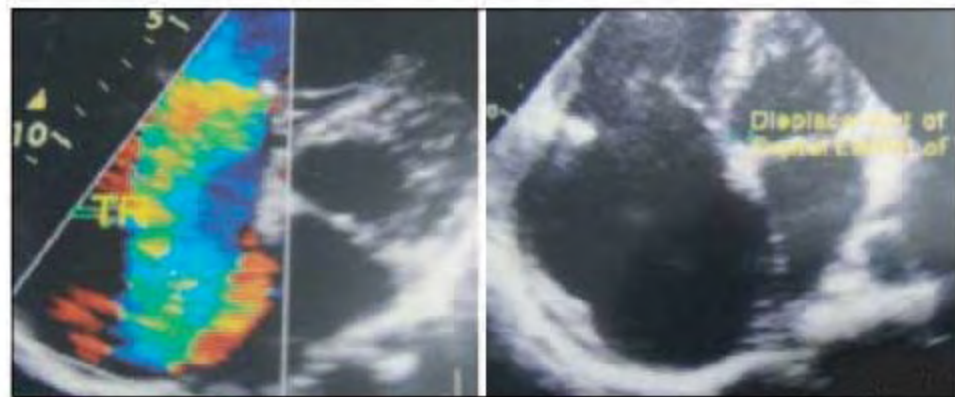


Fig. 1: Septal leaflet of tricuspid valve was displaced causing severe TR, dilated RA and RV.

An oblique right atriotomy was performed down to the IVC cannula, incorporating any existing retrograde catheter site. The foramen ovale was examined to ensure it was closed. Pledged traction sutures were placed on the edges of the

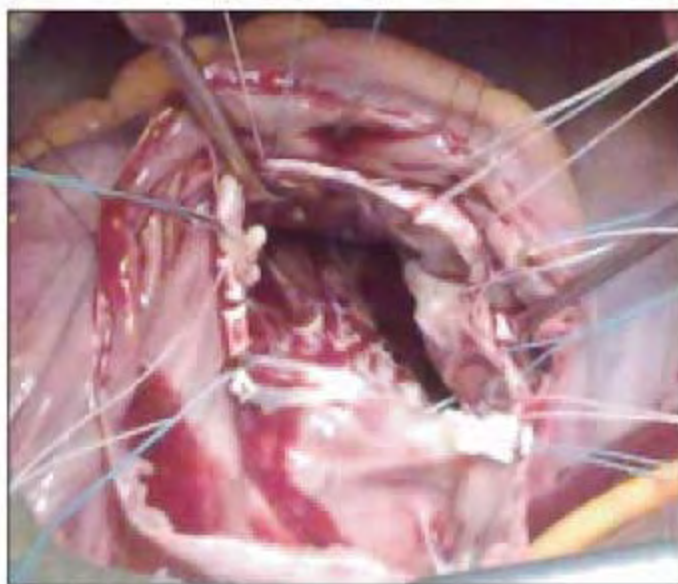


Fig. 2: Ticron sutures were placed.

atriotomy to enhance exposure. A flexible weighted vent is placed in the coronary sinus. The tricuspid valve was inspected and an assessment of repair versus replacement was made. When repair was not feasible, our preference

was to use a bioprosthetic bovine pericardial valve. The leaflets were left in place to preserve the sub-valvular apparatus. Everting 2-0 pledgeted Ticron sutures were placed along the circumference of the annulus from the atrial to the ventricular side of the valve (Fig. 2), starting at the anterior leaflet and working clockwise. Great care was taken when suturing near the AV node along the septal leaflet.

After proper sizing, we put the 29 sized mitral bioprosthetic valve. From the surgeons view, the valve posts lied at the 12, 4 and 8 o'clock positions. The valve was seated and the sutures were secured starting at the septal leaflet (Fig. 3). The atriotomy was closed with 5-0 polypropylene sutures in one layer after de-airing maneuvers. The caval tapes were released and the patient was weaned from cardiopulmonary bypass. It is our practice to place epicardial pacing wires on all patients receiving a tricuspid valve replacement. Temporary epicardial pacing wires were placed in all patients given the higher incidence of transient conduction disturbances in the post-operative period following tricuspid procedures.

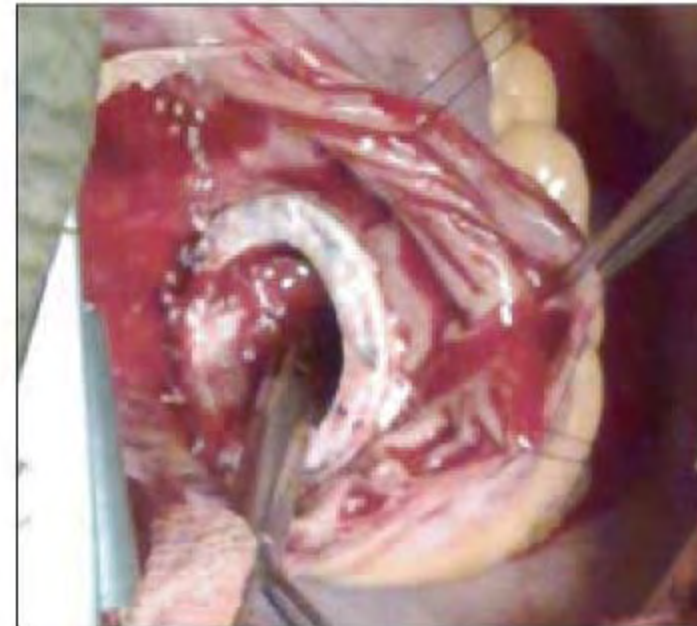

Fig. 3: The valve was seated.

The postoperative echocardiogram showed no TV regurgitation, and AV dissociation did not occur. The postoperative course was uneventful and the patient was discharged on the 10th postoperative day.

Discussion

Tricuspid regurgitation secondary to endocarditis, rheumatic heart disease or congenital anomalies is best treated by valve replacement. In the setting of functional TR, it is our preference to repair the valve with a ring annuloplasty when possible.

Risk factors for failure of tricuspid repair include a preoperative tricuspid regurgitation score of 3+ or 4+, left ventricular ejection fraction of <35%, and the need for permanent pacing.¹ In these settings we will consider primary tricuspid valve replacement for functional TR.

The technical aspects of tricuspid valve replacement are straightforward, and the procedure can be performed on the beating heart as well. Injury to the conduction system is a surgical pitfall that can be avoided by cautious placement of sutures in the region of the A-V node. Some groups prefer a supra-annular implantation of prosthetic valves which leaves the coronary sinus and A-V node on the ventricular side of the valve so as to distance their sutures from the conduction system.² There is a potential risk of damage to the prosthetic valve leaflets by the pulmonary artery catheter if replaced through the valve, however, we did not find this to be a clinical problem when we used CVP catheter in place of pulmonary artery catheter in our practice.

The prophylactic placement of epicardial pacing leads in all patients may be seen as unnecessary treatment in patients who are in sinus rhythm after the procedure. However, we have had such patients ultimately develop a need for permanent pacing later in the post-operative course. Our strategy should therefore to place epicardial leads in all patients receiving a tricuspid valve. Doing so avoids pacing wires crossing the prosthetic valve, which we believe leads to improved durability of the valve.

Replacement of the tricuspid valve is a relatively infrequent procedure in most cardiac surgery practices. While not technically demanding, management of such patients has proved challenging as evidenced by high short- and long-term mortality rates. Contemporary and historical series have reported 30-day mortality rates in excess of 20%, and a 10-year survival of roughly 40–50%.^{3–5} Risk factors that have been identified for operative mortality include emergent status, advanced age, and elevated pulmonary arterial pressures. Rheumatic or organic etiology of tricuspid valve disease is the main risk factor for late death as the disease process continues even after replacement.⁵

Whether to replace the tricuspid valve with a mechanical or bioprosthetic valve remains a subject of debate. Bioprosthetic valve advocates point to the thrombosis rate of mechanical valves in the tricuspid position of 10–25%, and the bleeding complications of anticoagulation.⁶ Neither valve type, however, has been shown to be a critical risk factor for short or long-term death.^{3,7–9} It is our practice to implant bioprosthetic valve in the tricuspid position, even in young patients. We feel the durability is reasonable and the risk of thrombosis and bleeding outweigh the risk of redo heart surgery when needed in this population.

Conclusion

Successful surgical replacement of tricuspid valve with a bioprosthetic valve without arresting the heart in a 45-year-old male may be feasible.

References

1. McCarthy PM, Bhudia SK, Rajeswaran J, Hoercher KJ, Lytle BW, Cosgrove DM, Blackstone EH. Tricuspid valve repair: durability and risk factors for failure. *J Thorac Cardiovasc Surg* 2004; 127: 674–85.
2. Ohata T, Kigawa I, Yamashita Y, Wanibuchi Y. Surgical strategy for severe tricuspid valveregurgitation complicated by advanced mitral valve disease: long-term outcome of tricuspid valvesupra-annular implantation in eighty-eight cases. *J Thorac Cardiovasc Surg* 2000; 120: 280–3.
3. Carrier M, Hébert Y, Pellerin M, Bouchard D, Perrault LP, Cartier R, Basmajian A, Pagé P, Poirier NC. Tricuspid valvreplacement: an analysis of 25 years of experience at a single center. *Ann Thorac Surg* 2003; 75: 47–50.
4. Filsoufi F, Anyanwu AC, Salzberg SP, Frankel T, Cohn LH, Adams DH. Long-term outcomes of tricuspid valvreplacement in the current era. *Ann Thorac Surg* 2005; 80: 845–50.
5. Iscan ZH, Vural KM, Bahar I, Mavioglu L, Saritas A. What to expect after tricuspid valve replacement? Long-term results. *Eur J Cardiothorac Surg* 2007 32: 296–300.
6. Kawano H, Oda T, Fukunaga S, Tayama E, Kawara T, Oryoji A, Aoyagi S. Tricuspid valve replacement with the St. Jude Medical valve: 19 years of experience. *Eur J Cardiothoracic Surg* 2000; 18: 565–9.
7. Rizzoli G, De Perini L, Bottio T, Minutolo G, Thiene G, Casarotto D. Prosthetic replacement of the tricuspid valve: biological or mechanical? *Ann Thorac Surg* 1998; 66: S62–S67.
8. Rizzoli G, Vendramin I, Nesseris G, Bottio T, Guglielmi C, Schiavon L. Biological or mechanical prostheses in tricuspidposition? a meta-analysis of intra-institutional results. *Ann Thorac Surg* 2004; 77: 1607–14.
9. Kaplan M, Kut MS, Demirtas MM, Cimen S, Ozler A. Prosthetic replacement of tricuspid valve: bioprosthetic or mechanical. *Ann Thorac Surg* 2002; 73: 467–73.