

# Primary Hemiarthroplasty for Per and Intertrochanteric Femur Fractures in Elderly Patients: Our Experience in BIRDEM General Hospital

Jonaed Hakim<sup>1</sup>, Afrina Jahan<sup>2</sup>, MKI Quayyum Choudhury<sup>3</sup>, M Zawad<sup>4</sup>, Rayhan Ali Mollah<sup>5</sup>

## ABSTRACT

**Background & objective:** Intertrochanteric fractures are becoming increasingly common as our population ages. These fractures typically occur in frail patients with multiple comorbidities. The morbidity associated with the fracture can be minimized by choosing appropriate fixation device for the fracture pattern, recognizing the stability of fixation, and performing accurate reduction with ideal implant placement. So, these fractures should be treated expeditiously so that there are minimum fixation failures. In BIRDEM hospital a large number of elderly patients having intertrochanteric femur fractures with multiple comorbidities, are treated by primary hemiarthroplasty. The purpose of this study is to see the clinical outcome of these hemiarthroplasty patients.

**Methods:** This retrospective study was carried out over four years from 2015 to 2019 on 60 patients (42 females and 18 males). All patients had diabetes in common along with other co-morbidities like ischaemic heart disease, hypertension, chronic kidney disease and stroke. The outcome was evaluated by applying Harris Hip Score after intervention.

**Result:** The mean age of the patients was 65.5 years (range: 60-85 years) with male to female ration being 3:7. The mean Harris Hip score at the four-year follow-up was  $83.1 \pm 10.9$ . A total of 12(20%) patients were graded as excellent, 30(50%) patients as good, 15(25%) as fair and 3(5%) as poor. It was observed that, patients with AO (Arbeitsgemeinschaft für Osteosynthesefragen) type 31A1 intertrochanteric fractures had better outcome than AO type 31A2 and 31A3 in our study.

**Conclusion:** Primary hemiarthroplasty can provide a stable, pain-free, mobile joint with acceptable complication rates. These fractures must be treated considering patient's age, bone quality and type of the fracture.

**Key words:** Intertrochanteric femur fractures, elderly patients, hemiarthroplasty, bone cement, cerclage wiring, Harris Hip Score (HHS) etc.

## INTRODUCTION:

Intertrochanteric hip fractures are major causes of disability and death in the elderly. The incidence of all hip fractures is approximately 80 per 100,000 persons and expected to be double over the next 50

years as the number of aged population increases. Intertrochanteric fractures make up 45% of all hip fractures.<sup>1</sup> Intertrochanteric fractures occurring as consequences of low-energy falls are common and are frequently seen in elderly patients.<sup>2</sup> A truly stable

## Author's information:

<sup>1</sup> **Dr. Jonaed Hakim**, Junior Consultant, Department of Orthopaedics & Traumatology, BIRDEM (Bangladesh Institute of Research and Rehabilitation in Diabetes, Endocrine and Metabolic Disorders) General Hospital & Ibrahim Medical College, 122, Kazi Nazrul Islam Avenue, Dhaka-1000, Bangladesh.

<sup>2</sup> **Dr. Afrina Jahan**, Registrar, Department of Orthopaedics & Traumatology, BIRDEM General Hospital & Ibrahim Medical College, 122, Kazi Nazrul Islam Avenue, Dhaka-1000, Bangladesh.

<sup>3</sup> **Prof. MKI Quayyum Choudhury**, Professor & Head, Department of Orthopaedics & Traumatology, BIRDEM General Hospital & Ibrahim Medical College, Dhaka.

<sup>4</sup> **Dr. M. Zawad**, Resident Medical Officer, Department of Orthopaedics & Traumatology, BIRDEM General Hospital & Ibrahim Medical College, Dhaka.

<sup>5</sup> **Dr. Rayhan Ali Mollah**, Resident Medical Officer, Department of Orthopaedics & Traumatology, BIRDEM General Hospital & Ibrahim Medical College, Dhaka.

**Correspondence:** Dr. Jonaed Hakim, Phone: +880 1975701631 E-mail: hakimjonaed@gmail.com

intertrochanteric fracture is one, which when reduced, has a cortical contact without a gap medially and posteriorly. Whereas in unstable intertrochanteric fracture there is comminution of greater trochanter and there is no contact between proximal and distal fragment because of displaced posteromedial fragment. The size lesser trochanter fragment, its size and degree of displacement are key to decide the instability of intertrochanteric fracture.<sup>3</sup>

Appropriate treatment method for intertrochanteric fracture, particularly in elderly people, is rather controversial because of the poor quality of bone mass, accompanying systemic disorders and discordancy of these patients.<sup>4</sup> Rigid internal fixation and early mobilization are the vital points of the treatment.<sup>5</sup> Trochanteric sliding plate fixation (Dynamic Hip Screw), intramedullary nailing, methyl-methacrylate or absorbable ceramic application and proximal femoral osteotomies are the recently used treatment modalities. But these options are not commonly accepted, because of the inadequate stabilization, shortening of the leg and abductor weakness after treatment.<sup>6</sup> Reported overall failure rate with internal fixation in intertrochanteric fractures ranges from 6-32%.<sup>7</sup> In the elderly, fracture instability, comminution and osteoporosis worsen the prognosis.<sup>8</sup> Moreover, there is a high rate of general complications associated with internal fixation due to prolonged recovery time taken after surgery.<sup>9</sup> Another treatment option for intertrochanteric fracture is endoprosthesis application aiming early mobilization with weight bearing, although it is not the ideal treatment option for stable trochanteric fractures. However, successful outcomes have been reported after the use of hemiarthroplasty and total hip arthroplasty in these patients.<sup>10</sup> After hip arthroplasty, patients can bear weight immediately. They can be encouraged to walk early and exercise the involved limb, which reduces the period of bed rest and rate of complications.<sup>11,12</sup>

While relative consensus exists about the treatment of femoral neck fractures for elderly patients, the optimal treatment for intertrochanteric fractures is still debatable.<sup>13</sup> This study was aimed to evaluate

the outcome of primary hemiarthroplasty by Harris Hip Score in elderly patients with intertrochanteric femur fractures in BIRDEM General Hospital with four years follow-up.

## METHODS:

This retrospective study was done in BIRDEM General Hospital from January 2016 to December 2019. During that period, primary hemiarthroplasty by bipolar hip prosthesis for intertrochanteric femur fractures were done on 280 patients, but clinical outcome was measured in only 60 patients with 35 having right-sided and 25 having left-sided fracture. All patients were community ambulators, with or without walking aids, prior to trauma with any one or more of the co-morbidities like diabetes, hypertension, ischaemic heart disease, stroke and chronic kidney disease.

Hemiarthroplasties were done using an anterolateral approach in lateral decubitus position by a dedicated surgical team under spinal anesthesia. Both stem and long stem with bipolar prosthetic heads were used. Polymethyl methacrylate (PMMA) bone cement was used in 36 cases. Among them 10 cases needed cerclage wiring by stainless steel wire to reconstruct the abductors and to hold the stem in position (Figure:2,3).

Patients were mobilized to a chair on the first postoperative day and then were permitted full weight bearing. During the first two weeks after surgery, patients used an abduction pillow while in bed. A walker was used by the patients for at least six weeks, followed by a cane if the patients had adequate muscle strength and balance. The rehabilitation progressed as tolerated by the patients. Patients were examined post-operatively at 6 weeks, 3 months, 6 months, 1 year, and thereafter annually up to 4-years. At each follow-up visit, a clinico-radiological examination was done and the outcome was evaluated using the Harris Hip Score (HHS) and were graded as poor (HHS < 70), fair (HHS 70-79), good (HHS 80-89) and excellent (HHS 90-100). Anteroposterior radiographs of hip were analyzed at each follow-up to note any evidences of loosening.

**RESULT:**

Of the 60 patients, 18(30%) were male and 42(70%) were female. Majority (86.6%) of the patients was 60 – 70 years old with mean age of the patients being 65.5 ± 5.6 years. Nearly 60% had right-sided involvement (Table:1). The fractures were classified according to AO Classification. Accordingly, 60% patients had class 31A2, 16.7% patients 31A1 and 23.3% 31A3 fractures (Fig. 1). The mean operative time was 110.0 ± 22.6 minutes. Majority (86.7%) of the patients needed single unit blood transfusion in postoperative period. The average length of stay was 8.7 ± 2.1 days (range: 5-14 days).

The median Harris Hip Score at the 4-year follow-up was 83 ± 10. A total of 12(20%) patients were graded as excellent, 30(50%) patients as good, 15(25%) as fair and 3(5%) as poor (Fig. II). At the last follow up (after 4 years), 30(50%) patients were walking without any aid, 8(13.3%) had a limping gait and used a stick to aid in walking, 3(5%) used a walker, and 3(5%) was wheel-chair-bound. Eight (13.3%) patients had an average shortening of 1.1 cm (range: 5-15 mm) which was well-compensated by giving a shoe raise. Nearly 20% (n = 11) had abductor lurch at 3 months follow-up; but only 8(13.3%) patients had abductor muscle weakness with a positive Trendelenberg test at final follow-up. They had to use sticks for walking. 3 patients among fair HHS score, had superficial wound infection. One patient of poor HHS ended in chronic pain and walked with a limp, but we couldn't find any obvious reason for that. In another case, there was dislocation, which was reduced closely under anesthesia and in the last one, there was loosening of uncemented prosthesis, which was treated later with bipolar prosthesis with long stem and augmentation by bone cement. There was one peri-prosthetic fracture in which revision surgery was done with augmenting with bone cement and applying cerclage wire made of stainless steel.

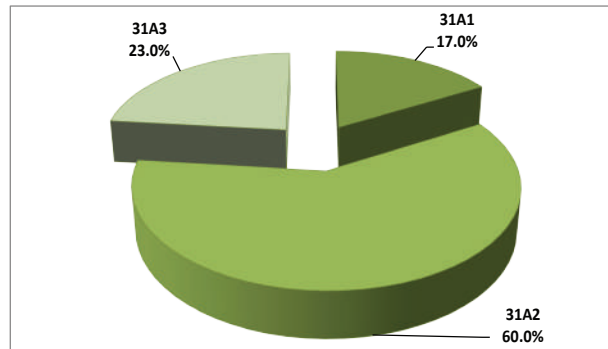
**Table I. Demographic pattern of patients**

Number of Patients	Site involved		Age in years		Sex	
	Right	Left	Range	Mean	Male	Female
60	35	25	60-85	65.5	18	42

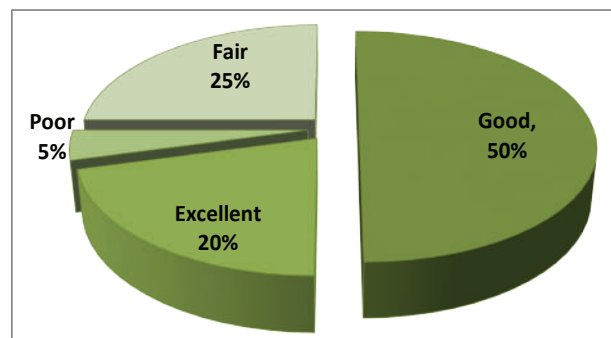
**Table II. Distribution of the study patients by demographic characteristics**

Demographic characteristics	Frequency	Percentage
<b>Age* (years)</b>		
60 – 70	52	86.6
70 – 80	4	6.7
≥ 80	4	6.7
<b>Sex</b>		
Male	18	30.0
Female	42	70.0
<b>Site involve</b>		
Right	35	58.3
Left	25	41.7

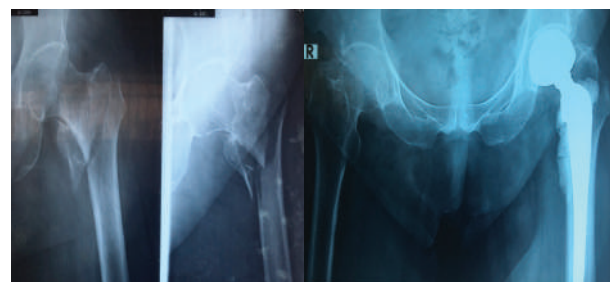\*Mean age = 65.5 ± 5.6 years.



**Figure 1: AO/OTA Classification**



**Figure 2: Final Outcome: Harris Hip Score**



**Fig 3: Pre & Post-Operative X-ray of left-sided Trochanteric Fracture of Femur**

## DISCUSSION:

Open reduction and internal fixation, although used to treat unstable intertrochanteric hip fractures and is familiar to orthopaedic surgeons, it is frequently associated with implant migration, fracture non-union and mal-union. Arthroplasty although, is a less frequently employed alternative, it allows patients immediate full weight bearing. Besides, many of the complications of open reduction and internal fixation could be avoided with this procedure.

Since 1971 hemiarthroplasty has been used for unstable intertrochanteric fractures, however less frequently as compared to femoral neck fractures.<sup>14,15</sup> Tronzo claimed to be the first to use long, straight-stemmed prosthesis for the primary treatment of intertrochanteric fractures.<sup>16</sup> Stem and Goldstein used the Leinbach prosthesis for the primary treatment of 22 intertrochanteric fractures and found early ambulation and early return to the pre-fracture state as definite advantages.<sup>17</sup> Liang and associates<sup>18</sup> in their study of unstable intertrochanteric fractures concluded that hemiarthroplasty is an effective method to treat unstable intertrochanteric fractures in elderly patients. It can decrease complications, reduce morbidity, improve patients' living quality and reduce the burden of the patient's family. Grimsrud and colleagues<sup>1</sup> studied 39 consecutive patients of unstable intertrochanteric fractures treated with a cemented bipolar hip arthroplasty and observed good result. The technique allowed safe and early weight bearing on the injured hip and had a relatively low rate of complications.

In the present study, since majority of the patients was out of bed on the second day postoperatively, and the recumbency time was minimal, there were no chest or urinary tract infection and development of bed sores in our series. Rodop and associates<sup>19</sup> in a study of primary bipolar hemi-prosthesis for unstable intertrochanteric fractures in elderly patients (n = 37) obtained excellent and good results in 45 and 37% cases respectively after 12 months of

intervention using Harris Hip Scoring system as the outcome measure. In our study, over 70% of the patients had good to excellent result suggesting that the modality of treatment we used is promising especially in view of the variable results of osteosynthesis in this cohort of patients.

Although the opponents of the technique stated increased blood loss, mechanical complications like dislocation, and infection as possible complications of the technique as compared to conventional internal fixation, Kayali et al,<sup>20</sup> in a comparative study of primary hemiarthroplasty versus internal fixation, showed clinical outcome of both the groups to be similar. Hemiarthroplasty patients were allowed full weight bearing significantly earlier than the internal fixation patients. Broos and associates<sup>21</sup> concluded that the operative time, blood loss and mortality rates were almost comparable between the two groups. They also found that the patients who received prosthesis for primary treatment, experienced less pain. One patient had dislocation 1 month after the surgery and it was corrected by close method followed by application of abduction bar for 3 weeks with good result. Conflicting reports about postoperative mortality in cases with primary hemiarthroplasty are cited in the literatures. Kesmezacare et al<sup>22</sup> reported postoperative mortality to be 34.2% after a mean treatment of 13 months (range: 1 to 36 months) and to be 48.8% after a mean treatment of 6 months (range: 1 to 24 months) in patients treated with internal fixation and endoprosthesis respectively. In the present study 4(6.7%) patients out of 60 died after three years of surgery due to co-morbidities associated with old age.

The purpose of the treatment of hip fractures in elder population is to prevent complications by providing early mobilization and to help patients in returning to their day-to-day activities. Hemiarthroplasty seems to be an effective treatment for displaced femoral neck fractures in elderly with a lower complication and a lower re-operation rate. Despite excellent outcomes in the literatures, hemiarthroplasty for unstable

intertrochanteric fractures has not been well accepted, probably because the procedure is technically more difficult than that in a femoral neck fracture. Reconstruction of metaphyseal femoral bone fragments and trochanteric reattachment around a femoral component stem involve techniques and skills that are similar to bone grafting methods used in revision total hip arthroplasty.<sup>1</sup> However, in our study, primary hemiarthroplasty showed good functional outcomes with majority of the patients being able to perform their normal activities within a month in spite of their advanced age.

### CONCLUSION:

Primary hemiarthroplasty in elderly patients with intertrochanteric femur fractures does provide a stable, pain-free, mobile joint with minimal complications, provided the intervention is given considering patients' age, various life co-morbidities, bone quality and type of the fracture. We recommend primary hemiarthroplasty to treat intertrochanteric femur fracture for carefully selected elderly patients with multiple comorbidities to avail one stage procedure.

### REFERENCES:

1. Grimsrud C, Monzon RJ, Richman J, Ries MD. Cemented Hip Arthroplasty With a Novel Cerclage Cable Technique for Unstable Intertrochanteric Hip Fractures. *The Journal of Arthroplasty* 2005;20(3).
2. Dhanwal DK, Dennison EM, Harvey NC, Cooper C. Epidemiology of hip fracture: Worldwide geographic variation. *Indian Journal of Orthopaedics* 2011; 45(1): 15-22. doi: 10.4103/0019-5413.73656
3. Babhulkar, SS. Management of trochanteric fractures. *Indian Journal of Orthopaedic* 2006;40(4): 210-218.
4. Sarmiento A, Williams EM. The unstable intertrochanteric fracture: treatment with a valgus osteotomy and I-beam nail-plate. A preliminary report of one hundred cases. *J Bone Joint Surg (Am)* 1970; 52:1390-18.
5. Miller K, Atzenhofer K, Gerber G, Reichel M. Risk prediction in operatively treated fractures of the hip. *Clinical Orthopaedics and Related Research* 1993; (293): 148-52.
6. DeLee J. Fractures and dislocations of the hip. In: Rockwood CA Jr, Green DP, Bucholz RW, Heckman JD, editors. *Rockwood and Green's fractures in adults, Vol 2. 4th ed, Philadelphia: Lippincott-Raven* 1996, p. 659-725.
7. Eastwood EA, Magaziner J, Wang J, Silberzweig SB, Hannan EL, Strauss E. Patients with hip fracture: subgroups and their outcomes. *J Am Geriatr Soc* 2002; 50:1240-9 .
8. White BL, Fisher WD, Laurin CA. Rate of mortality for elderly patients after fracture of the hip in the 1980's. *J Bone Joint Surg* 1987; 69-A: 1335-1340 .
9. Said GS, Farouk O, El-Sayed A, Said HG. Salvage of failed dynamic hip screw fixation of intertrochanteric fractures. *Injury* 2006; 37:194-202 .
10. Baumgaertner MR, Curtin SL, Lindskog DM. Intramedullary versus extramedullary fixation for the treatment of intertrochanteric hip fractures. *Clinical Orthopaedics and Related Research* 1998; 348:87-94 .
11. Faldini C, Grandi G, Romagnoli M, Pagkrati S, Digennaro V, Faldini O, Giannini S. Surgical treatment of unstable intertrochanteric fractures by bipolar hip replacement or total hip replacement in elderly osteoporotic patients. *J of Orthopaedic & Traumatology* 2006; 7(3):117-12.
12. Tronzo RG. The use of an endoprosthesis for severely comminuted trochanteric fractures. *Orthop Clin North Am* 1974;5 (4):679-681 .
13. Davis TR, Sher JL, Horseman A, Simpson M, Portar BB, Checketts RG. Intertrochanteric femoral fractures: Mechanical failure after internal fixation. *J Bone & Joint Surg (Br)* 1990; 72:26-3.
14. Blomfeldt R, Tornkvist H, Ponzer S, Soderqvist A, Tidermark J. Comparison of internal fixation with total hip replacement for displaced femoral neck fractures: Randomized controlled trial performed at four years. *J Bone Joint Surg (Am)* 2005; 87: 1680-1688.
15. Geiger F, Schreiner K, Schneider S, Pauschert R, Thompsen M. Proximal fracture of the femur in elderly patients: the influence of surgical care and patient characteristics on post-operative mortality. *J Bone Joint Surg (Am)* 2006; 35:651-358.
16. Tronzo RG. The use of an endoprosthesis for severely comminuted trochanteric fractures. *Orthop Clinical North Am* 1974; 5(4): 679-681.
17. Stern MB, Goldstein TB. The use of the Leinbach prosthesis in intertrochanteric fractures of the hip. *Clin Orthop Related Research* 1977; 128:325-31.

18. Liang YT, Tang PF, Guo YZ, Tao S, Zhang Q, Liang XD. Clinical research of hemiprosthesis arthroplasty for the treatment of unstable intertrochanteric fractures in elderly patients. *Natl Med J China* 2005; 85: 3260-2.
19. Rodop O, Kiral A, Kaplan H, Akmaz I. Primary bipolar hemiprosthesis for unstable intertrochanteric fractures. *Int Orthop* 2002; 26:233-7 .
20. Kayali C, Agus H, Ozluk S, Sanli C. Treatment for unstable intertrochanteric fractures in elderly patients: internal fixation versus cone hemiarthroplasty. *J Orthop Surg (Hong Kong)* 2006; 14:240-4.
21. Broos PLO, Rommens PM, Deleyn PRJ, Geens VR, Stappaerts KH. Pertrochanteric fractures in the elderly: Are there indications for primary prosthetic replacement? *J Orthop Trauma* 1991; 5:446-51 .
22. Kesmezacar H, Ogüt T, Bilgili MG, Gökay S, Tenekecioglu Y. Treatment of intertrochanteric femur fractures in elderly patients: internal fixation or hemiarthroplasty. *Acta Orthop Traumatol Turc* 2005; 5:423-9.