

VIRILIZATION IN A GIRL WITH ADRENOCORTICAL ADENOMA: A CASE REPORT

Tahniah Haq, S M Ashrafuzzaman and Zafar A Latif

Department of Endocrinology, Bangladesh Institute of Research & Rehabilitation in Diabetes Endocrine and Metabolic Disorders (BIRDEM), Shahbagh, Dhaka, Bangladesh

Abstract

We present a case of Cushing's syndrome and virilization in a 15 year old girl which was suspected to be due to an adrenal carcinoma. She presented with features of virilization in addition to those of hypercortisolism. Her high androgen levels especially dehydroepiandrosterone sulfate (DHEAS) were also in favor of an adrenal carcinoma. An unenhanced computerized tomography (CT) scan showed a mass (size: 5.3 cm) in the right adrenal gland with a soft tissue intensity of more than 10 HU which was suggestive of adrenal carcinoma. But, histopathology of the resected mass revealed a benign adrenocortical adenoma.

Ibrahim Med. Coll. J. 2012; 6(2): 70-72

Key words: Virilization, adrenocortical adenoma.

Introduction

A few cases of adrenal adenoma have been reported with features of virilization.^{1,2} As far as we know, previously no cases of virilizing adrenal adenoma have been reported in Bangladesh. We describe here a case of adrenal adenoma in a young Bangladeshi girl with features of virilization and a high androgen level.

Case presentation

A 15 year old girl was referred to the endocrine hospital for evaluation of secondary amenorrhoea for 2 years. Her menarche started at the age of 13 and was accompanied by thelarche and pubarche. But after a couple of cycles, the regular menstrual cycle stopped and despite several attempts with progesterone, it did not start. She started to notice acne and hirsutism over the last one year. There were painful boils over her legs and breast. The breast abscess was treated surgically. She mentioned a 6kg weight gain over 6 months. On query, she did not mention a deepening of the voice or any change in her physique. There was no muscle weakness or bone pain. Her weight was 58kg,

height 150cm, BMI was 25.7kg/m². She was found hypertensive with a systolic blood pressure of 160 and diastolic of 130 mm of Hg which was controlled with 10mg of amlodipine daily. She had an uneventful neonatal period and reached her milestones in due time. She was born of a consanguineous marriage.

On physical examination, she was noticed to have a round plethoric face with moderate acne and hirsutism. The Ferriman-Gallway score for hirsutism was 1 for upper lip, 4 for chin, 4 for trunk and limbs. There were purple striae over her axillae, abdomen and thigh (Figure 1a). Acanthosis nigricans was present over the axillae. Tanner stage was V for breast and IV for pubic hair. She had clitoromegaly (Figure 1b). No lump was palpable on abdominal examination, but there was tenderness over the right lumbar area. Her blood sugar fasting and after 75g of glucose meal was 5.7mmole/L and 10.5mmole/L respectively. Serum sodium level was 146mmole/L and S. potassium was 3.6mmole/L. All other biochemical and haematological parameters were unremarkable. Chest X-ray and ECG were normal. On March, 2011 endocrine evaluation

Address for Correspondence:

Dr. Tahniah Haq, Department of Endocrinology, BIRDEM, 122 Kazi Nazrul Islam Avenue, Dhaka 1000, Bangladesh, E mail: tahniahhaq@yahoo.com

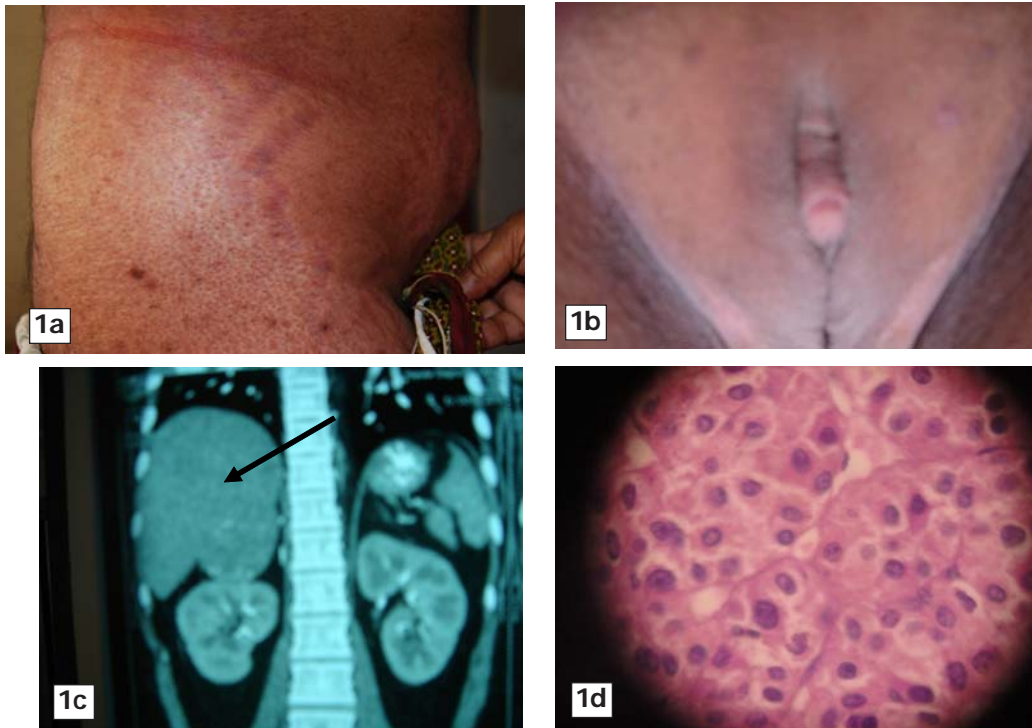


Fig. 1a: Wide, purple striae over lower abdomen, **1b:** Clitoromegaly, **1c:** Contrast CT showing an oval shaped well circumscribed soft tissue density (HU 51) mass measuring about 5.3cm × 4.7cm in the right suprarenal area with minimum contrast enhancement. **1d:** H&E staining of resected tumor showing polygonal cells having round to oval nuclei and abundant eosinophilic cytoplasm.

showed a luteinizing hormone level of 0.64 mIU/ml (normal: 1.1-11.6 mIU/ml), FSH was 0.36mIU/L (2.8-11.3 mIU/ml). Her androgen levels were extremely elevated. Testosterone was 17.05nmol/L (0.89-4.22), dehydroepiandrosterone sulfate (DHEAS) was 458 μ gm/dL (35-430). After 4 months, testosterone level rose even higher to 43.90nmol/L. 17-OH progesterone level was normal (3.92ng/ml). Serum cortisol at 9am was 1303.80nmole/L (116-1065) and at 5pm 1656nmole/L. Twenty four hour urinary cortisol was high (1937.52 nmole/L). Overnight dexamethasone suppression test was done. Next morning cortisol was 1139.84nmole/L. ACTH level was 33.8pg/ml (8.3-57.8). Patient was euthyroid as the FT4 and TSH levels were 10.94pmole/L and 0.91IU/ml respectively. An ultra sonogram (USG) of the whole abdomen did not reveal any abnormality. A repeat USG of abdomen 6 months later detected a hypoechoic mass measuring 5cm × 3.9cm in the right adrenal gland. Left adrenal gland and ovary were normal in appearance. The mass was evaluated further with a computerized tomography (CT) imaging. CT findings showed an oval shaped well circumscribed

soft tissue density (HU 46) mass lesion measuring about 5.3cm × 4.7cm in the right suprarenal area (Figure 1c). After intravenous contrast there was minimum enhancement (HU 51). Flat plane around mass was well preserved. No perilesional structural involvement was seen. Left adrenal gland was normal.

The case was diagnosed as adrenal carcinoma based on high androgen levels especially DHEAS and the presence of a mass (5.3 × 4.7cm) in the right adrenal gland having a soft tissue density of 46HU.

The tumor was resected surgically. A capsulated tumor around 5 × 5 cm in size was resected and sent for histopathological examination. On intraoperative examination there were no enlarged lymph nodes. Histopathological examination of the resected mass revealed a capsulated neoplasm of adrenal gland. The tumor was mostly composed of cells of zona glomerulosa. Tumour cells were polygonal having round to oval nuclei and abundant eosinophilic cytoplasm. A fair number of bizarre nuclei were present. Cells were arranged diffusely in clusters, nests

and trabecular pattern. Mitotic bodies were not present. No necrosis, vascular or capsular invasion was identified. No malignant cells were noted. The final diagnosis was adrenocortical adenoma (Figure 1d).

Following surgery, menstruation started on the first postoperative day. Blood pressure came down to normal and anti-hypertensives drugs were stopped from the first postoperative day. The cushingoid features and hirtutism resolved over 6 months following surgery. The patient was maintained on steroids which was planned to be gradually withdrawn over months.

Discussion

Adrenal virilism is a syndrome in which excessive adrenal androgens cause virilization. Some common causes of adrenal virilization are adrenal carcinoma and congenital adrenal hyperplasia. Adrenocortical carcinomas produce oligomenorrhea and virilization characterized by deepening of the voice, clitoromegaly and hirsutism. High concentration of DHEAS is suggestive of adrenocortical carcinomas. The size of the adrenal mass measured by CT or MRI remains one of the best indicators of malignancy. In the German Adrenal Cancer Registry, the range of malignant tumors size was from 3 to 28 cm. Adrenocortical carcinomas smaller than 6 cm in size have also been reported. Measurement of Hounsfield units (HU) in unenhanced CT is of great value in differentiating malignant from benign adrenal lesions. The sensitivity and specificity of using a cutoff level 10 HU for characterization an adrenal lesion as a benign adenoma in unenhanced CT was 71 and 98% respectively. This means adrenal masses with an attenuation of more than 10 HU in unenhanced CT are most likely to be malignant.³

Our patient presented with features of virilization such as hirsutism and clitoromegaly. She had markedly increased levels of DHEAS and unenhanced CT scan showed a 5.3 cm mass with an intensity of 46 HU (i.e. more than 10 HU). All these features suggested an adrenal carcinoma. However, histopathology later proved the tumor to be of benign nature. Therefore, the final diagnosis was adrenocortical adenoma.

There are few case reports where an adrenal adenoma presented with features of virilization. It was reported in an 18-month-old girl with ganglioneuroblastoma and an adrenal adenoma.¹ A 14-year-old Caucasian girl presented with features of virilization. Her androgen levels were extremely high. Adrenal ultrasonography revealed an adrenal mass 4.6 × 5.3-cm. The histologic findings showed a benign adrenocortical tumor.² Previously no cases of a virilizing adrenal adenoma have been reported in Bangladesh. Therefore, the present case indicates that not all adenomas present typically with only cushingoid features. Benign tumors can also present with features like virilization and high androgen levels as seen usually in carcinomas.

References

1. Dahms T W, Gray G, Vrana M, New M I. A case presenting as Cushing syndrome with virilization. *Am J Dis Child* 1973; **125**: 608-611.
2. Eliakim A, Cale-Benzoor M, Klinger-Cantor B, Freud E, Nemet D, Feigin E, Weintrob N. A case study of virilizing adrenal tumor in an adolescent female elite tennis player - insight into the use of anabolic steroids in young athletes. *Journal of Strength and Conditioning Research* 2011; **25**(1):46-50.
3. Allolio B, Fassnacht M. Adrenocortical carcinoma: clinical update. *The Journal of Clinical Endocrinology & Metabolism* 2006; **91**: 2027-2037.