

Melioidosis by aminoglycoside susceptible *Burkholderia pseudomallei*: First case in Bangladesh

Saika Farook¹, Md. Shariful Alam Jilani^{2*}, Alpona Akhter³, J. Ashraful Haq²

¹Department of Microbiology, Bangladesh Institute of Research and Rehabilitation in Diabetes, Endocrine and Metabolic Disorders (BIRDEM), Dhaka, ²Department of Microbiology, Ibrahim Medical College, Dhaka, ³Department of Oncology, Dhaka Medical College, Dhaka

Abstract

Burkholderia pseudomallei is the etiological agent of melioidosis. It is a gram-negative bacillus present in environment and intrinsically resistant to many antibiotics including aminoglycosides. However, recently aminoglycoside susceptible *B. pseudomallei* has been isolated from melioidosis cases and reported from some countries of the world. But, such aminoglycoside susceptible *B. pseudomallei* has never been detected in Bangladesh either from melioidosis cases or from environment. All the *B. pseudomallei* isolated so far in Bangladesh were resistant to gentamicin and other aminoglycosides. Here, we describe a disseminated case of melioidosis caused by aminoglycoside susceptible *B. pseudomallei* in a 55 years old Bengali male patient. This is the first case of melioidosis due to aminoglycoside susceptible *B. pseudomallei* in Bangladesh.

IMC J Med Sci 2020; 14(2): 003. Epub date: 19 October 2020

Introduction

Burkholderia pseudomallei, a gram-negative bacillus, causing melioidosis is intrinsically resistant to aminoglycosides, macrolides and colistin [1-2]. This intrinsic resistance to aminoglycosides and colistin is used as identification criterion for *B. pseudomallei*. Also, these antibiotics are used to prepare selective media for isolation of *B. pseudomallei*. However, recently aminoglycoside susceptible *B. pseudomallei* strains have been detected in some regions of Malaysia, Thailand and Australia [3-6]. But, such aminoglycoside susceptible *B. pseudomallei* has so far not been detected in Bangladesh. All the *B. pseudomallei* isolated and reported from Bangladesh were resistant to aminoglycosides [7]. But, here we describe a disseminated case of melioidosis caused by aminoglycoside susceptible *B. pseudomallei* in a 55 years old Bengali male patient.

Case Summary

A 55 years old smoker, non-diabetic male presented with a 3 month history of high grade fever, non productive cough and weight loss. About a year back, he developed intermittent to high grade fever, cough and loss of appetite and was diagnosed as a smear negative pulmonary tuberculosis case and treated accordingly in a local hospital. Initially, his symptoms improved, but about 3 months back he gradually developed high grade fever again, the highest recorded temperature being 104⁰F. With deteriorating symptoms he was admitted to Medicine unit of Dhaka Medical College Hospital. Four days after admission he developed pain and swelling on the left elbow. About 1 month following admission, the patient developed sudden, severe headache along with a single episode of vomiting followed by restlessness and disorientation. He had 5 episodes of seizures in 2 days with loss of consciousness (Glasgow Coma Scale was 3/15).

*Correspondence: Md. Shariful Alam Jilani, Department of Microbiology, Ibrahim Medical College, 1/A Ibrahim Sarani, Segunbagicha, Dhaka 1000, Bangladesh. e-mail: jilanimsa@gmail.com

On general examination, patient was mildly anemic, dyspneic and the temperature was 103^oF. Respiratory system examination revealed features suggestive of consolidation. The left elbow joint was erythematous, swollen (4cm×4cm), tender without any discharge or regional lymphadenopathy. Liver was just palpable. Blood analysis yielded haemoglobin 9.6 g/dl, ESR 70 mm at first hour, total white cell count 6.8x10⁹/L, platelets 70x10⁹/L, SGPT 80 U/L and SGOT 173 U/L. HbsAg and anti Hbc IgM was positive. Chest radiograph showed patchy and in-homogenous opacities in both upper, mid and right lower zone of both lungs (Fig-1). Blood, sputum, urine and cerebrospinal fluid (CSF) culture yielded no growth. Sputum for acid fast bacilli (AFB) and *Mycobacterium tuberculosis* by Ziehl–Neelsen stain and MTB/RIF-GeneXpert test was negative respectively. Ultrasonography of whole abdomen revealed mild hepatosplenomegaly and grossly enlarged prostate. Magnetic resonance imaging (MRI) of brain exhibited features suggestive of venous infarct due to suspected venous thrombosis involving superior sagittal sinus.

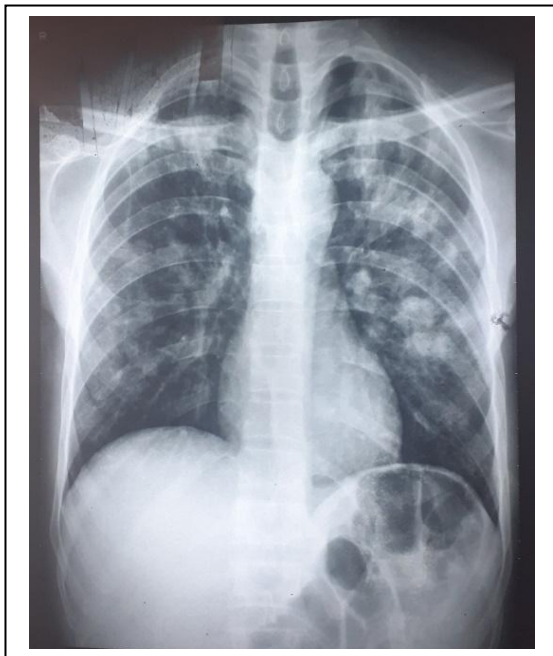


Fig.1: Chest X-Ray P/A view showing patchy opacities in upper, middle and lower zone of lungs

Pus was aspirated from the left elbow joint swelling using a sterile syringe. Gram stain of the pus showed gram-negative bacilli arranged in bipolar 'safety pin' pattern. Culture of the pus yielded growth of gram-negative and oxidase positive bacilli in Blood and MacConkey agar media, but no growth was detected on modified Ashdown's selective media containing gentamicin 5µg/ml. The isolate was identified as *B. pseudomallei* by colony morphology and biochemical tests [8]. The isolate was further confirmed by monoclonal antibody based latex agglutination test for *B. pseudomallei* (Meloidosis Research Center, Khon Kaen, Thailand). Polymerase Chain Reaction (PCR) and Loop Mediated Isothermal Amplification based assay (LAMP) using *B. pseudomallei* specific primers (Table-1) were also performed for further confirmation of the isolate. Both PCR and LAMP tests confirmed the isolate as *B. pseudomallei* (Fig-2 and Fig-3). The isolate was sensitive to ceftazidime, meropenem, amoxicillin+clavulanic acid, piperacillin+tazobactam and aminoglycosides namely gentamicin, amikacin and netilmicin (Table-2) and resistant to trimethoprim-sulphamethoxazole (TMP-SMX) and colistin. Since aminoglycoside susceptible *B. pseudomallei* was never been detected in Bangladesh further enquiry was made to track the possible source of the organism. On enquiry, it was found that he had been a construction worker in Malacca, Malaysia for the past 10 years where he developed high grade intermittent fever, cough and loss of appetite about a year ago and then he returned to Bangladesh. Based on the above, the patient was finally diagnosed as a case of disseminated melioidosis by aminoglycoside susceptible *B. pseudomallei*. Probably, the patient could have acquired the infection while in Malaysia because such aminoglycoside susceptible *B. pseudomallei* strains are prevalent there. The patient was successfully treated with standard antibiotic regimen for melioidosis and discharged with improved general condition.

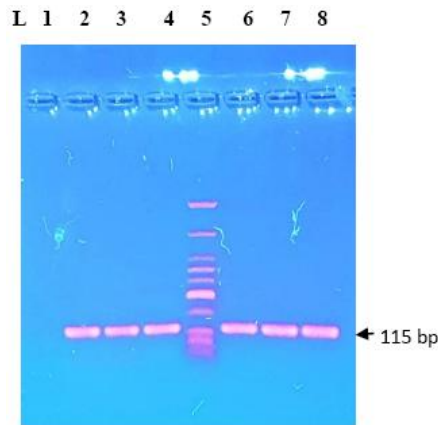


Fig. 2: Amplification of the 115 bp product of *B. pseudomallei* by PCR. Lane 1= Negative template control. Lane 2= amplified product of *B. pseudomallei* USM strain, as positive control. Lane 4= positive aminoglycoside sensitive *B. pseudomallei*. Lane 5= 25 bp DNA ladder. Lane 3, 6-8= other gentamicin resistant positive *B. pseudomallei*

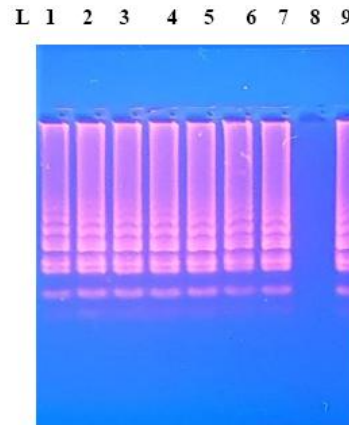


Fig. 3: Amplification of *B. pseudomallei* by LAMP. Lane 1= amplified product of *B. pseudomallei* USM strain, as positive control. Lane 8= Negative template control. Lane 3= positive aminoglycoside sensitive *B. pseudomallei* LAMP product. Lane 4-7, 9= other gentamicin resistant *B. pseudomallei* LAMP products

Table-1: Primers targeting *TTS1* gene used in conventional PCR [9] and in-house LAMP [10]

Primers for PCR	Primer sequence
Forward primer	5`-CGTCTCTATACTGTGCGAGCAATCG-3`
Reverse primer	5`-CGTGCCACCCGGTCAGTACTC-3`
Primers for LAMP	Primer sequence
Forward Outer Primer (F3-2)	TCGATTGCTTCGACAGCG
Forward Inner Primer (FIP-2)	TTCGCCTCCAGCATCAACCTGCCAATTTCCATTTCCGGCAGC
Backward Outer Primer (B3-2)	AATCCCTGCCCGTCAATG
Backward Inner Primer (BIP-2)	CTCGTCTATGCGCAGGATCAGGCGGCAACCGGATTATCAGT
Forward Loop Primer (LF)	ATACCGTCAATGTCCGACCCG
Backward Loop Primer (LB)	CGGCATCGATACCAACACG

Table-2: Results of disc diffusion and MIC tests of isolated *B. pseudomallei*

Antimicrobial agents	Disk diffusion test		MIC test (µg/ml)		Interpretation
	Zone of inhibition of test organism (mm)	Sensitive zone diameter breakpoints (mm)	MIC of test organism (µg/ml)	MIC breakpoints (Sensitive)	
Gentamicin ^a	22	≥15	1	≤4	Sensitive
Amikacin ^a	19	≥17	2	≤16	Sensitive
Netilmicin ^a	20	≥15	Not done	≤8	Sensitive

Note: a=Zone diameter interpretive standards of CLSI for *P. aeruginosa* by disk diffusion method [11].

Discussion

In Bangladesh, the first case of melioidosis was reported in 1988 [12]. Since then, about 54 human melioidosis cases from different districts of Bangladesh have been recorded till 2018 [13]. In addition, *B. pseudomallei* was isolated from soil samples of Gazipur district [14], rendering Bangladesh as a 'definite' melioidosis endemic country.

B. pseudomallei is known to be intrinsically resistant to aminoglycosides [2]. Resistance to aminoglycosides and colistin is an important identification criterion for *B. pseudomallei*. All *B. pseudomallei* that have been isolated in Bangladesh till now were resistant to amikacin and gentamicin by both Kirby-Bauer disk diffusion and MIC method [7]. However, aminoglycoside sensitive *B. pseudomallei* have been isolated in certain regions of Southeast Asia and Australia [3-6]. There have been reports of rare cases of melioidosis due to aminoglycoside susceptible strains (0.1%) in Thailand [5] and in Australia [6]. On the contrary, 86% of *B. pseudomallei* isolates in Sarawak, Malaysian Borneo were found sensitive to Gentamicin [3]. However, in Kedah, Malaysia, about 21% and 6% of isolates were susceptible to gentamicin and amikacin respectively [4].

Resistance to aminoglycosides in *B. pseudomallei* is due to *amrAB-oprA*-mediated efflux [5,15]. Studies comprising of genome sequencing have revealed that a mutation or absence of *amr-B* transcripts that encodes for the multidrug efflux system accounts for the susceptibility to aminoglycosides as well as macrolides in the aforementioned isolates [3-4]. Apparently, our patient with disseminated melioidosis was residing in Malacca, Malaysia for the past 10 years. So, it could be reasonably assumed that this particular strain could be acquired in Malaysia where aminoglycoside susceptible strains had previously been detected. However, we should not dismiss the possibility of presence of such aminoglycoside susceptible strains indigenously in Bangladesh. True origin of our aminoglycoside susceptible isolate could be determined if we could do sequence analysis or multilocus sequence typing.

In a resource limited country like ours, culture of *B. pseudomallei* constitutes the diagnostic gold

standard. Intrinsic resistance of *B. pseudomallei* to aminoglycosides is used for the development of selective media for its isolation from samples like sputum or soil that contain other organisms. This particular case demonstrates that the use of gentamicin incorporated selective media might fail to detect such susceptible strains and would undermine the true extent of its presence in environment and clinical samples.

Author contributions

SF did the experiments and wrote the manuscript; MSAJ supervised the work and contributed in writing the manuscript; AA collected the clinical data and involved in the management of the patient; JAH contributed in writing and editing the manuscript.

Conflict of interest

The authors hereby, declare that no conflict of interest exists

Ethical statement

Written consent was obtained from the patient for publication of the case.

Funding

This study was partly funded by Ibrahim Medical College

References

1. Jenney AW, Lum G, Fisher DA, Currie BJ. Antibiotic susceptibility of *Burkholderia pseudomallei* from tropical northern Australia and implications for therapy of melioidosis. *Int J Antimicrob Agents*. 2001; **17**(2): 109-13.
2. Dance DA, Wuthiekanun V, Naigowit P, White NJ. Identification of *Pseudomonas pseudomallei* in clinical practice: use of simple screening tests and API 20NE. *J Clin Pathol*. 1989; **42**(6): 645-8.
3. Podin Y, Sarovich DS, Price EP, Kaestli M, Mayo M, Hii K, Ngian H, Wong S, Wong I, Wong J, Mohan A. *Burkholderia pseudomallei* isolates

- from Sarawak, Malaysian Borneo, are predominantly susceptible to aminoglycosides and macrolides. *Antimicrob Agents Chemother.* 2014; **58**(1): 162-6.
4. Hassan MR, Vijayalakshmi N, Pani SP, Peng NP, Mehenderkar R, Voralu K, Michael E. Antimicrobial susceptibility patterns of *Burkholderia pseudomallei* among melioidosis cases in Kedah, Malaysia. *Southeast Asian J Trop Med Public Health.* 2014; **45**(3): 680.
 5. Trunck LA, Propst KL, Wuthiekanun V, Tuanyok A, Beckstrom-Sternberg SM, Beckstrom-Sternberg JS, Peacock SJ, Keim P, Dow SW, Schweizer HP. Molecular basis of rare aminoglycoside susceptibility and pathogenesis of *Burkholderia pseudomallei* clinical isolates from Thailand. *PLOS Negl Trop Dis.* 2009; **3**(9): 519.
 6. Price EP, Sarovich DS, Mayo M, Tuanyok A, Drees KP, Kaestli M, Beckstrom-Sternberg SM, Babic-Sternberg JS, Kidd TJ, Bell SC, Keim P. Within-host evolution of *Burkholderia pseudomallei* over a twelve-year chronic carriage infection. *mBio.* 2013; **4**(4).
 7. Dutta S, Haq S, Hasan MR, Haq JA. Antimicrobial susceptibility pattern of clinical isolates of *Burkholderia pseudomallei* in Bangladesh. *BMC Res Notes.* 2017; **10**(1): 1-5.
 8. Lipuma JJ, Currie BJ, Lum GD, Vandamme PAR. *Burkholderia*, *Stenotrophomonas*, *Ralstonia*, *Cupriavidus*, *Pandrea*, *Brevundimonas*, *Comamonas*, *Delftia*, and *Acidovorax*. In: Murray PR, Baron EJ, Jorgensen JH, Landry ML, Pfaller MA, editors. *Manual of Clinical Microbiology.* 9th ed. Washington, DC: ASM Press; 2007. p. 749–769.
 9. Novak RT, Glass MB, Gee JE, Gal D, Mayo MJ, Currie BJ, Wilkins PP. Development and evaluation of a real-time PCR assay targeting the type III secretion system of *Burkholderia pseudomallei*. *J Clin Microbiol.* 2006; **44**(1): 85-90.
 10. Farook S. Development of Loop Mediated Isothermal Amplification based assay for the rapid detection of *Burkholderia pseudomallei* [Thesis]. Dhaka, Bangladesh: Bangabandhu Sheikh Mujib Medical University. July, 2020.
 11. Performance standards for antimicrobial susceptibility testing M100. Thirtieth Informational Supplement, vol. 39. Wayne: Clinical and Laboratory Standards Institute; 2020.
 12. Struelens MJ, Mondol G, Bennish M, Dance DA. Melioidosis in Bangladesh: a case report. *Trans R Soc of Trop Med Hyg.* 1988; **82**(5): 777-8.
 13. Chowdhury FR, Jilani M, Alam S, Barai L, Rahman T, Saha MR, Amin M, Fatema K, Islam KM, Faiz MA, Dunachie SJ. Melioidosis in Bangladesh: a clinical and epidemiological analysis of culture-confirmed cases. *Trop Med Infect Dis.* 2018; **3**(2): 40.
 14. Jilani MS, Robayet JA, Mohiuddin M, Hasan MR, Ahsan CR, Haq JA. *Burkholderia pseudomallei*: its detection in soil and seroprevalence in Bangladesh. *PLOS Negl Trop Dis.* 2016; **10**(1): e0004301.
 15. Moore RA, DeShazer D, Reckseidler S, Weissman A, Woods DE. Efflux-mediated aminoglycoside and macrolide resistance in *Burkholderia pseudomallei*. *Antimicrob. Agents Chemother.* 1999; **43**:465-470.