

A 4-year-old boy with progressive penile enlargement and accelerated growth

*Rahman MA¹, Ahmed N², Haq T³, Selim S⁴, Fariduddin M⁵

¹Md Ashiqur Rahman, Resident, Department of Endocrinology, Bangabandhu Sheikh Mujib Medical University (BSMMU), Dhaka, Bangladesh;

²Nasir Ahmed, Resident, Department of Pathology, BSMMU, Dhaka, Bangladesh; ³Tahniyah Haq, Associate Professor, Department of Endocrinology, BSMMU, Dhaka, Bangladesh; ⁴Shahjada Selim, Associate Professor, Department of Endocrinology, BSMMU, Dhaka, Bangladesh; ⁵Md Fariduddin, Professor, Department of Endocrinology, BSMMU, Dhaka, Bangladesh

Abstract

A 4-year-old boy presented with progressive penile enlargement, pubic hair, acne, and aggressive behaviour for two years. Physical examination revealed that height was greater than the 95th percentile. Tanner stages showed advanced pubertal signs. His bone age was also advanced compared to chronological age. Laboratory findings were suggestive of peripheral precocious puberty. Abdominal imaging showed a mass at the right adrenal gland. The patient underwent a right open adrenalectomy. There was a well-circumscribed mass with no invasion of surroundings. The histopathology study was consistent with an adrenocortical tumor which was confirmed to be an adenoma by Immunohistochemistry. Postoperatively his cortisol and testosterone levels were normal. Follow-up at 6 months showed that there was secondary activation of the hypothalamic-pituitary-gonadal axis, a complication of prolonged exposure to androgens. [*J Assoc Clin Endocrinol Diabetol Bangladesh, January 2024; 3 (1): 34-37*]

Keywords: Precocious puberty, adrenal tumor

***Correspondence:** Md Ashiqur Rahman, Resident, Department of Endocrinology, Bangabandhu Sheikh Mujib Medical University, Dhaka, Bangladesh. Email: ashiqur149dmc@gmail.com, Cell no: +8801737392103

Introduction

Precocious puberty is the onset of pubertal development before the age of 8 years in girls and before 9 years in boys.¹ The causes of precocious puberty may vary from a variant of normal pubertal development to more sinister causes like brain tumors or gonadal tumors. The causes can be classified into central (due to premature activation of the hypothalamic-pituitary-gonadal axis) or peripheral (due to excess production of gonadal sex steroids due to any tumor or congenital adrenal hyperplasia).² The evaluation of these patients requires careful history to ascertain whether the child has developed abnormal pubertal features compared to age and anthropometry, Tanner staging, and other relevant examinations to confirm the suspicion. Investigations require routine tests along with hormone tests like gonadal steroids, FSH and LH, GnRH stimulation test, bone age, and other imaging like an MRI of the brain or CT scan of the abdomen to look for the etiology of precocious puberty. Here we report a very rare case of adrenal tumor in a child who presented with peripheral precocity.

Case Summary

A 4-year-old boy presented with complaints of penile enlargement, the appearance of pubic hair, and acne for the last 2 years which was gradually progressive. His parents had also noticed that his behavior was aggressive toward his peers for the last few months. Physical examination revealed; a height of 120 cm (>95th percentile), weight of 23 kg, tanner stages for pubic hair was IV, stretched penile length was 14 cm, and testicular volume was 3.5 ml (Figure-1). His bone age was advanced (10-12 years) (Figure-2). Laboratory findings revealed low gonadotropins, and high testosterone (Table-I). So precocious puberty was gonadotropins independent (peripheral), either adrenal or testicular. Abdominal ultrasonography showed a hypoechoic mass in the right adrenal gland (22×17) mm, and an abdominal CT scan demonstrated a low-density mass at the right adrenal gland region measuring (2.2×1.8×1.7) cm (Figure-3). Based on the above data the interpretation was adrenal androgen-secreting tumor either adenoma or carcinoma.

The patient underwent right open adrenalectomy: tumor size was (1.5×1.5) cm, and there was no invasion to

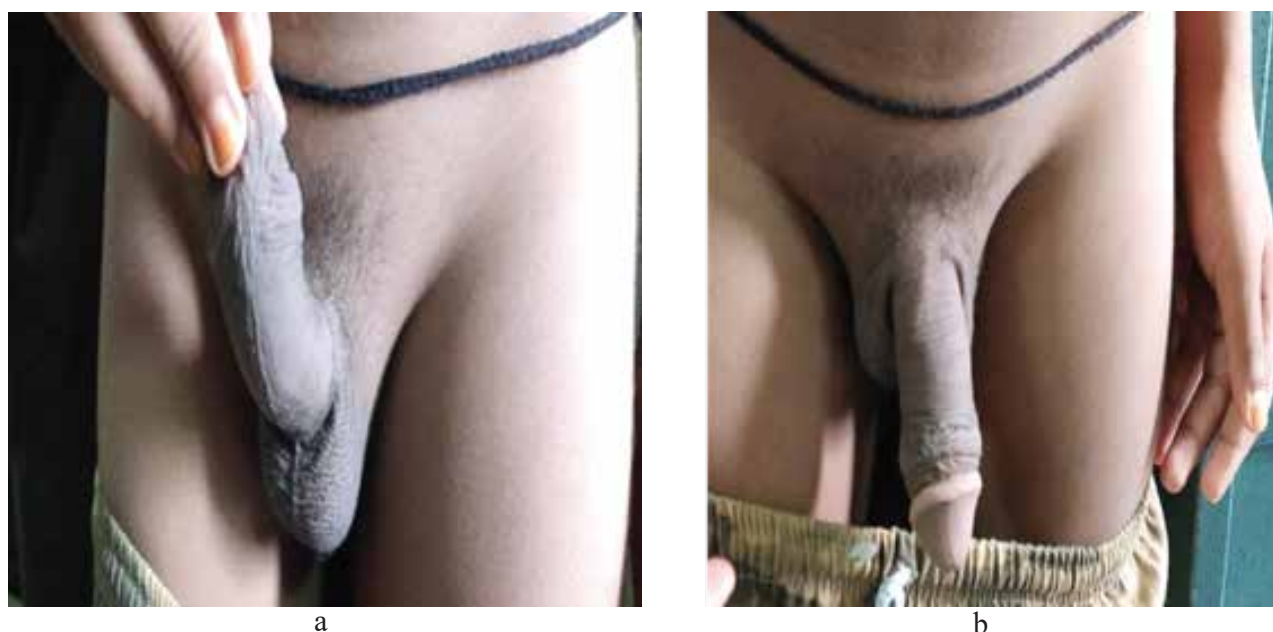

Figure 1 (a and b): Penile enlargement and pubic hair in the 4-year-old boy. In comparison, testicular volume was normal

Table-1: Hormonal and Radiological profiles of the patient

Investigation	Before surgery	After Surgery	Follow up after 6 months	Age-specific reference range
TSH (mIU/mL)	5.21	-	-	0.73-4.77
FSH (IU/L)	0.18	1.02	-	≤ 3
LH (IU/L)	0.13	0.6	1.99	0.2-4.9
Testosterone (ng/dL)	545	7.2	401.5	<19
DHEAS (μg/dL)	39.7	1.5	-	≤ 5
Cortisol (nmol/L)	-	215	-	55-469
LH- 1 hr after GnRH (IU/L)	-	-	30.4	≥5 indicates pubertal response
USG of testes	Right testes 16.9×9 mm, left testes 17×9.6 mm	-	-	-

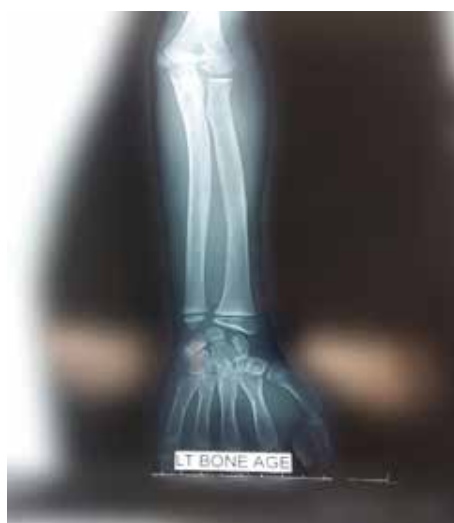

Figure 2: X-ray of left wrist and elbow showing advanced bone age in the 4-year-old boy

surroundings. His surgery and recovery period was uneventful. The histopathology study showed an encapsulated tumor composed of sheets of cells having pleomorphic nuclei with abundant clear to eosinophilic cytoplasm, mitoses were infrequent and no necrosis was seen (Figure-4). Immunohistochemistry showed tumor cells were positive for synaptophysin and inhibin A and negative for chromogranin A and GATA 3. Ki67 index was about 3% and it was confirmed to be an adrenal adenoma. Postoperative follow-up showed his testosterone and DHEAS levels were in the prepubertal range and his cortisol level was normal (Table-I). Subsequent follow-up after 6 months showed that his height was 126 cm, stretched penile length 15 cm, and testicular volume 5 ml on both sides. GnRH stimulation showed a pubertal response (Table-I). A diagnosis of secondary central precocious puberty was made. Due to

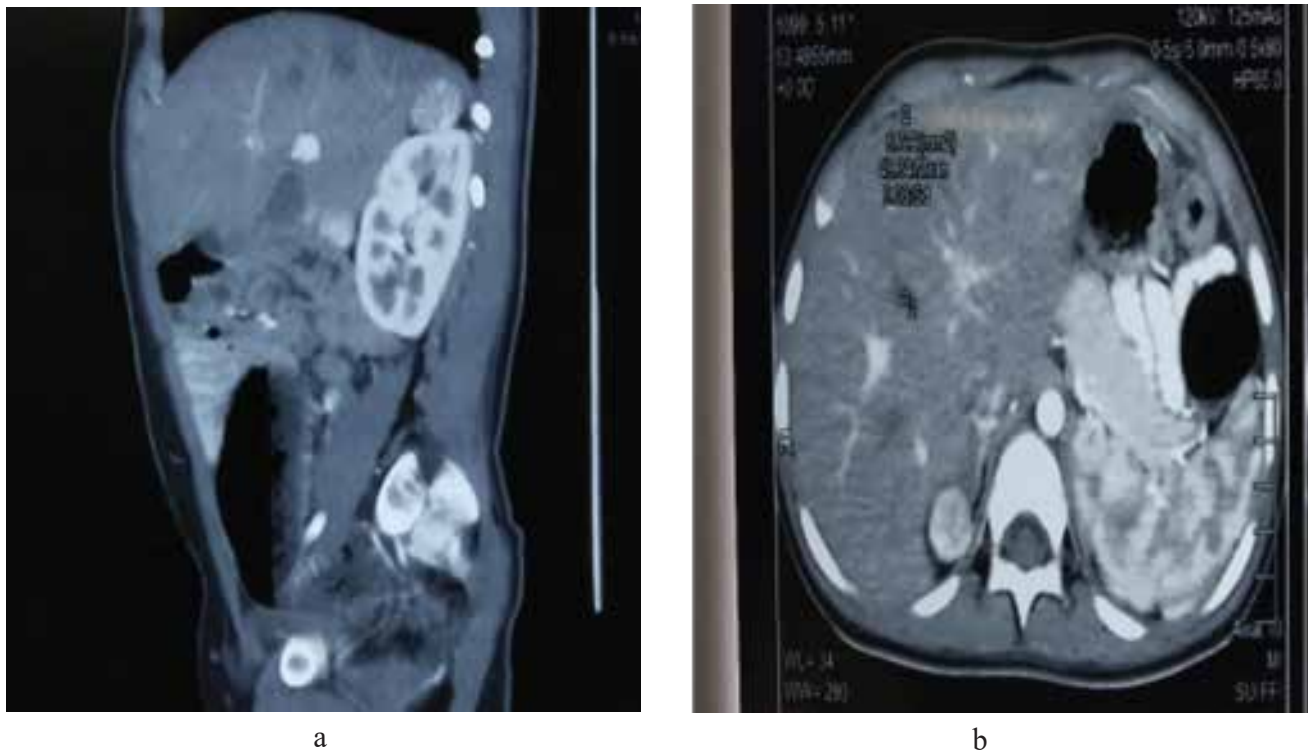


Figure 3 (a and b): CT scan demonstrated a low-density mass at the right adrenal gland region measuring (2.2×1.8×1.7) cm

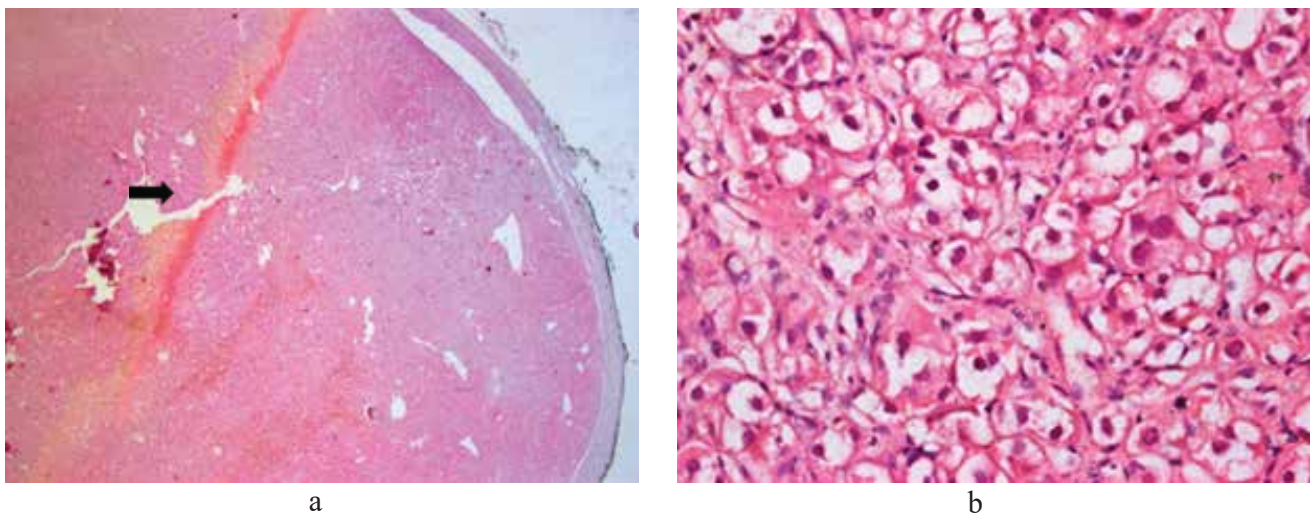


Figure 4 (a and b): The histopathology study showed an encapsulated tumor composed of sheets of cells having pleomorphic nuclei with abundant clear to eosinophilic cytoplasm, mitoses were infrequent and no necrosis.

prolonged exposure to androgens, there is premature activation of the hypothalamic-pituitary-gonadal axis. The diagnosis was explained to the patient and it was decided to start him on GnRH analog (leuprolide) once a month.

Discussion

Precocious puberty can be classified into central and peripheral precocious puberty, based on underlying

etiology. The clinical presentations of the two types of precocious puberty are markedly different, as central precocious puberty (CPP) usually presents with sequential enlargement of the testes, penis, and pubic hair in males and sequential maturation of breasts and pubic hair in females. CPP is usually isosexual (appropriate for the child's sex). It is usually idiopathic in females but organic in males (brain tumor, trauma, hydrocephalus). Peripheral precocity presents mainly

with the early development of pubic and/or axillary hair.³ It can be isosexual or contrasexual. There are several causes of peripheral precocity, including adrenal tumors, non-classical congenital adrenal hyperplasia, testicular tumors, germ cell tumors, McCune-Albright syndrome, familial male-limited precocious puberty (testotoxicosis), or exogenous sex steroid hormone usage. Central precocious puberty is usually treated with GnRH analog to delay pubertal development and prevent bone maturation which may lead to short stature. The decision to treat with GnRH analog is made on the factors of the child's age, height velocity, rapidity of sexual maturation, bone age advancement, etc. During treatment, the patient should be warned about the initial flare. The monitoring schedule varies according to the individual. Height velocity, pubertal features, bone age, LH, and sex steroids are to be checked every 6-12 months.⁴ Peripheral precocious puberty due to underlying tumor needs surgical excision.

Adrenal tumor in children is rare accounting for only 0.2% of all pediatric neoplasm.⁵ It is relatively more common in Brazil.⁵ Compared to adults, the adrenal tumor in children usually presents with virilization or Cushing's syndrome. In an adrenal tumor, the question we should answer is if the tumor is functioning and whether is it benign or malignant. In adults, we can use the Weiss criteria in histopathology to define malignancy. However, in children, it is very difficult to distinguish adenoma from carcinoma as there are no definite histopathological criteria.⁶ Immunohistochemistry is done to identify adrenal carcinoma. Treatment is surgical excision of the tumor. Regular follow-up should be done with an examination to look for regression of pubertal features. Hormonal tests should be done to confirm a surgical cure and also to look for secondary maturation of the hypothalamic-pituitary-gonadal axis leading to central precocious puberty.⁷

Conclusions

Even after successful treatment of precocious puberty due to a virilizing adrenal tumor, the patient should be followed up to detect the appearance of secondary central precocious puberty.

Acknowledgements

We are grateful to the parents of the patient for consenting to the

clinical photography and its publication. We are also grateful to the Department of Pathology and Pediatric Surgery of Bangabandhu Sheikh Mujib Medical University, Dhaka, Bangladesh.

Disclosure

The authors declare that no conflict of interest could be perceived as prejudicing the impartiality of the research reported.

Financial Disclosure

The author(s) received no specific funding for this work.

Data Availability

Any inquiries regarding supporting data availability of this study should be directed to the corresponding author and are available from the corresponding author upon reasonable request.

Ethical Approval and Consent to Participate

Written informed consent was obtained from the patient. All methods were performed in accordance with the relevant guidelines and regulations.

Copyright: ©2024. Rahman et al. **Journal of Association of Clinical Endocrinologist and Diabetologist of Bangladesh.** This article is published under the Creative Commons CC BY-NC License (<https://creativecommons.org/licenses/by-nc/4.0/>). This license permits use, distribution and reproduction in any medium, provided the original work is properly cited, and is not used for commercial purposes.

How to cite this article: Rahman MA, Ahmed N, Haq T, Selim S, Fariduddin M. A 4-year-old boy with progressive penile enlargement and accelerated growth. *J Assoc Clin Endocrinol Diabetol Bangladesh*, 2024; 3(1):34-37

Publication History

Received on: 8 October 2023

Accepted on: 29 October 2023

Published on: 1 January 2024

References

1. Styne DM. Physiology and disorders of puberty. In: Melmed S, Koenig R, Rosen CJ, et al., editors. *Williams textbook of endocrinology*. 14th edition. Elsevier; 2019. pp 1149-64.
2. Harrington J, Palmert MR. Definition, etiology, and evaluation of precocious puberty. Up To Date, Section Editors: Peter J. Snyder, MD. 2022.
3. Kafi SE, Alagha E, Shazly MA, Al-Agha A. Pseudo-precocious puberty associated with an adrenocortical tumor in a young child. *Cureus* 2019;11(12):e6440. DOI: 10.7759/cureus.
4. Harrington J, Palmert MR. Treatment of precocious puberty. Up To Date, Section Editors: Peter J. Snyder, MD. 2022.
5. Shirata NK, Sredni ST, Castelo A, Santinelli A, Mendonça B, Montironi R, et al. Texture image analysis in differentiating malignant from benign adrenal cortical tumors in children and adults. *Anticancer Res* 2009;29(8):3365-08.
6. Erickson LA, Rivera M, Zhang J. Adrenocortical carcinoma: review and update. *Adv Anat Pathol* 2014;21(3):151-9. DOI: 10.1097/PAP.000000000000019.
7. Razavi Z, RastgooHaghi A: Precocious puberty associated with an adrenal tumor: a case report. *Iran J Ped Hematol Oncol* 2016; 6:136-41. DOI: 10.7759/cureus.6440.