

Accuracy of Ultrasonogram in Diagnosis of Acute Appendicitis

Perveen R¹, Islam AFMS², Rahman H³, Khan RP⁴

Abstract

Introduction: Acute appendicitis is one of the most common causes of abdominal pain of adult patients referred to the emergency department. Despite its prevalence, the diagnosis of appendicitis can be elusive and fraught with pitfalls because of the absence of a pathognomonic sign or symptom and the poor predictive value of laboratory testing. So following the significant advances in accuracy, ultrasonography has become an important part of the modern work-up of acute appendicitis.

Objective: To evaluate the role and accuracy of ultrasonography in the diagnosis of acute appendicitis.

Materials and Methods: A total number of 110 cases (65 men and 45 women), with clinical suspicion of appendicitis, were subjected to abdominal ultrasonographic examination. All ultrasonographic positive cases and a few of ultrasonographic negative cases were subjected to operative intervention. The accuracy of ultrasonography in the diagnosis of appendicitis was compared with the clinical diagnosis, operative findings and histopathological examination reports. The statistical analysis was done by using SPSS10.

Results: Among 110 cases, 77 cases were sonographically positive for appendicitis and 5 cases were appendicular masses. The cardinal signs were right lower abdominal tenderness, rebound tenderness and positive Rovsing's sign. The specificity of Ultrasound was 74.28%, sensitivity 90.66%, positive predictive value 88.31%, negative predictive value 78.79% and accuracy was 85.45% in the diagnosis of acute appendicitis.

Conclusion

So far the cost reduction of treatment and negative laparotomies are concerned, the ultrasonography is still an useful tool in the diagnosis of appendicitis in spite of more recent investigations like CT abdomen and Laparoscopy.

Key-words: Acute Appendicitis, Ultrasonography, Accuracy of Diagnosis, Sensitivity, Specificity.

Introduction

Abdominal ultrasonography (USG) has a definitive role in the diagnosis of acute appendicitis because it establishes an alternative diagnosis in patient with acute right lower abdominal pain and reduces the number of negative laparotomies¹. Delay in the diagnosis and surgery in some atypical cases of appendicitis may result in perforation. This occurs in 17-39% of patients with appendicitis. The elderly and very young are at a higher risk². Acute appendicitis is still the most common indicator to emergency abdominal surgery. The clinical diagnosis of appendicitis is difficult in a few cases. Approximately 20.33% of patients will present atypically^{1,2,3}. The inflamed appendix is seen as a blind ended tubular structure with laminated wall arising from the base of cecum. Puylaert reported the sensitivity of 89% and specificity 100% in the diagnosis of acute appendicitis by ultrasonography^{4,6}. However the diagnosis is still based on clinical features. The aim of this study was to evaluate the role of ultrasonography to find out its accuracy to diagnose the appendicitis by comparing with clinical assessment and histopathological reports.

1. **Dr Rosy Perveen**, MBBS, FCPS, Assistant Professor of Radiology and Imaging, Medical College for Women and Hospital (MCWH), Uttara, Dhaka 2. **Dr AFMS Islam**, MBBS, DMRD, Associate Professor and Head, Department of Radiology and Imaging, MCWH, Uttara, Dhaka 3. **Brig Gen Habibur Rahman (Retd)**, MBBS, FCPS, Professor in Surgery, Nightangle Medical College, Savar, Dhaka 4. **Dr Ruksana P Khan**, MBBS, DNM, Sonologist, MCWH, Uttara, Dhaka.

Materials and Methods

This observational study was carried out in the department of Radiology and Imaging in collaboration with the department of Surgery in MCWH at Uttara, Dhaka and Catharsis Hospital, Pubail, Dhaka over a period of 2 years from May 2014 to April 2016. A total of 110 patients (65 men and 45 women, age range from 10 years to 65 years) who presented with pain in the right lower abdomen, in whom acute appendicitis was suspected basing on clinical features, were subjected to abdominal USG examination.

Inclusion Criteria:

- Male and female patients with age group of 10 to 65 years.
- Pain in right iliac fossa.
- Fever.
- Increased leucocytes count.
- Mass in right iliac fossa.
- Patients with recurrent appendicitis were also included.

Exclusion Criteria:

- Patients below 10 and above 65 years of age.
- History of previous laparotomy.
- Chronic infectious disease like ileocecal tuberculosis.
Carcinoid tumors and other neoplastic lesions of the appendix.
- Patients with 3rd trimester of pregnancy.

Sonographic Criteria:

The following accepted criteria were considered for the diagnosis of an inflamed appendix.

- a. A peristaltic non compressive appendix as a blind ending tubular structure.
- b. Diffuse hypoechogenicity (associated with a higher incidence of perforation)
- c. Target appearance of ≥ 6 mm (6 millimeters) in the total diameter on cross section (81%) in axial mural wall thickness ≥ 2 mm.
- d. Localized periappendicular fluid collection.
- e. Lumen may be distended with an echoic/ hyper echoic material.
- f. Visualization of appendicolith
- g. Free pelvic fluid.
- h. Prominent hyperechoic mesoappendix/ pericaecal fat.

The criteria of Negativity:

Negative appendix was defined as normal looking appendix on operation and absence of acute inflammation on histopathology. All cases were sent for histopathology and the ones in which histopathological examination (HPE) was negative, were considered as true negatives.

Results

It has been shown that all of the patients included in the study had history of abdominal pain which was considered to be of strong clinical suspicion of acute appendicitis. Tenderness over right iliac fossa (RIF) was the most common sign elicited in all 110 cases (100%). Migration of pain to RIF was found in 80 (72.72%), vomiting was found in 70 (63.63%) cases, rebound tenderness in 85 (77.27%), Rovsing's sign in 49 (44.54%) and fever in 45 (40.90%) cases (Table-I).

Table-I: Clinical signs and symptoms

Symptoms	Cases(n)	
Pain in abdomen	110	
Migration of pain	80	7
Fever	45	4
Vomiting	70	6
Diarrhoea	9	8
Dysuria	6	5
Sign		
RIF Tenderness	110	
Rebound tenderness	85	7
Guarding	27	2
Tachycardia	55	
Rovsing's sign	49	4
Leukocytosis	80	7
Neutrophilia	90	8
Pus cell and RBC in urine	18	1

Total white cell count rose significantly in 72.72% in our patients. This result was comparable to the study done by Lewis et al¹⁴. The outer diameter of the appendix was greater than 6mm in all 77 cases (70%). It is lower than the criteria letdown by Jeffrey et al¹⁶.

Table-II: USG diagnosis of RIF pain (n=110)

Pathology	Cases(n)	
Acute appendicitis	77	
Right ureteric colic	03	
Pelvic inflammatory disease	06	
Ovarian cyst	08	
Appendicular mass	04	
Ectopic pregnancy	05	
Inconclusive findings	07	

All 77 cases which were sonologically positive underwent operative treatment and out of these 77 cases, 68 cases were histopathologically (HPE) positive and 09 cases were HPE negative (Table-III).

Histopathological diagnosis

logy Diagnosis	Cases(n)
ndicitis among USG positive cases	68
ndicitis among USG negative cases	07
pendicitis	05
Hyperplasia	08

The sonologically negative cases were managed conservatively but in this group of 33 cases due to the persistence of symptoms and or surgeon's suspicion 11 cases were operated upon. Out of these 11 cases 07 were HPE positive (Table-IV). Lewis et al noted that pain abdomen which localized in right lower quadrant contributed to the maximum number of patients which was similar to our study⁵.

Correlation of HPE diagnosis with HPE

umber of cases	110
sitive	77
gative	33
sitive	68
gative	9
gative Case Operated	11
sitive	07
gative	04
s	
ases of USG	110
sitive	77
sitive	68
sitive	68
gative	26
ositive	09
egative	07

In this study, tenderness in right lower fossa was seen in 100% cases whereas rebound tenderness at McBurney's point was noted in 92% which is similar to the findings shown by Taura et al¹⁵. Observation shows that the overall sensitivity was 90.66%, specificity was 74.28%, positive predictive value (PPV) 88.31%, negative predictive value (NPV) 78.79% and diagnostic accuracy 85.45%.

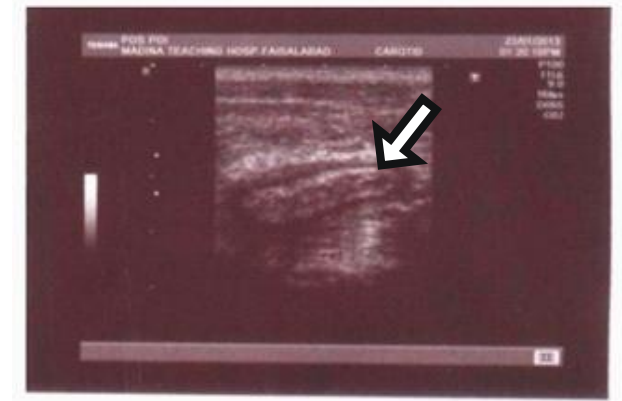

Fig-1: Gray scale image of inflamed, non-compressible appendix as blind ended tubular structure with cross section diameter of 7.9 mm and wall thickness of 2.1 mm.

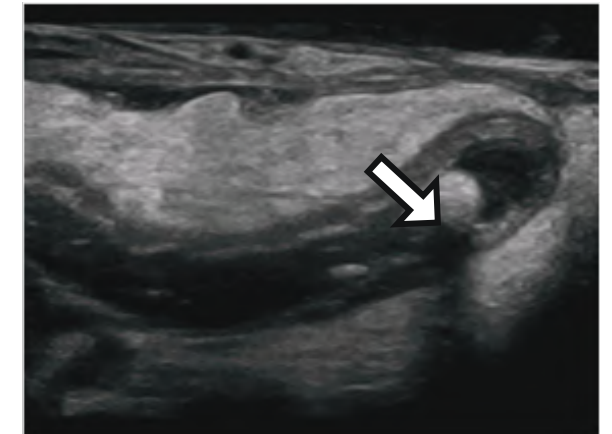


Fig-2: Appendicolith in Ultrasonogram as bright echogenic focus.

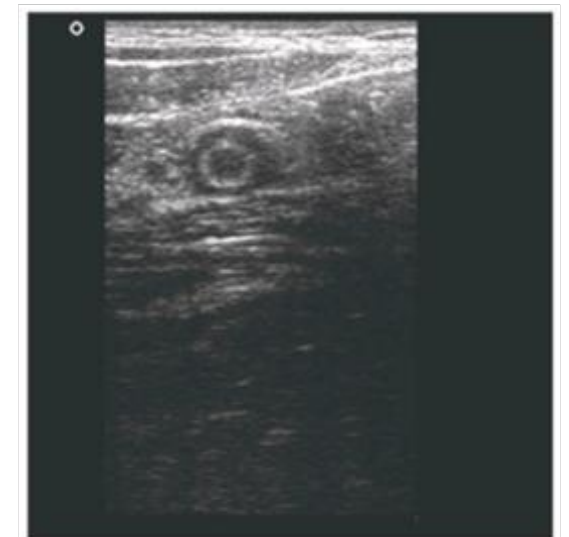


Fig-3: Target sign with inflamed appendix on USG.

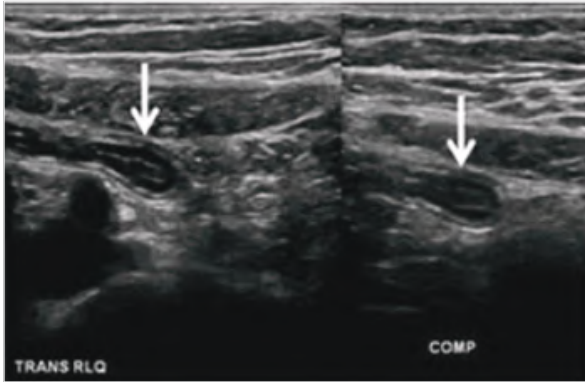


Fig-4: Inflamed appendix with peri appendicular fluid collection.

Discussion

Ultrasonography (USG) is a widely available and inexpensive modality of investigation that has the potential for highly accurate imaging in patients with suspected acute appendicitis. Diagnosis of acute appendicitis is not always straightforward. Sometimes the presentation of the disease is so atypical that even the most experienced surgeon may remove normal appendix or sit on the perforated one⁸⁻⁹. The advantage of USG over computed tomography (CT) is that it allows precise correlation of the USG findings with the area of maximum tenderness or with a palpable mass. The PPV in this study is 88.31% which is relatively low compared with other studies¹⁰⁻¹¹ and can be explained by the study design. This study mainly focused on the screening value of sonography with the sonograms interpreted in a manner to avoid missing any cases with positive findings. Therefore, subtle but non-specific signs that might have indicated acute appendicitis, such as fluids in right paracolic gutter, were interpreted as positive results. These results are comparable to a Korean meta-analysis on the role of USG in the diagnosis of acute appendicitis which shows sensitivity and specificity 86.7% and 90.0% respectively¹²⁻¹³.

This study is compared with study of Tauro et al¹⁵, Jo Shi et al¹⁷, Ida chan et al¹⁸ and Rioux et al¹⁹ which has been shown in Table-VI whose sensitivity values varied from 83 to 90% and specificity ranges from 88.09 to 95%. In this study overall accuracy of sonography was 85.45% and the results were comparable to the studies of Tarzan z et al²⁰, Hahn et al²¹ and Skanne et al²².

The Table-V summarizes the results of our study compared with the results of similar studies in different parts of the world.

Table-V: Validity Test (n=110)

Reference	Sensitivity	Specificity	PPV	NPV	Avg
Present Study	90.66	74.28	88.31	78.79	85.45
Tauro LF et al	91.37	88.09	91.37	88.09	90
Chan et al	83.00	95.00	86.00	94.00	92
Jo Shi et al	96.00	93.00	98.00	88.00	95
Rioux et al	93.00	94.00	86.00	98.00	94

Limitations and Drawbacks of the study

There are certain drawbacks in using ultrasonography for diagnosing acute appendicitis. The foremost important is the experience of the sonologist as the procedure is highly operator dependent. Considering the cost factor of the contrast CT study, it was not included for the accurate diagnosis of dubious cases.

Conclusion

The gold standard for the diagnosis of appendicitis still remains pathologic confirmation after appendectomy. The accuracy of USG in this aspect is extremely variable due to many reasons, including lack of operator skill, increased bowel gas content, obesity, anatomic variants and limitations to explore patients with previous laparotomies. It is inexpensive, safe and widely available. Diagnostic accuracy is reported to range from 71% to 97%²¹⁻²². So USG remains our first line method in the evaluation of patients referred with clinically suspected acute appendicitis. Nevertheless, due to variable diagnostic accuracy, individual skill is requested not only to perform successful examination but also to warrant computed tomography (CT) for equivocal cases to reduce the rate of fatal consequences like perforations.

References

1. Jeffrey RB Jr, Laing FC, Levis FR. Acute appendicitis, high resolution real-time ultrasound findings. *Radiology* 1987; 163:11-4.
2. Deutch AA, Shani V, Reiss R. Are some appendectomies unnecessary? An analysis of 319 white appendices, *JR Coll Surg Edin* 1983; 28:35-40.

3. Jess P, Bjeraegaard B, Brynitz S et al. Acute appendicitis: Prospective trial of cerumir diagnosis accuracy and complication. *Am J Surg* 1987; 141:232-4.
4. Balthezar EJ et al. Acute appendicitis: CT and ultrasound correlation in 100 patients. *Radiology* 1994; 190:31-5.
5. Lewis FR, Itolcroft JW, Boey J et al. Appendicitis: A clinical review of diagnosis and treatment in 1000 cases. *Arch Surg* 1975; 110:677-84.
6. Berry J Jr, Malt RA. Appendicitis near its century. *Ann Surg* 1984 Nov; 200(5):567-75.
7. Puylaert JB. Acute Appendicitis: US evaluation using graded compression. *Radiology* 1986; 158(2):355-60.
8. Hale DA, Molloy M, Pearl RH et al. Appendectomy: A contemporary appraisal. *Ann Surg* 1997; 225(3):252-61.
9. Zielke A, Hasse C, Sitter H et al. Influence of ultrasound on clinical decision making in acute appendicitis: A prospective study. *Eur J Surg* 1998; 164:201-9.
10. Wilson B; Cole JC, Nipper ML et al. Computed tomography and ultrasonography in the diagnosis of appendicitis. When are they indicated? *Arch Surg* 2001; 136:670-5.
11. Rao PM, Boland GW. Imaging of acute right lower abdominal quadrant pain. *Clinical Radiology* 1998; 53:639-49.
12. Yu SH, Kim CB, Park JW et al. Ultrasonography in the diagnosis of appendicitis: Evaluation by meta-analysis. *Korean J Radiol* 2005 Oct-Dec; 6(4):267-77.
13. Asefa G, Mesret S, Nugussle Y. The role of ultrasound in diagnosis acute appendicitis. *Ethiopian Med J* 2006; 44:67-74.
14. Lewis FB, Holcroft Boey J, Dumphy EA, critical Review of diagnosis and treatment in thousand case. *Arch of surgery*, 1975; 110:677-84.
15. Tauro Lf, premanand TS, Aithala PS et al. Ultrasonography is still A useful diagnostic tool in Acute Appendicitis. *Journal of clinical & Diagnostic Research* 2009 oct; 3:1731-36.
16. Jeffery RB Jr, Laing FC, Townsend RR. Acute Appendicitis: sonographic criteria based on 250 patients. *Radiology* 1988; 167:327-9.
17. Joshi Hol, Patel VB, Dave AN. Ultrasonographic evaluation of Acute appendicitis. *Ind J Radiology* 1996; 2:75-8.
18. Ida chan, Simon G. Bicknell, Mary Graham, utility and Diagnostic Accuracy of sonography in detecting Appendicitis in a Community Hospital. *AJR* 2005; 184:1809-12.
19. Michael Rioux. Sonographic detection of normal and abnormal appendix. *AJR* 1992; 158:773-8.
20. Tarjan Z, Mako E, Winternitz T et al. The value of ultrasonic diagnosis in acute appendicitis. *Orv Hetil* 1995; 136:713-7.
21. Lee SL, Walsh AJ, HO HS. Computed tomography and ultrasonography do not improve and may delay the diagnosis and treatment of acute appendicitis. *Arch Surg* 2001; 136:556-62.
22. Hahn HB, Hoepna FV, Kalle et al. sonography of acute appendicitis in children-7 years' experience. *paediatric Radiol* 1998; 28:147-51.
23. Skanne P, Amiard PF, Nordshus T et al. Ultrasonography in patients with suspected appendicitis. A prospective study. *Br J Radiol* 1990; 63:787-93.