

## Assessment of Complications Associated with Tooth Supported Fixed Dental Prosthesis amongst Armed Forces Personnel

Tariquzzaman M<sup>1</sup>, Chowdhury GM<sup>2</sup>, Hyder MLA<sup>3</sup>

### Abstract

**Introduction:** Fixed dental prosthesis is becoming more popular for preservation of badly damaged crowns and endodontically treated teeth and also for replacing lost teeth around the world. Complications of fixed dental prosthesis are also becoming very common. Fixed dental prosthesis assures greater retention and stability in addition to comfort. Fixed dental prosthesis is more acceptable to patients when correctly planned and designed which provide predictable function are also enhances the esthetics and psychological well being of the patients.

**Objective:** To assess the complications associated with tooth supported fixed dental prosthesis amongst armed forces personnel reporting to Combined Military Hospital (CMH) Cumilla and Combined Military Hospital (CMH) Dhaka.

**Materials and Methods:** An interview based questionnaire was used for 220 patients followed by clinical oral examination of every individual in this cross sectional study conducted during September 2016 to August 2017 in Combined Military Hospital, Dhaka. Patients soft tissues were checked but the main emphasis was given on recording the information regarding the type of prosthesis being used, material of the prosthesis, location of the prosthesis and the complication present including dental caries, coronal or radicular abutment fracture, root canal treatment failure, periapical lesions, periodontal problems and mechanical failures including occlusal interference, no occlusal contact, decementation of the prosthesis, esthetic problems, porcelain and metal fractures. Periapical radiograph was made to assess mentioned complaints; more so periodontal probing was applied to measure the gingival attachment loss.

**Results:** Approximately 183(83%) patients were using porcelain fused to metal prosthesis with 133(60%) of prosthesis being used in posterior segments of mouth. Complications like dental caries, coronal abutment fracture, radicular abutment fracture, occlusal interferences, root canal failures and decementations

were more significantly associated with crowns than bridges ( $p=0.001$ ). On the other hand esthetic issues, periapical lesions, periodontal problems, porcelain fractures and metal damage were more commonly associated with bridges ( $p=0.001$ ). All cases of dental caries reported were associated with acrylic crown and bridges, whereas all coronal abutment fractures were associated with metal prosthesis. A significantly higher number of patients who got their fixed dental prosthesis from other sources i.e. paramedics, technicians, dental assistants or unqualified dentists had periapical lesions, decementations, esthetic issues and periodontal diseases.

**Conclusion:** Complications associated with fixed dental prosthesis like root canal failures, decementations, periapical lesions and periodontal disease were more significantly associated with prosthesis fabricated by other sources rather than those acquired from CMHs and private dental care and also in patients using prosthesis for 5 to 10 years.

**Key-Words:** Fixed dental prosthesis, Complications, Armed Forces Personnel.

### Introduction

Fixed dental prosthesis are becoming more popular for preservation of badly damaged crowns or endodontically treated teeth and also for replacing the lost or missing teeth not only in the developed countries but also in the developing countries across the world. Since a fixed dental prosthesis assures the greater retention and stability in addition to comfort, it is more or less considered as the next best to implants<sup>1</sup>. A complication has been defined as "a secondary disease or a condition developing in the course of a primary disease or condition<sup>2</sup>." Whenever clinical failure of fixed dental prosthesis occurs, complications arise; complications also reflect substandard care. Most of the time, during or after appropriately performed fixed prosthodontic treatment procedures complications arise<sup>3</sup>.

1. Lt Col Md Tariquzzaman, BDS, D Prosthodontics, FCPS, Classified Specialist in Prosthodontics, Military Dental Centre, Dhaka  
2. Maj Gen Golam Mohiuddin Chowdhury, BDS, FCPS, Consultant Dental Surgeon General, Dte Gen Med Services, Bangladesh Armed Forces, Dhaka  
3. Brig Gen Md Liakat Ali Hyder, BDS, FCPS, Commandant, Military Dental Centre, Dhaka.

The longevity and complication rate of fixed dental prosthesis (FDPs) are greatly influenced by the level of skills of the clinician and his or her academic knowledge<sup>4</sup>. The treatment with crowns/bridges prosthesis is one of the most common procedures in dental practices. When correctly planned and designed, the fixed dental prosthesis not only provides predictable function but also enhances the aesthetics. On the other hand a poorly manipulated prosthesis is likely to fail prematurely and leads to irreversible damage to the teeth and supporting structures beneath. Sound diagnosis, radiographic examination, clinical assessment and technical skills are essential when dealing with failed or failing fixed prosthesis<sup>5</sup>.

Although fixed dental prosthesis are more acceptable to patients, but also lead to short and longer-term biological changes, notably caries at retainer margins and other lesions like periodontitis of abutment teeth, as well as carrying the risk of technical complications such as loss of retention and fracture of super-structure<sup>6</sup>. Significant tooth reduction of the abutments is the major shortcoming of this alternative<sup>7</sup>. Subgingival margins for esthetic reasons are associated with increased gingival inflammation<sup>8,9</sup>. The most common reason for removals of fixed prosthesis is caries<sup>10,11</sup>. Loss of retention, which has been noted to be related to caries is also a common reason for failures of fixed dental prosthesis<sup>12,13</sup>. Other frequent causes for failures are poor aesthetics, technical problems (fractures of the fixed bridges, porcelain fractures, wear of occlusal surfaces), endodontic treatment through the retainer and periodontal diseases<sup>14,15</sup>. As such, this study was designed to assess the complications associated with tooth supported fixed dental prosthesis amongst armed forces personnel reporting to Combined Military Hospital(CMH) Cumilla and Combined Military Hospital(CMH) Dhaka.

### Materials and Methods

Two hundred and twenty armed forces personnel who visited CMH Cumilla and CMH Dhaka were selected in this cross sectional study. An interview based questionnaire was used to collect relevant information from the patients related to their complaints regarding treatment of fixed dental prosthesis. The questionnaire consisted of 5 questions in total out of which 2 questions were related to demographics i.e. name and age and rest of the questions each was related to information related to place of provision of the prosthesis, duration of use of the prosthesis and the complaints associated with the prosthesis. All patients were then subjected to an oral examination which was carried out using a mirror, dental explorer and dental tweezers. Patients

soft tissue were checked including gingiva, tongue and palate for any soft tissue diseases, calculus or any abnormality but the main emphasis was given on recording the information related to type of prosthesis being used i.e. crown or bridge, material of the prosthesis i.e. acrylic, full metal or porcelain fused to metal (PFM), location of the prosthesis i.e. anterior or posterior and the complication present i.e. biological complications including dental caries, coronal or radicular abutment fracture, root canal treatment failure, periapical lesions, periodontal problems and mechanical failures including occlusal interference, no occlusal contact, decementation of the prosthesis, esthetic problems, porcelain and metal fractures. A periapical radiograph was taken for each patient to evaluate the above mentioned complaints. In addition to periapical radiograph, extinct bleeding on probing, periodontal pocket depth and clinical attachment loss were measured at six sites of each abutment tooth with a periodontal pocket measuring probe to assess the status of periodontal disease. Similarly, dental caries was assessed by means of dental explorer. Bite wing radiographs were taken for those patients who were suspected to have dental caries to confirm the diagnosis.

After completing the questionnaires, the statistical information was analyzed by using SPSS version 17. Data analyses were done in the following steps. Place of provision of the fixed dental prosthesis were recorded into three categories i.e. hospital, private practice and other places where service was provided by paramedics, technicians, dental assistants and unqualified dentists. Similarly the complications related to the duration of use of the fixed dental prosthesis were recorded into four categories i.e. less than 6 months, 6 months to one year, one to five years and five to ten years.

### Results

Out of the 220 patients who participated in the study 121(55%) were males and 99(45%) were females. About 130(59%) patients acquired their fixed dental prosthesis from CMH based care whereas 37(17%) from private dental practices and 53(24%) from other sources. About half i.e. 109(49.5%) of the patients had been using the fixed dental prosthesis for 1 to 5 years followed by 84(38%) who had been using fixed dental prosthesis for the last 6 months to one year.

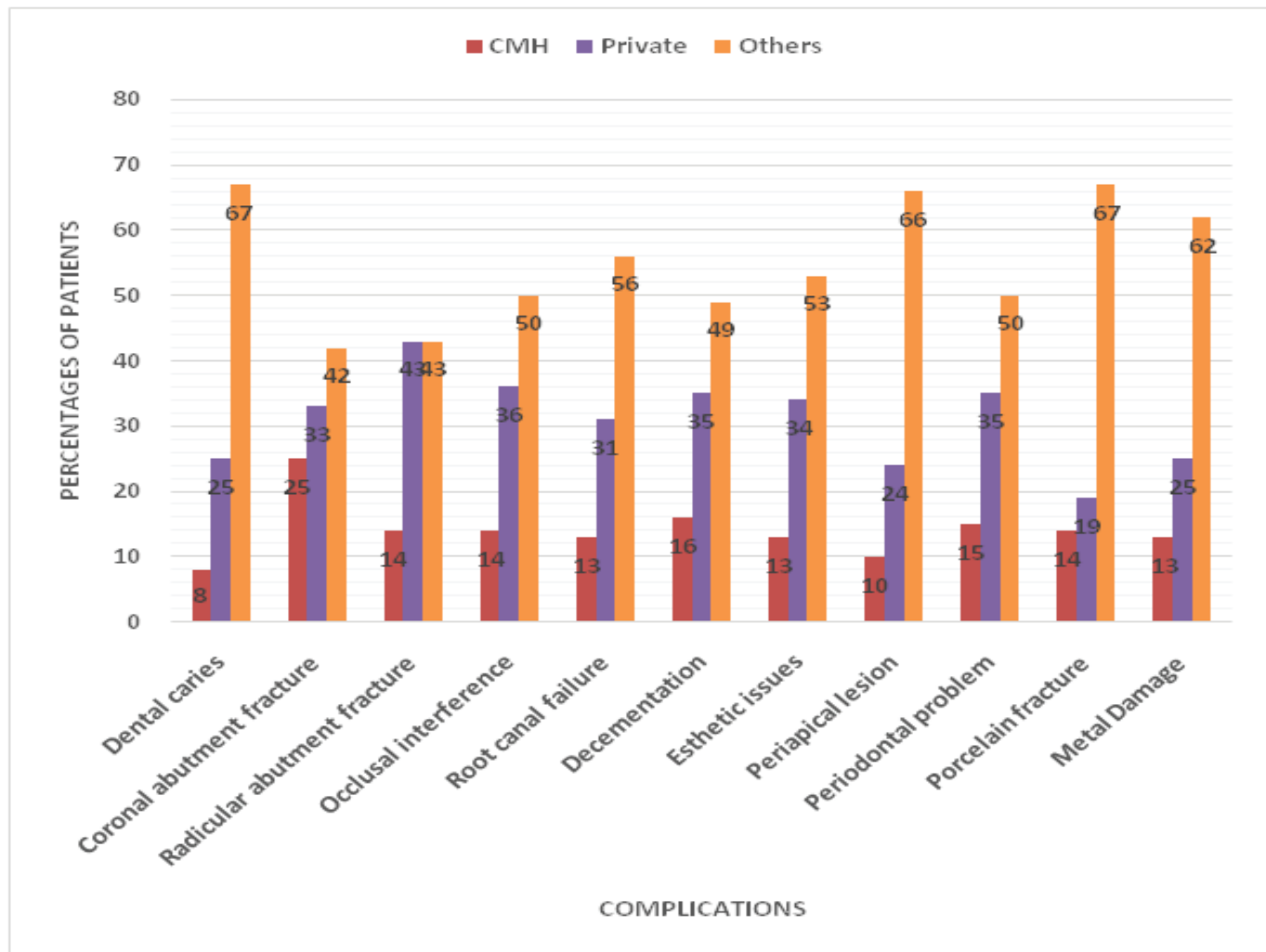
The study participants were distributed in terms of type of fixed dental prosthesis being used i.e. crown or bridge, materials used for fixed prosthesis and location of prosthesis. Almost 183(83%) participants had porcelain fused to metal (PFM) prosthesis and 133(60%) of prosthesis were in posterior segments of the mouth (Table-I).

**Table-I:** Distribution of prosthesis according to type, materials and location (n=220)

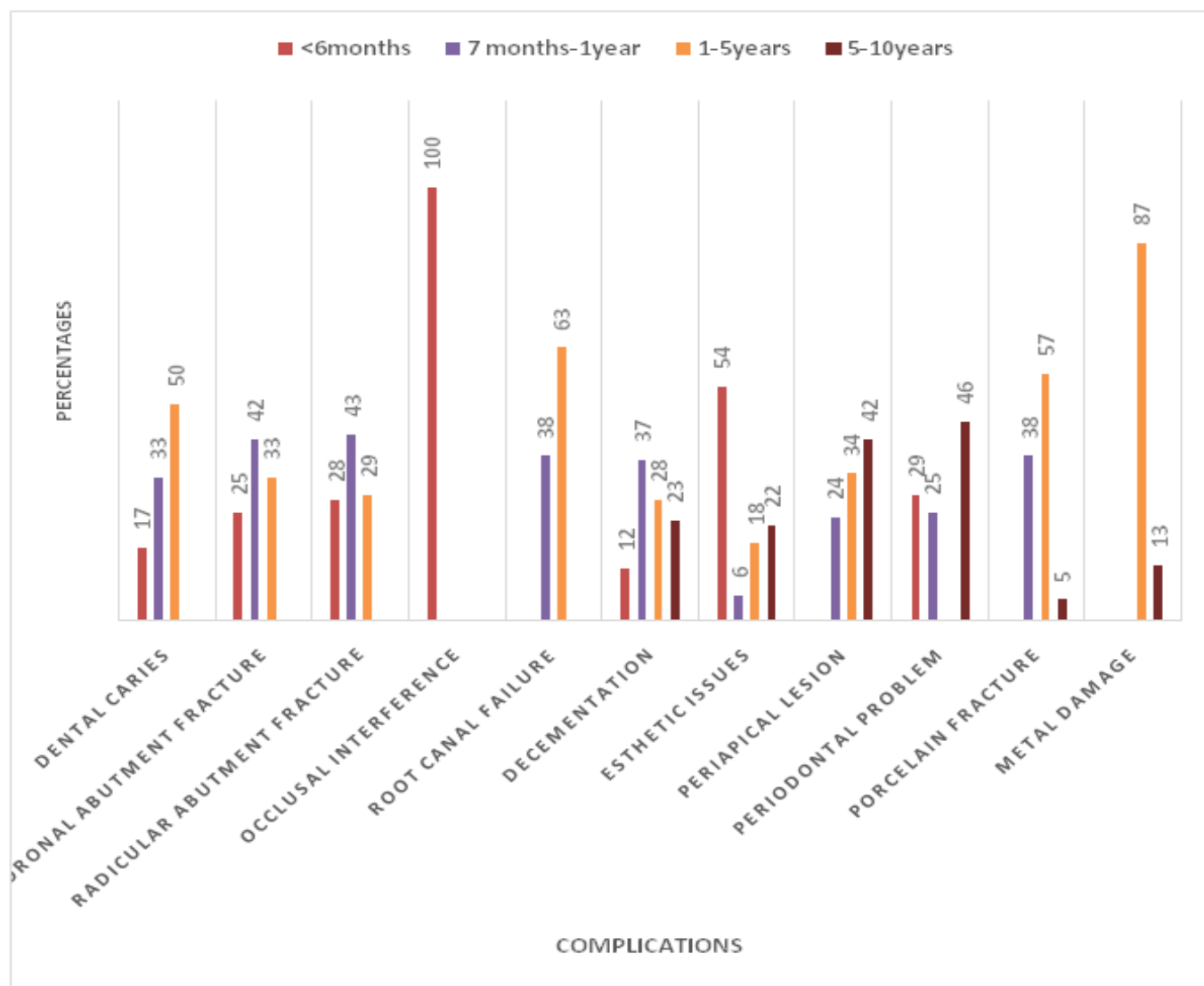
Type of prosthesis		Materials used			Location	
Crown	Bridge	Acrylic	Metal	Porcelain fused to metal	Anterior	Posterior
115(52.27%)	105(47.72%)	14(6.36%)	23(10.45%)	183(83.18%)	87(39.54%)	133(60.45%)

**Table-II:** Association between type of prosthesis, materials used in prosthesis and prosthesis related complications

Type of Complications	Type of Prosthesis			Material used in prosthesis			P value
	Crown	Bridge	P value	Acrylic	Metal	PFM	
Dental Caries	12	0	0.001	10	2	0	0.000
Coronal Abut Fra.	12	0		0	6	6	
Radicular Abut Fra.	7	0		0	0	7	
Occlusal interferenc	14	0		0	0	14	
Root canal Failure	9	7		0	5	11	
Decementation	25	18		0	6	37	
Esthetic Issues	9	23		0	0	32	
Periapical lesson	7	22		0	4	25	
Periodontal Proble	15	11		4	0	22	
Porcelain Fracture	5	16		0	0	21	
Metal Damage	0	8		0	0	8	



**Fig-1:** Complications associated with place of provision of prosthesis



**Fig-2:** Complications associated with duration of placement of prosthesis

Table-II shows the association between type of prosthesis, materials of prosthesis and related complication. It reports that complications like dental caries (10.5%), decementations of crowns (22%), coronal and/or radicular abutment fracture (10.5%), occlusal interferences (12%) and root canal failures (8%) were more significantly associated with patients who had previously acquired crowns as compared to bridges. Whereas esthetic issues (22%), periapical lesions (21%), porcelain fractures (15%), periodontal problems (10%) and metal damage (8%) were more commonly associated with patients who had previously acquired bridges as compared to crowns. These associations were found to be statistically significant ( $p=0.001$ ).

Figure-1 shows the relation between place of provision of prosthesis and associated complications. It shows that a significantly higher number of participants who got their fixed dental prosthesis from other sources i.e. paramedics, technicians, dental assistants or quacks developed dental caries, porcelain fracture, periapical lesions, metal damage, decementations, root canal failures and periodontal diseases.

Figure-2 shows the relation between duration of placement of prosthesis and associated complications. A significantly higher number of occlusal interferences, esthetic issues and periodontal lesions were associated with less than 6 months of use of the prosthesis. A greater number of coronal abutment fracture, radicular abutment fracture and root canal failure occurred after 6 months to 1 year of use of prosthesis and significantly higher number of metal damage, porcelain fractures and root canal failure were found amongst participants who had been using prosthesis for last 1 to 5 years.

## Discussion

The results of the study showed that complications like dental caries, coronal and/or radicular abutment fracture, occlusal interferences, root canal failures and decementations were more significantly associated with patients who had previously acquired crowns as compared to bridges. This finding is similar to studies by Owall et al and Eckerbom et al in Sweden where they found that a significant number of decementations and root and/or abutment fractures were associated with use of crowns as compared to bridges<sup>16,17</sup>. In this study, the result shows that decementation of crowns, dental caries, abutment fracture complications were more common in fixed dental prosthesis specially in crowns which is similar with the study by Tan k et al where they found that caries and decementations are the major complication for fixed dental prosthesis failure<sup>4</sup>. The results of present study are also in coherence with study by Valderhaug & Karlsen in Norway where they found that complications like decementations and abutment fractures are more significantly found amongst patients using crowns as compared to bridges<sup>18</sup>.

Results of the present study reveal that porcelain fractures and metal damage were present amongst patients who had been using prosthesis for the past 5 years which could be partly explained by fatigue of the materials used i.e. metal alloys, porcelain and acrylic. This finding is however different from the findings of several previous studies which have reported that survival of prosthesis decreased more sharply after 10 years of use<sup>19,20</sup>. The current study showed that a statistically significant number of periodontal problems, periapical lesions and decementations developed in patients who were using the prosthesis for more than 5 years which is in line with results of previous study by Scurria et al who reported that decementations and periapical lesions were more commonly found in patients using FDP for more than 5 years<sup>21</sup>. The most common complications in the current study were decementation of fixed dental prosthesis, esthetic issues and periapical lesions which is coherent with previous study conducted by Ghani and Memon where they found that decementation and periapical lesions were amongst the most commonly reported complications<sup>3</sup>. The uniqueness of this study is that although previous studies have identified the complications related to fixed dental prosthesis, they have not tried to explore the association of these complications with important factor like place of provision of the prosthesis especially in a country like Bangladesh where lot of sources other than registered dental practitioners are involved in carrying out dental procedures.

## Conclusion

The results of the present study showed that the most common complications of fixed dental prosthesis were dental caries, decementation of crowns, periapical lesions, esthetic problem, coronal or radicular abutment fracture on patients using the prosthesis for one to five years. The complications associated with use of fixed dental prosthesis like dental caries, root canal failures, decementations, periapical lesions and periodontal disease were more significantly associated with use of prosthesis that were fabricated by other sources rather than those acquired from CMHs and private dental care also in patients using prosthesis for 5 to 10 years. A sound diagnosis by specific radiograph, skilled clinical and laboratory procedures may improve the length of services produced by fixed dental prosthesis.

## References

1. Walton JN, Gardner FM, Agar JR. A survey of crown and fixed partial denture failures: Length of service and reasons for replacement. *J Prosthet Dent* 1986; 56(4):416-21.
2. Merriam Webster's Collegiate Dictionary. 10th ed. Springfield, MA: Merriam-Webster 1993:236.
3. Ghani F, Memon MR. Complications in Metal-Ceramic fixed dental prosthesis among patients reporting to a teaching dental hospital. *Journal of Liaquat University of Medical and Health Sciences* 2010; 9(1):17-22.
4. Tan K, Pjetursson BE, Lang NP et al. A systematic review of the survival and complication rates of fixed partial dentures (FPDs) after an observation period of at least 5 years. *Clin Oral Implants Res* 2004; 15(6):654-66.
5. Briggs P, Ray-Chaudhuri A, Shah K. Avoiding and managing the failure of conventional crowns and bridges. *Dent Update* 2012; 39(2): 78-80, 82-4.
6. Creugers NH, Kreulen CM. Systematic review of 10 years of systematic reviews in prosthodontics. *Int J Prosthodont* 2003; 16(2):123-7.
7. Shillingburg HT, Hobo S, Whitsett LD. *Fundamentals of fixed Prosthodontics*. 2nd ed. Chicago (IL): Quintessence Publishing Co 1981:115-9.
8. Koth DL. Full crown restorations and gingival inflammation in a controlled population. *J Prosthetic Dent* 1982; 48(6):681-5.
9. Silness J. Periodontal conditions in patients treated with dental bridges. The relationship between the location of the crown margin and the periodontal condition. *J Periodontol Res* 1970; 5(3):225-9.
10. Libby G, Arcuri MR, LaVelle WE et al. Longevity of fixed partial dentures. *J Prosthetic Dent* 1997; 78(2):127-31.
11. Sharma A, Rahul GR, Poduval ST et al. Removal of failed crown and bridge. *J Clin Exp Dent* 2012; 4(3):e167-72.

12. Glantz PO & Nilner K. Patient age and long term survival of fixed prosthodontics. *Gerodontology* 1993; 10(1):33-9.
13. Lindquist E & Karlsson S. Success rate and failures for fixed partial dentures after 20 years of service: Part I. *Int J Prosthodont* 1998; 11(2):133-8.
14. Palmqvist S & Swartz. Artificial crowns and fixed partial dentures 18 to 23 years after placement. *Int J Prosthodont* 1993; 6(3):279-85.
15. Oral health surveys: Basic methods, 4th ed. Geneva, WHO 1979.
16. Öwall B, Cronström R & René N. Prosthodontic claims in the Swedish Patient Insurance Scheme. *Acta Odontol Scand* 1992; 50(6):365-74.
17. Eckerbom M, Magnusson T & Martinsson T. Prevalence of apical periodontitis, crowned teeth and teeth with posts in a Swedish population. *Endod Dent Traumatol* 1991; 7(5):214-20.
18. Valderhaug J & Karlsen K. Frequency and location of artificial crowns and fixed partial dentures constructed at a dental school. *J Oral Rehabil* 1976; 3(1):75-81.
19. Leempoel PJ, Käyser AF, Van Rossum GM et al. The survival rate of bridges. A study of 1674 bridges in 40 Dutch general practices. *J Oral Rehabil* 1995; 22(5):327-30.
20. Creugers NH, Käyser AF, van 't Hof MA. A meta-analysis of durability data on conventional fixed bridges. *Community Dent Oral Epidemiol* 1994; 22(6):448-52.
21. Scurria MS, Bader JD, Shugars DA. Meta-analysis of fixed partial denture survival: Prostheses and abutment. *J Prosthetic Dent* 1998; 79(4):459-64.