

Paraneoplastic Polymyositis in a Patient of Myelofibrosis

Razzak MA¹, Khandaker J², Islam SMJ³

DOI: <https://doi.org/10.3329/jafmc.v15i1.48661>

Abstract

Polymyositis is a rare rheumatologic disorder. Exact cause is unknown but autoimmunity, genetic and environmental factors like infection and drugs may be responsible. It may be a primary autoimmune disease, associated with other autoimmune diseases or underlying malignancy. There is two-way relationship between polymyositis and malignancy. Patients with polymyositis and dermatomyositis has increased chance of various malignancies. On the other hand polymyositis and dermatomyositis may be a paraneoplastic manifestation of some malignancies like carcinoma lung, ovary, breast, pancreas, colon, lymphoma, MDS and myeloproliferative disorders. We have diagnosed a case of polymyositis in a patient of Myelofibrosis (MF). The patient presented with inflammatory myopathy affecting proximal muscles of the limbs, neck muscles, laryngeal and pharyngeal muscles. Muscle enzymes were markedly elevated, EMG and MRI were in favour of inflammatory myopathy. Muscle biopsy showed inflammatory infiltrates in muscles mostly by T- cells with myonecrosis, degeneration and regeneration without vasculopathy and perivascular change. Primary polymyositis and other autoimmune diseases were excluded by absence of relevant autoantibodies. So he was diagnosed as a case of paraneoplastic polymyositis.

Key-words: Polymyositis, Myopathy, Paraneoplastic, Myelofibrosis, Muscle biopsy, Azathioprine.

Introduction

Polymyositis (PM) is acquired, chronic inflammatory myopathy of unknown etiology. The clinical hallmark of this disease is symmetrical proximal muscle weakness. In severe cases there may be associated dysphagia and cardiorespiratory complications. Polymyositis is uncommon autoimmune connective tissue disease. The reported annual incidence in various populations ranges from 2 to 10 new cases per million persons¹. The cause may be immunological or may be associated with malignancy. The malignancies associated with PM are nasopharyngeal cancer, lung cancer, breast cancer, ovarian cancer, non-Hodgkin's lymphoma, MDS and bladder cancer, amongst others². Very rarely it may be associated with myelofibrosis (MF). We have diagnosed a case of paraneoplastic polymyositis related to myelofibrosis. This is the first reported case in Bangladesh. We are publishing the case report to develop awareness amongst the physician regarding this rare disease.

Case report

A 60-year-old man, known case of primary myelofibrosis, DM, HTN and CKD developed weakness of proximal muscles of all four limbs and weakness of neck muscles associated with myalgia, weight loss and fatigability for 02 months. It was associated with

dysphagia and dysphonia. He developed fever, productive cough and shortness of breath for 02 weeks. There was no history of arthritis, skin rash, drooping of eyelids or any diurnal variation of muscle weakness. For myelofibrosis he received Thalidomide, Hydroxyurea, blood transfusion several times during last 06 years. His blood pressure and diabetes were under control by antihypertensive and oral hypoglycemic agents. He was also getting symptomatic and supportive treatment for CKD.

Clinically he was anemic, febrile and mildly dyspneic. His muscle power in limbs 2-3/5 with tenderness in arms and thighs. He had bilateral creps, huge splenomegaly and moderate hepatomegaly. Basing on history and clinical findings he was provisionally diagnosed as a case of polymyositis and aspiration pneumonia. He was thoroughly investigated. His blood CBC revealed Hb% -8.50 g/dL, TLC- 14.2 x10⁹/L, platelet - 58 x10⁹/L. His FBS- 5.7 mmol/L, 2HABF-8.0 mmol/L, serum creatinine- 1.5mg/dL, serum CPK- 4910 U/L, aldolase-18.6 U/L, LDH- 1434 U/L, AST- 133 U/L and serum electrolytes were normal. His CXR showed opacities in both lower lobes and CT scan (Figure-1) of chest revealed bilateral consolidation, pleural effusion, cardiomegaly and mild pericardial effusion. His immunologic marker e.g, RA, ANA, Anti ds-DNA, Anti Jo-1, Anti Mi-2 antibody and ENA profile were negative. His EMG (Figure-2) showed low amplitude, short duration, polyphasic action potential with spontaneous fibrillary wave suggestive of inflammatory myopathy. NCS showed mixed sensory motor peripheral neuropathy. His MRI of thigh muscles (Figure-3) revealed intensity changes favouring myositis more marked in adductor group. Muscle biopsy (Figure-4) showed infiltration of inflammatory cells mostly T cells in epimysial distribution, but there was no evidence of small vessel damage or perivascular inflammatory infiltrate. Immunohistochemistry showed infiltrated lymphocytes are CD-3 positive and CD-20 negative that goes in favour of PM (Figure-5).

Therefore, after exclusion of primary polymyositis and other rheumatologic diseases, with all probability he was diagnosed as a case of paraneoplastic polymyositis due to primary myelofibrosis. Paraneoplastic antineuronal markers (anti Hu, Yo, Ri, Ma-2, CRMP-5, amphiphysine antibody) could further support the diagnosis but was not done due to unavailability in Bangladesh.

His pneumonia was treated with broad spectrum antibiotic, diabetes was controlled with insulin and Hydroxyurea was stopped. Other symptomatic and supportive care were continued. He was given Inj. Methyl prednisolone I/V daily for 5 days followed by oral prednisolone. Tab. Azathioprine was added after control of pneumonia. Counselling, physiotherapy and rehabilitation

1. **Brig Gen Md. Abdur Razzak**, MBBS, MCPS, FCPS, APLAR Fellow in Rheumatology, Chief Physician, CMH, Dhaka (*E-mail*: razzakprm@yahoo.com) 2. **Maj Jesmin Khandker**, MBBS, Trainee in Medicine, AFMI, Dhaka 3. **Col Sk Md Jaynul Islam**, MBBS, DCP, MCPS, FCPS (Histopath), Classified Specialist in Pathology, AFIP, Dhaka.

therapy were given. But his response was not satisfactory. His peripheral neuropathy may be a paraneoplastic manifestation or due to effects of DM or cytotoxic drugs. Pneumonia was due to immunosuppression and weakness of muscles of deglutition and respiration leading to aspiration.

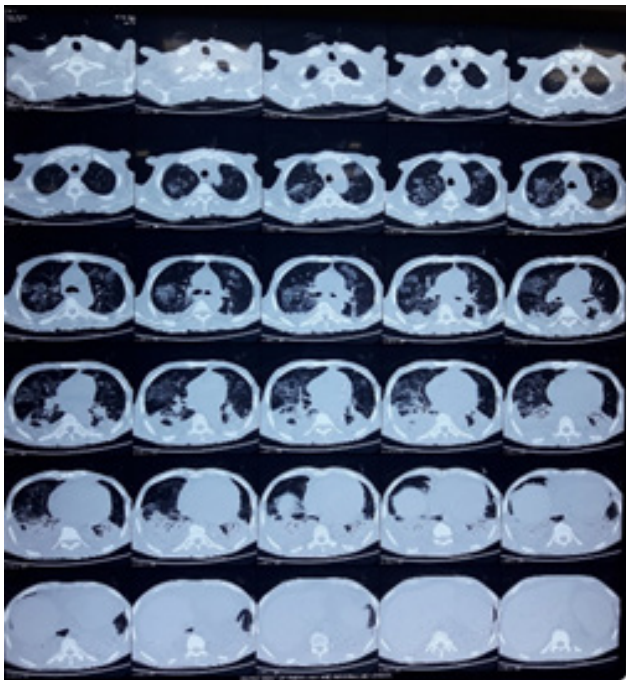


Figure-1: CT scan of chest

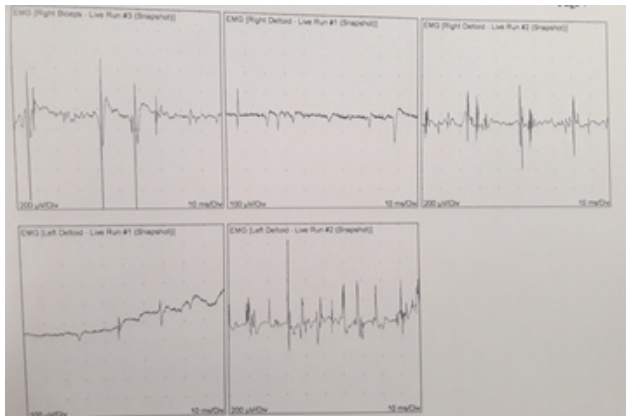


Figure-2: NCS and EMG study

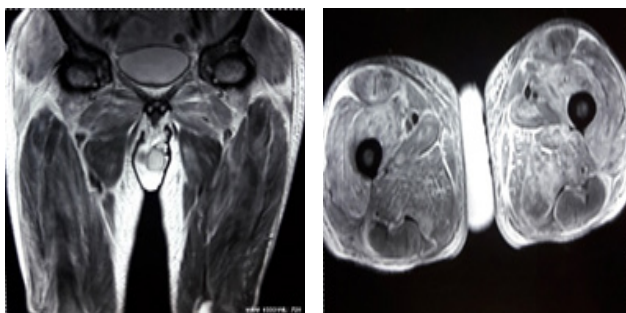


Figure-3: MRI of thigh muscles

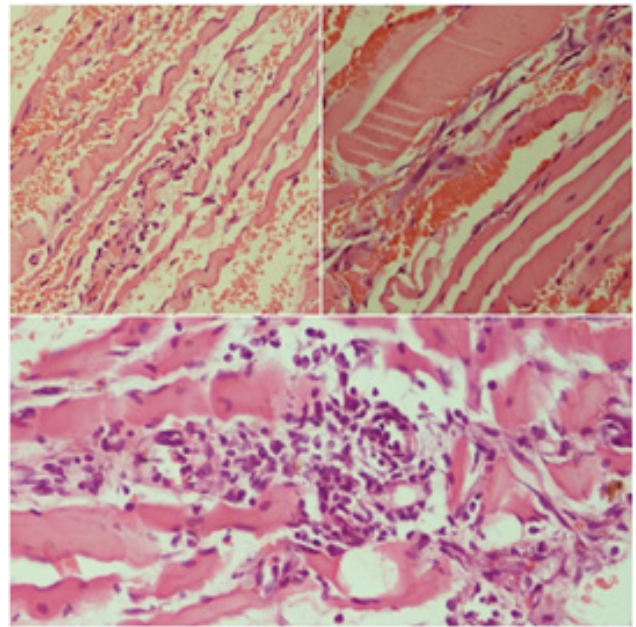


Figure-4: Muscle biopsy

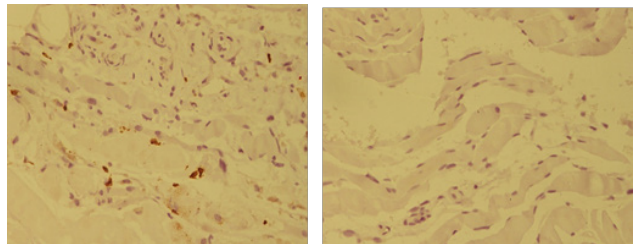


Figure-5: Immunohistochemistry for CD-3 and CD-20

Discussion

Polymyositis (PM) and dermatomyositis (DM) are characterized by chronic inflammation of skeletal muscle and are manifested, in their classic presentation, by proximal muscle weakness accompanied by elevations of the serum creatine kinase (CK) typical electromyography (EMG) changes with polyphasic potentials and muscle biopsy findings of a necrotizing, inflammatory process³. DM is distinguished from PM by a typical rash, usually red, scaly and plaque-like, over the knuckles, wrists, elbows, knees and ankle malleoli and violaceous lesions in the periorbital and trunk area⁴. These diseases are of unknown etiology and relatively rare but have been associated with a host of inciting agents, from infections⁵ to vaccines⁶ to malignancies⁷ and involve a multitude of immunological abnormalities⁸. Bohan and peter has described a diagnostic criterion⁹ to diagnose polymyositis as follows: 1) Progressive symmetrical proximal muscle weakness. 2) Elevated level of muscle enzymes. 3) An abnormal finding in electromyography. 4) An abnormal finding in muscle biopsy.

Patients with polymyositis may present with proximal myopathy, systemic features such as fever, malaise, weight loss, arthralgia, dyspnea, dysphagia, dysphonia, Raynaud's phenomenon, arrhythmia etc. It may be associated with different types of malignancy, especially lung cancer in men and ovarian cancer in female. Other malignancy like colonic, nasopharyngeal,

gastric carcinoma and lymphoma may be associated with PM. Connective tissue diseases like SLE, systemic sclerosis, rheumatoid arthritis etc can be present as well¹⁰. Therefore, polymyositis and dermatomyositis may present in isolation or may be associated with malignancy, which is very rare. There are few cases of primary myelofibrosis associated with PM worldwide¹¹. To the best of our knowledge, this is the first case of paraneoplastic polymyositis associated with primary myelofibrosis diagnosed in Bangladesh.

Autoimmunity is a common theme of both PM and MF. PM is a known autoimmune inflammatory myopathy and MF is associated with increased autoantibody production and circulating immune complexes^{11,12}. Additionally, the association between autoimmune disorders and idiopathic MF has been reported in 10–14% of cases^{13,14}. This case of PM presents the possibility of an immune paraneoplastic mechanism associating primary MF. Regenerating muscle cells in myositis have been observed to express antigens similar to cancer tissue¹⁵. In the setting of hematologic malignancy, a paraneoplastic immune response may inadvertently target muscle tissue leading to PM. Immunosuppression with concurrent treatment of the underlying malignancy is indicated in the setting of paraneoplastic PM. First-line immunosuppressive therapy often includes prednisone. Prior cases of primary myelofibrosis have shown response to azathioprine and prednisone regimens¹². However, as seen in this case, paraneoplastic PM may demonstrate poorer response to treatment than primary PM. High dose intravenous steroids have been documented as a potential second-line therapy¹⁶. IVIG and plasmapheresis has also been shown to be beneficial in resistant cases of PM^{17,18}. Prior case reports have documented resolution of PM after treatment of underlying neoplasm. Natural history of the disease shows spontaneous remission in 20% cases. 5 years survival in 85% cases is seen. Prognosis is better if cause is immunological, presentation is in isolation, early presentation, young age and absent anti synthetase antibody. Prognosis is poor if it is associated with malignancy and depends on the prognosis of the underlying disease.

Conclusion

Primary PM is a rare disease. Very rarely it may occur as a paraneoplastic manifestation of malignant disease. According to international literatures PM is a extremely rare association of MF. High index of suspicion, adequate knowledge & experience is needed to diagnose such rare condition. Early diagnosis and prompt treatment of underlying malignancy & PM will improve the prognosis.

References

- Koh ET, Seow A, Ong B et al. Adult onset polymyositis/ dermatomyositis: clinical and laboratory features and treatment response in 75 patients. *Ann Rheum Dis* 1993; 52: 857-61.
- Hill CL, Zhang Y, Sigurgeirsson B et al. Frequency of specific cancer types in dermatomyositis and polymyositis: A population-based study. *Lancet* 2001; 357(9250): 96–100.
- Mastaglia FL & Ojeda VJ. Inflammatory myopathies: Part 2. *Ann Neurol* 1985, 17:317-23.
- Kagen LJ. Dermatomyositis and polymyositis: clinical aspects. *Clin Exp Rheumatol* 1984; 2: 271-77.
- Whitaker JN. Inflammatory myopathy: A review of etiologic and pathogenetic factors. *Muscle Nerve* 1982; 5:573-92.
- Ehregut W. Dermatomyositis and vaccination. *Lancet* 1978; 2:1040-1.
- Lakhanpal S, Bunch TW, Ilstrup DM et al. Polymyositis/dermatomyositis and malignant lesions: Does an association exist? *Mayo Clin Proc* 1986, 61:645-53.
- Dustoor MM, Ransohoff R & Segal AM. Disordered immune regulation in autoimmune rheumatic diseases. *Cleve Clin Q* 1986, 53:241-48.
- Bohan A & Peter JB. Polymyositis and dermatomyositis. Part I. *N Engl J Med* 1975, 292:344-47.
- Dalakas MC. Inflammatory muscle diseases. *N Engl J Med* 2015; 372:1734.
- Taskapan H, GURSOY S, CETIN M, et al. Development of dermatomyositis in a patient with primary myelofibrosis. *Hematology* 2001; 6(2):131–34.
- Ito A, Umeda M et al. A case of dermatomyositis associated with chronic idiopathic myelofibrosis. *Rinsho Shinkeigaku* 2006; 46(3):210–13.
- Enright H and Miller W. Autoimmune phenomena in patients with myelodysplastic syndromes. *Leukemia & Lymphoma* 1997; 24:483–89.
- Camos M, Arellano-Rodrigo E, Abell DO et al. Idiopathic myelofibrosis associated with classic polyarteritis nodosa. *Leukemia and Lymphoma* 2003; 44(3):539–41.
- Casciola-Rosen L, Nagaraju N, Plotz P et al. Enhanced autoantigen expression in regenerating muscle cells in idiopathic inflammatory myopathy. *Journal of Experimental Medicine* 2005; 201(4):591–601.
- I. Arshad and D. Barton. Dermatomyositis as a paraneoplastic phenomenon in ovarian cancer. *BMJ Case Reports* 2016; Article ID 215463, 2016.
- Dalakas MC. Intravenous immunoglobulin in autoimmune neuromuscular diseases. *Journal of the American Medical Association* 2004; 291(19):2367–75.
- Aslanidis SA, Pyrpasopoulou A, Kartali N et al. Successful treatment of refractory rash in paraneoplastic amyopathic dermatomyositis. *Clinical Rheumatology* 2007; 26(7):1198–1200.