

### TASTE DISTURBANCE AFTER TONSILLECTOMY: A RARE BUT SIGNIFICANT COMPLICATION- A CASE REPORT

Kabir MA<sup>1</sup>, Afsana SD<sup>2</sup>

#### Abstract

**Introduction:** Tonsillectomy is the most commonly performed procedure and generally regarded as a safe surgery. Taste disturbance is a very rare complication after tonsillectomy, with very few reports in the literature. The most possible cause of this rare complication is direct or indirect damage to the glossopharyngeal nerve or its lingual branch (LBGN).

**Aim:** To report a very rare complication of the most commonly performed procedure i.e. tonsillectomy.

**Case Report:** The case is a 32 years old lady who complained of taste disturbance following tonsillectomy that was performed for chronic tonsillitis. As treatment patient was given Trifluoparazine Hydrochloride a Phenothiazine derivatives and Vit B<sub>6</sub> + Vit B<sub>12</sub>. Patient recovered after 4 months postoperatively.

**Conclusion:** Tonsillectomy should be performed with minimal trauma to the tonsillar bed to avoid injury to the Glossopharyngeal nerve or its lingual branch (LBGN) and all patients should be informed of the risk of post-operative taste disturbance after tonsillectomy.

**Key-words:** Tonsillectomy, Glossopharyngeal nerve, Lingual Branch of Glossopharyngeal Nerve (LBGN), Dysgeusia (sense of abnormal taste), Trifluoparazine Hydrochloride (Phenothiazine derivatives).

#### Introduction

Tonsillectomy is a commonly performed surgical procedure and generally regarded as a safe surgery. Even though it has its own set of complications, disturbance in taste following surgery should be considered rare. Post operative pain, bleeding,

swelling and discomfort last a few days, or a few weeks at most. But, for a slim minority of patients, the complication of post-tonsillectomy taste disorder can linger much longer. Taste disturbance is an unusual complication after tonsillectomy, with very few reports in the literature. The possible causes of this rare complication are: (i) direct or indirect damage to the Glossopharyngeal nerve or its lingual branch (LBGN), (ii) lack of dietary zinc and (iii) habitual drug intake.

#### Case history

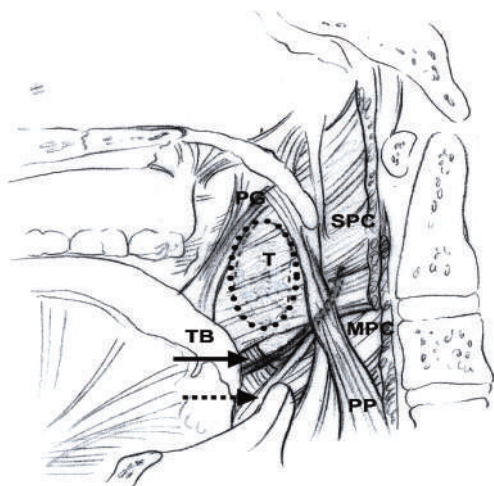
The subject was a 32 years old lady, who complained of taste disturbance following tonsillectomy that was performed for chronic tonsillitis on 10 Aug 2012. Surgery was undertaken under GA. During surgery, hypertrophic tonsils were found to be sited deeply into the tonsillar bed, especially at the lower pole of both tonsils. Tonsils were removed by dissection method. After the tonsils were dissected with an elevator, the lower poles were clamped with a Negus and silk ligatures were applied. Bleeding was controlled with immediate gauze pressure and use of electrocautery. The surgery was performed with minimal bleeding and without any complication. Patient noticed taste disturbance after tonsillectomy from post operative night. She almost tasted nothing and all fluids and solid foods tasted bitter or metallic. She also lost few weight. The patient had no pain, dysphagia or any other post tonsillectomy complications. Her physical examination revealed normal healing of tonsillar bed. The gag response, speech, swallowing, status and positions of soft palate, uvula and tongue were all normal. Her serum Zinc level as well as the other hematological parameters were found to be normal. She did not take any drug habitually that could affect her sense of taste. From 10th POD, patient was treated with Tab Zinc Gluconate 50 mg thrice daily,

1. **Maj Misbah Al Kabir**, Graded Specialist in ENT & Head Neck Surgery, BNS PATENGA, New Mooring, Chittagong;
2. **Maj Sultana Dil Afsana**, LMO, BNS PATENGA, New Mooring, Chittagong.

Tab Neuro B twice daily and rinsing mouth with milk of magnesia but no significant improvement was noticed after 2 months post operatively. Later on patient was evaluated by Neurophysician and from first week of Jan 2013 she started taking Tab Telazine 1 mg (Trifluoparazine Hydrochloride: a Phenothiazine derivatives) once daily and Tab Neurocare (Vit B<sub>6</sub> + Vit B<sub>12</sub>) twice daily. Patient's taste sensation started to recover after 2 weeks of taking above two drugs and almost complete recovery occurred after 2 months of treatment. At present, patients taste sensation is completely normal.

### Discussion

Taste disturbance is an unusual complication<sup>1,2,3,4,7,8</sup> of tonsillectomy. There are very few reports of it in the literature. Depending on various studies, this complaint occurs anywhere from 0.3% to as high as 9% of tonsillectomy cases<sup>4,5,6</sup>. The possible causes of this rare complication are: (i) direct or indirect damage to the glossopharyngeal nerve or its lingual branch (LBGN)<sup>7,8</sup>, (ii) lack of dietary zinc<sup>7,11</sup> and (iii) habitual drug intake<sup>7,13</sup>. In a recently published literature, it has been reported that thermal injury to the Glossopharyngeal nerve by electrocautery could also be a possible cause for this complication<sup>8</sup>. The lingual branch of the glossopharyngeal nerve (LBGN) can be injured during tonsillectomy, leading to taste disturbance. The topographical relationship between the palatine tonsils, the muscle layer of the tonsillar bed and the LBGN has been reported in the literature<sup>7,8,9,10</sup> as shown in Fig-1.



**Fig-1:** Anatomy of the right tonsillar fossa displaying the location of the LBGN. PG (palatoglossus) muscle; PP (palatopharyngeus) muscle; MPC (middle pharyngeal constrictor) muscle; TB (tongue base).

Especially in adults it is difficult to separate the tonsillar capsule from the pharyngeal bed when repeated attacks of inflammation have made their union almost fibrous. So during tonsil removal, the structures in the tonsillar bed could be injured during a tonsillectomy procedure. Anatomy of the right tonsillar fossa displaying the location of the LBGN (solid arrow) just superior to the stylohyoid ligament (dashed arrow) is shown in Fig-1. The LBGN is exposed in the inferior pole of the tonsillar fossa secondary to inadequate coverage by the superior constrictor muscle (SPC). The dashed oval area represents the location of the tonsil (T), and, with extensive soft tissue excision at the inferior tonsillar pole, the LBGN is susceptible to injury. This is the proposed location of injury to the LBGN during tonsillectomy.

Attempts to clamp tonsillar branches of the lingual or facial arteries supplying the inferior pole of the tonsil can damage the Glossopharyngeal nerve and/or its lingual branches. Depending on above findings, possible indirect damage to the LBGN was suspected as the cause of taste disturbance in our case. As her gag reflex, swallowing, speech, movement and positions of the soft plate and uvula were normal the main trunk of the Glossopharyngeal nerve was thought to be intact. Treatment for dysgeusia as a result of nerve damage is limited because the exact neurologic mechanism is unknown.

Recovery is therefore restricted to the natural healing process and physical regeneration of neural fibers in the periphery and gustatory tract is often slow and rarely complete. One treatment strategy is flavor enhancement<sup>12</sup> that increases the appeal of nutritional foods and thus alleviates nutritional deficiencies. Regardless of the etiology, most cases of post-tonsillectomy dysgeusia spontaneously resolve within a few months without any specific intervention. But some may last longer. However, there are a few things that might help accelerate normal taste recovery<sup>5</sup> including: stopping all unnecessary medications, Zinc Gluconate 50mg 3 times per day, rinsing mouth with watered down milk-of-magnesia, chewing non-mint flavored gum. It was not clearly established whether the recovery in our patient was spontaneous or was an effect of Trifluoparazine Hydrochloride (Phenothiazine derivatives) -1mg once daily and Vit B<sub>6</sub> + Vit B<sub>12</sub> treatment even though otolaryngologist can try for it if required.

## Conclusion

Possible indirect injury to the lingual branch of the Glossopharyngeal nerve during tonsillectomy is suspected as the cause of taste disturbance which may or may not be completely reversible. So, tonsillectomy should be performed with minimal trauma to the tonsillar bed and the patient should be informed of the risk of post-operative taste disturbance. Measuring the patient's taste threshold and serum Zinc level preoperatively and obtaining a thorough drug history, including details of non-prescription medications habitually taken by the patient are also important. More studies are required to establish Trifluoparazine Hydrochloride (Phenothiazine derivatives) as a treatment option.

## References

1. Collet S, Eloy P, Rombaux P, Bertrand B. Taste disorders after tonsillectomy: case report and literature review. *Ann Otol Rhinol Laryngol*. 2005 Mar; 114 (3):233-6.
2. Tomita H, Ohtuka K. Taste disturbance after tonsillectomy. *Acta Otolaryngol Suppl*. 2002; (546):164-72.
3. Michael R. Goins, MD; Dimitri Z. Pitovski, MD. Posttonsillectomy taste distortion: a significant complication. *Laryngoscope*. 2004 Jul; 114(7):1206-13.
4. Tomofuji, Seiichi; Sakagami, et al Taste disturbance after tonsillectomy and laryngomicrosurgery. *Auris Nasus Larynx* vol. 32 issue 4 December, 2005. p.381-6.
5. Taste-changes-fter-tonsillectomy from <http://fauquierent.blogspot.com/2012/11/taste-changes-after-tonsillectomy.html>.
6. Arnhold-Schneider M, Bernemann D. Incidence of taste disorders following tonsillectomy. *HNO* 1987;35:195-8.
7. Taste disturbance after tonsillectomy. Ohtsuka K, Tomita H, Yamauchi Y, Kitagoh H. *Jibiinkoka Gakkai Kaiho (J Otolaryngol Jpn)* 1994;97:1079-88.
8. Cem Uzun, M.D., Mustafa Kemal Adali, M.D., Ahmet Rifat Karasalioglu, M.D. Unusual complication of tonsillectomy: taste disturbance and the lingual branch of the glossopharyngeal nerve. *The Journal of Laryngology & Otology*, April 2003, Vol. 117, pp. 314-7.
9. Ohtsuka K, Tomita H, Murakami G Anatomy of the tonsillar bed: Topographical relationship between the palatine tonsil and the lingual branch of the glossopharyngeal nerve.. *Acta Otolaryngol* 2002; Suppl 546: 99–109.
10. Todd TW, Fowler RH. The muscular relationships of the tonsil. *Am J Anat* 1927; 40: 355-71.
11. Bicknell JM, Wiggins RV. Taste disorder from Zinc deficiency after tonsillectomy. *West J Med* 1988;149:457-60.
12. Schiffman SS, Warwick ZS. Effect of flavor enhancement of foods for the elderly on nutritional status: food intake, biochemical indices, and anthropometric measures. *Physiol Behav* 1993; 53:395-402.
13. Case of ageusia from a variety of causes. Deguchi K, Furuta S, Imakiire T, Ohyama M. *J Laryngol Otol* 1996;110:598-601.