

PRIMARY HYDATID CYST OF KIDNEY

Ahmed SS¹, Islam SMJ², Baqui MN³, Huda M⁴, Ali SM⁵**Introduction**

Hydatid cyst of the kidney is a very rare condition caused by the larval stage of *Echinococcus granulosus*. The incidence of renal involvement is about 2% of all hydatid disease in humans¹. It is endemic in parts of the Middle East, South America, Australia, New Zealand, and Alaska². Isolated renal involvement is even rarer. The average patient age is about 30 years. It is more common in women³. Here, a case of isolated primary hydatid cyst of the kidney is presented, that was evaluated clinically and investigated by x-ray, abdominal ultrasonography, intravenous urography and finally confirmed by histopathology.

Case report

A 45 year male presented with mild pain in the right lumbar region for one year and occasional passage of grape skin like structures (ruptured daughter cysts) in urine. The routine laboratory findings revealed high ESR (80 mm in first hour) with slight increase in serum creatinine (1.4 mg/dl). Routine urine examination was normal. X-ray of the kidney and urinary bladder region showed no abnormality. Ultrasonography of the kidney and urinary bladder region revealed normal left kidney while the right kidney was enlarged (11.3x4.9 cm). Pelvicalyceal system of right kidney was dilated. The cortical echogenicity was increased and corticomedullary pattern was distorted. A hypoechoic area was seen measuring 5.0x2.8 cm having inhomogenous echotexture at the lower pole of the right kidney. Proximal part of the ureter was dilated. Intravenous urography revealed non-functional right kidney. Nephrectomy was done. Examination of the nephrectomy specimen (Fig 1) revealed grossly thinned out cortex with dilated pelvicalyceal system and the dilated spaces were filled with whitish grape like cyst of different sizes.

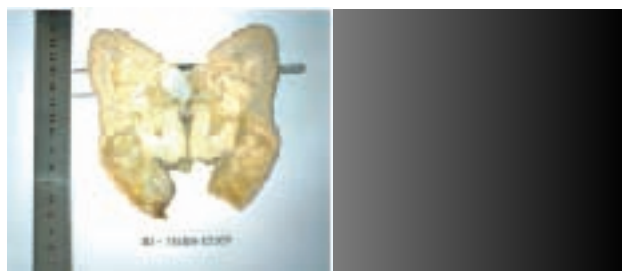

Fig-1: Gross examination of the kidney showing grape skin like structures

Crush smear of the grape like cystic structure revealed scolices and hooklets of *Echinococcus granulosus*. Histological sections revealed typical picture of hydatid cyst (Fig 2).

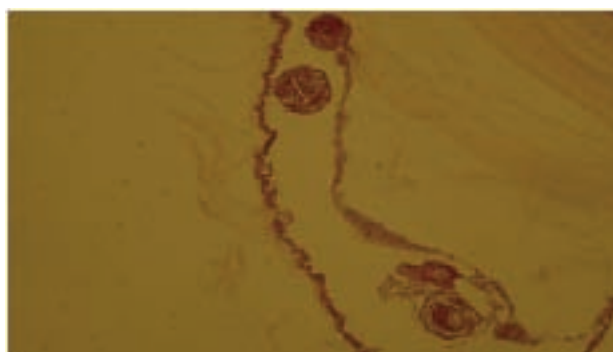


Fig-2: The wall of the hydatid cyst has a laminated membrane and a germinal layer with scolices

Discussion

Humans are an intermediate host of *Echinococcus granulosus* through ingestion of water or vegetables contaminated by its eggs⁴. The ovum digested in the duodenum and the parasitic embryos pass through the intestinal wall to reach the portal venous system; therefore, the most frequently involved organ is the liver⁴. Secondary involvement resulting from hematogenous dissemination and can be seen in almost any anatomic location. Isolated hydatid disease of the kidney is rare conditions that can be challenging to diagnose⁵. The majority of hydatid cyst of the kidney are primary. Primary hydatid cyst of the kidney may begin in the renal substance proper or in the peripheral tissues with involvement of the kidney proper secondarily. The cyst may be intra-renal and infra-capsular. After entry the cyst may be latent for years. Sometimes twenty to thirty years may pass before the symptom appears. Presenting complaints are typically of flank mass, haematuria and pain⁶, occasionally as a result of rupture of the cyst into collecting system the patient pass typical "grape skins" (collapsed daughter cyst) like material in the urine⁷. Plain film, intravenous urography, selective angiography and ultrasonography can contribute very much to the diagnosis. Cystoscopy and retrograde pyelography is also very helpful. Recently, magnetic resonance imaging

1. Dr. Syed Salahuddin Ahmed MBBS, PhD, Assistant Professor of Pathology, NITOR, Dhaka; 2. Lt Col Sk Md Jaynul Islam MBBS, DCP, MCPS, FCPS, Associate Professor of Pathology, AFMC, Dhaka; 3. Dr. Muhammad Nazmul Baqui MBBS, MD, Department of Pathology, SSMC, Dhaka; 4. Dr. Mahmudul Huda MBBS, Resident, Pathology, BSMMU, Dhaka; 5. Professor Syed Mukarram Ali MBBS, MRCPATH, FRCPATH, Professor of Pathology, BCPS and Chief Consultant Pathology, Delta Hospital Limited, Dhaka.

(MRI) has been gaining popularity for investigating hydatid disease involving soft tissues⁸.

In general, surgery is the treatment of choice in renal hydatid cyst. Kidney sparing surgery (removal of the cyst with pericystectomy) is possible in most cases (75%). Nephrectomy (25% of cases) must be reserved for destroyed kidney⁹. Very few cases of laparoscopic removal of renal hydatid cyst are reported. Finally for a non-functioning grossly enlarged kidney hydatid cyst should be in the differential diagnosis.

References

1. Warren D, Johnson JR, Christopher W, et al. Parasitic disease of the genitourinary system. In: Walsh PC, Retik AB, Vaughan FD, editors. Campbell's Urology, volume 2. 8th ed. Philadelphia: Elsevier Saunders; 2002. p.786-788.
2. Vuitton DA. The WHO Informal Working Group on Echinococcosis. Coordinating Board of the WHO-IWGE. *Parassitologia* 1997; 39:349-353.
3. Gogus O, Beduk, Topukcu Z. Renal hydatid disease. *Br J Urol* 1991;68:466-469.
4. Fazeli F, Narouie B, Firoozabadi MD, Afshar M, Naghavi A, Ghasemi-rad M. Isolated Hydatid Cyst of Kidney. *Urology* 2009; 73: 999-1001.
5. Yaycioglu O, Ulsan S, Gul U, et al. Isolated renal hydatid disease causing ureteropelvic junction obstruction and massive destruction of kidney parenchyma. *Urology* 2006; 67 (6) :15-17.
6. Saidi F. *surgery of Hydatid Disease*. Philadelphia: W.B. Saunders Co, 1976.
7. Hanies JG, Mayo ME, Allan TNK, Ansell JS. Echinococcal cyst of the kidney. *J Urol* 1977;117:788.
8. Claikens B, Van Hoe L, Vansteenbergen W. Images in clinical radiology. MRI features of hydatid disease. *JBR-BTR* 1999; 82:167.
9. Mongha R, Narayan S, Kundu A K. Primary hydatid cyst of kidney and ureter with gorss hydatiduria: A case report and evaluation of radiological features. *Indian J Urol* 2008 Jan-Mar; 24(1): 116-117.