

## DEVICE CLOSURE OF PATENT DUCTUS ARTERIOSUS IN COMPLICATED PATIENT

Begum NNF

### Abstract

**Introduction:** Congenital Rubella Syndrome is caused by the destructive action of the rubella virus on the fetus at a critical time in development. If the infection occurs at 0-12 weeks of conception, there is a 51% chance of effect on the infant. Along with eye problems, mental retardation, deafness, growth retardation and developmental delays, some patient who survive infection, takes birth with congenital heart disease. Patent ductus arteriosus (PDA) is the most commonly reported heart problem.

**Case Report:** Two cases of congenital rubella syndrome with large patent ductus arteriosus and severe pulmonary hypertension are reported here, whose PDA's were closed with Lifetech PDA occluder devices. One of them had multiple peripheral pulmonary stenosis which were also dilated with balloons. Both of them had interventions in same day.

**Key words:** Patent ductus arteriosus (PDA), congenital rubella syndrome, severe pulmonary hypertension

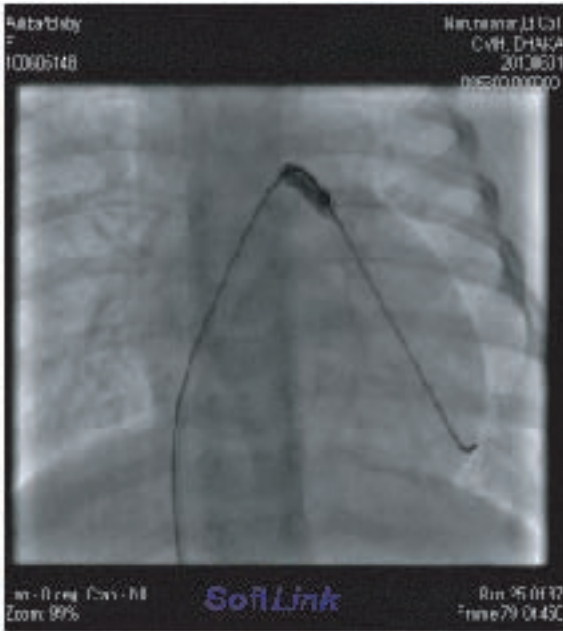
### Case report

**Case 1:** This girl was diagnosed as a case of congenital rubella syndrome with large patent ductus arteriosus (PDA) and multiple peripheral pulmonary stenosis at the age of 03 months. She had history of recurrent Respiratory tract infection (RTI) since birth with failure to thrive. During one episode of RTI, a murmur was detected and she was referred to paediatric cardiologist of Combined Military Hospital (CMH) Dhaka for further assessment. Clinical examination showed typical facies with tachypnea and a continuous long systolic murmur all over the precordium with loud 2nd heart sound. Her SPO<sub>2</sub> was 88% (in room air). Bilateral cataract was also noticed. Her chest X-ray showed cardiomegaly with oligoemic lungs. Her electrocardiogram (ECG) showed right ventricular hypertrophy. TORCH antibodies screening showed immunoglobulin M (IgM) antibody positive for rubella virus. Echocardiography with color Doppler showed large tubular PDA of 4 mm size with right to left shunt and narrowing of pulmonary artery at multiple levels after bifurcation. She was diagnosed as a case of multiple peripheral pulmonary stenosis, large tubular PDA with reverse shunt. She was taken in to the Cath Lab on 1st June 2010 for balloon angioplasty and

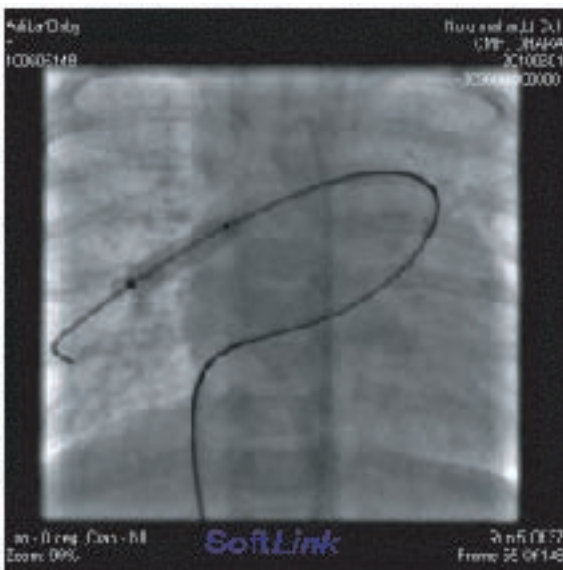
PDA device closure. Her diagnostic catheterization showed multiple stenotic lesions in peripheral branches of right and left pulmonary arteries along with valvular stenosis of pulmonary valve. A large PDA was noticed and pulmonary pressure was found 80/60 mm of Hg which was supra-systemic (right femoral arterial [RFA] pressure 75/40 mm of Hg). Peripheral pulmonary stenosis (PS) was thought to be responsible for high pulmonary pressure. So it was decided to do balloon dilatation of peripheral PS and pulmonary valve first. It took three hours to dilate all reachable pulmonary branches on both side. Six mm x 2 cm, 8 mm x 3cm Tyshak balloons were used several times on both lungs to dilate vessels. Later pulmonary artery pressure was measured again. But still it was supra-systemic. So decision to close PDA in same sitting was postponed.

Patient was discharged on the next day. She was followed up in out patient department (OPD) clinic for about 5 months and then PDA shunt was found left to right on 20th November 2010. She was getting medicine like Sildenafil, Captopril to reduce her pulmonary arterial (PA) pressure. She was taken into the Cath Lab again on 24th November 2010 for device closure of PDA. Because of pulmonary valve stenosis and peripheral branch stenosis her pulmonary artery course was abnormal, so device delivery system was introduced to aorta through right ventricle and pulmonary artery in modified way with the help of snare. An 8 mm x 6 mm Lifetech PDA occluder device was implanted. Device was not released until half an hour of implantation to see any adverse effect on the patient from high pulmonary pressure. All the vital parameters were found within normal limits and color doppler echo showed no residual shunt. So device was finally released from the delivery cable. Patient was kept in observation for 72 hours in the pediatric cardiology unit. Echo before discharge showed no residual shunt and marked reduction of pulmonary artery pressure [pulmonary artery systolic pressure (PASP) 35 mm Hg]. She was advised to come for follow up at 1, 3, 6, 9, 12, 18 and 24th month of intervention and clinical examination. ECG, chest X-ray and Echo will be done during each sitting. She was referred to ENT, eye specialist and Pediatric neurologist for other associated problem.

1. Col Nurun Nahar Fatema Begum MBBS, FCPS, Pediatric Cardiologist, CMH Dhaka



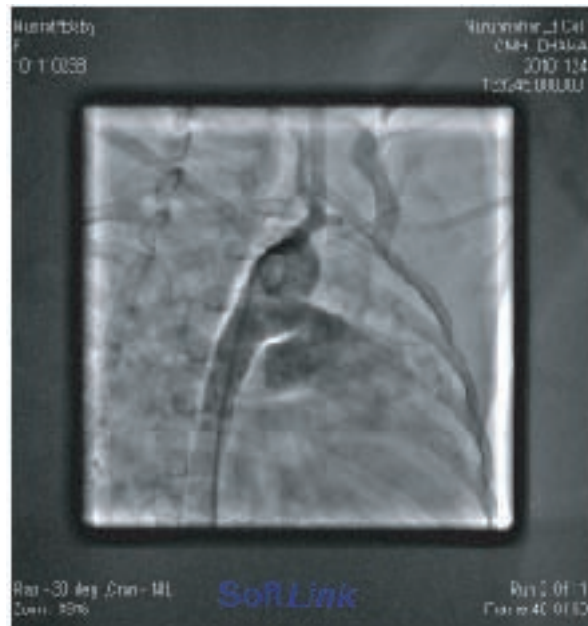**Fig-1:** Showed balloon dilatation of LPA origin of (case 1)



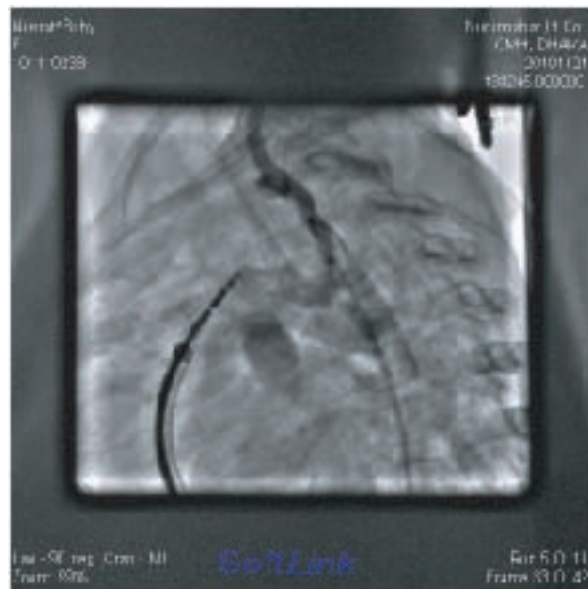
**Fig -2:** Balloon dilatation of distal RPA branch

**Case 2:** This girl was diagnosed as a case of congenital rubella syndrome at the age of 2 years and 4 months. She was referred to pediatric cardiologist of CMH Dhaka for cardiac work up. Along with failure to thrive, developmental delay, bilateral cataract and deafness, a huge size patent ductus arteriosus (6 mm) was noticed in colour doppler echocardiography with right to left shunt and with severe pulmonary hypertension. She had no pulmonary stenosis, so she was diagnosed as a case of huge PDA with Eisenmenger change. Her chest X-ray also showed bulged pulmonary conus. She was treated with antifailure (Lasix, digoxin, captopril) and Sildenafil with an aim to reduce pulmonary artery pressure. She was kept in observation for

01 month with all the medicine and then she was taken into the Cath lab on 24th November 2010 with an aim for trial of PDA device closure. Her pulmonary pressure was 76/60/68 mm Hg. Simultaneous aortic pressure was 78/52/66 mm Hg. We have decided to go for device closure with an idea that if there is any pulmonary hypertensive crisis than we will remove the device immediately. Initially we tried with a 12 x 10 mm device but that was small for the lesion with residual shunt. So it was taken out. Later on a 14x12 mm PDA occluder from cocoon (Thailand) was deployed and it also failed to occlude the shunt and shape of the device was not symmetrical with the PDA opening at aortic end.



**Fig-3:** Aortogram shows huge PDA in patient (case 2)



**Fig-4:** Aortogram shows residual shunt after implantation of 14x12 device of shine yard

As a last chance a lifetech device of 14 x 12 mm was implanted and that worked nicely. We observed the patient for half an hour for any untoward events, but patient was found quite, sedated. SPO<sub>2</sub>, heart rate and RFA pressure were all normal and Echo showed no residual shunt, no mechanical obstruction of aorta and marked reduction of pulmonary artery systolic pressure (PASP 50 mm Hg). So finally device was released from the delivery cable. Patient was observed for 72 hours and echo before discharge showed no residual shunt and Pulmonary artery systolic pressure of 40 mm Hg. Follow up appointment was given accordingly and multidisciplinary management of eye, ENT and other problems were advised.

### Discussion

Congenital Rubella Syndrome is a type of in utero infection that infants contract from their mother while she is pregnant and can lead to severe birth defects and disorders. It is caused by a virus called rubella virus<sup>1-4</sup>. Fortunately, rubella is uncommon now a days as children are vaccinated. But congenital rubella syndrome is still not uncommon as most of the mothers are not vaccinated. A newborn with congenital rubella is at risk for congenital heart problems specially PDA, eye problems like cataract or glaucoma, mental retardation, growth retardation, low birth weight, developmental delay, learning disabilities, deafness, hepatosplenomegaly, etc. Cardiac abnormalities occur in half of the children infected during the first week of gestation. PDA is the most frequently reported cardiac defect followed by lesions of pulmonary arteries and valvular disease<sup>5-8</sup>. In one study heart disease was found in 93.34% case of rubella syndrome. Incidence of heart disease is also high in other studies<sup>9-12</sup>. In both of our cases, failure to thrive, bilateral cataract was present. Deafness was present in one case (case II) with developmental delay. Both the cases were referred to ophthalmologist for treatment of cataract first but it was refused on the ground that their cardiac problems should be solved prior to cataract surgery. In case no 1, PDA was associated with multiple peripheral pulmonary artery stenosis. In case no 2, there was no pulmonary stenosis but there was evidence of Eisenmenger change.

PDA occlusion with ductus occluder and coils are in use since long time. The Lifetech PDA occluder, constructed of Nitinol mesh, is similar in principle to the Amplatzer PDA occluder<sup>13-15</sup>. Reported center is using this device since 2004. So far 494 cases are operated with this device, with a total of 928 with other devices and coils. This device is a conical shaped device with a wide aortic end to stent the ductus<sup>8</sup>. This device is effective for large size ductus<sup>9</sup>. PDA of case no 2 was very large, cylindrical and was not suitable for device closure and was referred to cardiac surgeon for ligation. But this case was refused by cardiac surgeon for the reason that she had right to left shunt. So maximum effort was given to

close her ductus with any of the occluder available in Bangladesh. The 12 x 10, 14 x 10 mm devices of few companies were tried and occlusion was not achieved. Size of the device could not be increase further as there was chance of mechanical obstruction to aortic end. But finally Life tech device gives good result (14 x 12) and there was no pulmonary hypertensive crisis in immediate post operative period. Case no 1 was also refused by the surgeon as peripheral PS at the various part of the lungs on both side were unreachable for surgeons. So, all peripheral PS were dilated in one sitting and PDA was closed in another sitting. So far 49 cases of cylindrical large PDA with severe pulmonary hypertension are closed with various devices and no complications were noticed in their follow up investigations.

### Conclusion

It is now standard practice in many centers to recommend non surgical closure as first choice therapy. The procedure is less invasive, needs only 24 hours hospital stay for uncomplicated cases. This reduces the total cost as it minimize parent's loss of working days and stay in hotels/away from home . In our center we prefer transcatheter closure over surgical ligation. In last five years we referred only two cases to cardiac surgeon for surgical ligation.

### References

1. Information Service. Delayed effects of congenital rubella syndrome. Sense - for Deafblind People. Factsheet -19. London: Sense; 2008.
2. Fatema NN, Razzaque AKM, Haque AFMS. Pattern of heart disease in congenital rubella syndrome patient: Analysis of cases over one year.. Bangladesh Journal of cardiology 2010; 6 (1): 1-5.
3. Edrich RF, Winters KL, Lang WB, Gubler KD, Rubella and congenital rubella. J Long Term Eff med implants 2005; 15(3): 319-328.
4. Bar-O, B, Levichek Z, Morethi ME, Mahc Andrew S, Karen G. Pregnancy out come following rubella vaccination: a prospective controlled study. Am J Med Genet 2004; 130 (1): 52-54.
5. Robertson Se, Featherstone DA, Geic-Dobo M, Hersh Bs. Rubella and congenital rubella syndrome: Global up date: Rev Panam Publica 2002; 14 (5): 306-315.
6. Siegel M, Fuerst HT, Guinee VF. Rubella epidemics and embryopathy. Results of a long-term prospective study. AM J Dis child 1971; 121 (6): 469-473.
7. Congenital Rubella Syndrome in late infancy. JAMA 1967; 200 (6): 105-111.
8. Cooper LZ, Krigman. Diagnosis and management of Congenital Rubella. Pediatrics 1966; 37: 335-338.
9. Rudolph AJ. Trans placental Rubella infections in newly born infants. JAMA 1968; 191: 843-845.
10. karones SB. Congenital Rubella syndrome: New clinical aspects and recovery of virus for affected infants. J Pediatr 1968; 67; 166-181.
11. Lirquist J. M. Congenital Rubella Syndrome as a systemic infection: Studies of affected infants born in Philadelphia. Brit Med J, 1965; 2: 1401-1406.
12. Mason WH. Rubella infection. In: Kliegman RM, Behrman RE, Jenson HB, Stanton BF, editors. Nelson Text book of pediatrics. Volume-1. 18th ed. Philadelphia: WB Saunders; 2008. p.1340.
13. Lambert HP, Stern H, Welstead AJ. Congenital Rubella Syndrome. Lancet 1965; 2: 826-827.
14. Health guide. The New York Times. Monday, May 31, 2010.
15. Focus on congenital rubella syndrome. Fact sheet. Spring 2006 Newsletter. Voll 15 No 3 page 4.