

SHORT COMMUNICATION

## Evaluation of wound healing potential of pomegranate (*Punica granatum*) whole fruit extract on skin burn wound in rats (*Rattus norvegicus*)

Bambang Sektiari Lukiswanto<sup>1</sup>, Alya Miranti<sup>2</sup>, Sri Agus Sudjarwo<sup>3</sup>, Hardany Primarizky<sup>1</sup>, Wiwik Misaco Yuniarti<sup>1</sup>

<sup>1</sup>Department of Clinical Science, Faculty of Veterinary Medicine, Universitas Airlangga, Surabaya, Indonesia

<sup>2</sup>Faculty of Veterinary Medicine, Universitas Airlangga, Surabaya, Indonesia

<sup>3</sup>Department of Pharmacology, Faculty of Veterinary Medicine, Universitas Airlangga, Surabaya, Indonesia

### ABSTRACT

**Objective:** This research was conducted to study the wound healing process of whole fruit pomegranate extract (*punica granatum*) standardized with 40% ellagic acid ointment for deep second-degree burn wound of skin in the rat (*Rattus norvegicus*).

**Materials and Methods:** Powder of standardized pomegranate extract (SPE) with 40% ellagic acid was processed to become ointments. Twenty-five male rats, weighed 150–180 gm at 3 months of age, were randomly divided into five groups. After anesthetized, stainless circle plate with 1 cm of diameter in 85°C was contacted firmly toward right gluteal of rat skins for 5 sec in order to create deep second-degree burn wound. Control groups consist of (T0) cream base and (T1) 1% silver sulfadiazine. Treatment groups consist of (T2) 2.5% SPE, (T3) 5% SPE, and (T4) 10% SPE. Histopathological preparation used hematoxylin-eosin stained skin samples. Histological observations were performed using the optics microscope against collagen, the number of polymorphonuclear cell (PMN) infiltration, the degree of angiogenesis, and re-epithelization. The results were statistically compared between groups.

**Results:** Microscopic observation on the wound healing process on the collagen, PMN infiltration, angiogenesis, and re-epithelization showed that topical administration of 10% SPE in burns gives the best result. This is characterized by a high density of collagen with a good arrangement, which is accompanied by a complete and mature epithelium, low number of inflammatory cells, and angiogenesis. This may be caused by the compounds in the pomegranate extract, which have the antioxidant, anti-inflammatory, and anti-bacterial effects.

**Conclusion:** This study reveals that 10% SPE accelerates the healing of deep second-degree burn wound. Thus, pomegranate standardized with 40% ellagic acid is a promising herb for the healing of burn wound of skin.

### ARTICLE HISTORY

Received January 13, 2019  
Revised February 03, 2019  
Accepted February 16, 2019  
Published April 14, 2019

### KEYWORDS

Burn wound; ellagic acid; pomegranate; silver sulfadiazine; wound healing



This is an Open Access article distributed under the terms of the Creative Commons Attribution 4.0 Licence (<http://creativecommons.org/licenses/by/4.0>)

### Introduction

Burn wound is one of the most considerable cases in the world [1]. Burn wound creates an extensive loss of cells and tissues, which makes the repair process more complicated than incision wound [2]. On the other hand, burn wound usually comes with complications. Burn wounds and the complications worsen the patient's condition, which results in even more challenges in treatment management [3].

Burn wound can be classified by its depth. Deep second degree of burn wound is characterized with blister [4] that reaches reticular dermal layer and it has a higher risk of chronic local inflammation of dermis, followed by the formation of keloid or hypertrophic scar which may remain for a longer period of time [5].

There are four stages of the wound healing process: hemostasis, inflammation, proliferation, and remodeling [6]. Hemostasis is the process which conducts blood

**Correspondence** Bambang Sektiari Lukiswanto ✉ [bamsekti@yahoo.com](mailto:bamsekti@yahoo.com) 📧 Department of Clinical Science, Faculty of Veterinary Medicine, Universitas Airlangga, Surabaya, Indonesia.

**How to cite:** Lukiswanto BS, Miranti A, Sudjarwo SA, Primarizky H, Yuniarti WM. Evaluation of wound healing potential of pomegranate (*Punica granatum*) whole fruit extract on skin burn wound in rats (*Rattus norvegicus*). J Adv Vet Anim Res 2019; 6(2):202–07.

coagulation. Inflammation occurs in order to protect the host from pathogen invasion and to promote proliferation [7]. Wound re-epithelization, angiogenesis, fibroblast, and extracellular matrix (ECM) formation are the results of proliferation [6,7]. The final stage of the wound healing process is remodeling, which creates the final result in the tissue's maturation process [7,8].

Until today, researchers are still searching for an alternative drug to optimize the healing result of the burn wound. The pomegranate, *Punica granatum*, is already well-known as a traditional medicinal fruit that was stated in the Old Testament of the Bible, the Qur'an, the Jewish Torah, and the Babylonian Talmud as a sacred fruit containing powers of fertility, abundance, and luck. Traditionally and currently, pomegranate is used for disorders of various systems [9]. The pomegranate's efficacies, which already known, are a strong antioxidant, anticarcinogenic, anti-inflammatory, and antibacterial [10].

Tannins, flavonoids, alkaloids, organic acid, saccharides, coumarins, lignans, triterpenes, steroids, punicic acid, anthocyanidins, anthocyanins, and estrogenic substances are found in pomegranate, in fruits and in every other part of it. Current research seems to indicate that the most therapeutically beneficial pomegranate's constituent is ellagic acid, which comes from ellagitannins (ETs) [10,11].

Pomegranate extract is currently standardized with ellagic acid. Approximately 40% (or more) ellagic acid in pomegranate extract is believed to increase and enhance the therapeutic effect of pomegranate extract. A synergic activity between substances inside the pomegranate appears better compared to a single substance [10,12].

To the best knowledge of the authors, there were a few studies done describing the effect of standardized materials for burn wound therapy. This research aimed to evaluate the effect of standardized pomegranate extract with 40% ellagic acid for deep second-degree burn wound in the rat.

## Materials and Methods

### Ethical approval

The entire procedure of this research was evaluated and approved by the Ethical Committee of Faculty of Veterinary Medicine, Universitas Airlangga (792-KE), December 17, 2017.

### Research sites

This research was conducted at the Laboratory of Experimental Animal at the Faculty of Veterinary Medicine Universitas Airlangga, Indonesia. Ointments preparation was conducted in the Faculty of Pharmacy, Universitas Airlangga, Indonesia. The histological examination was

conducted at Pathology Laboratory, Faculty of Veterinary Medicine, Universitas Airlangga, Indonesia.

### Experimental animal

Twenty-five male albino rats (*Rattus norvegicus*) at 3 months of age and weighed 150–180 gm were used in this research. The rats were given commercial food and water *ad libitum*.

### Research materials

Materials used in this research were powder of standardized pomegranate extract with 40% ellagic acid and polyethylene glycol (PEG). Preparation of topical formulation was done by melted PEG 4000 in a water bath and liquid PEG 400 was added. The mixture was cooled while being stirred until it congealed. The standardized pomegranate extract powder (2.5%, 5%, and 10% w/w) was levigated with the blank base and was serial diluted using mortar and pestle. In histopathological preparation, 70%, 80%, 90%, and 96% alcohol, formalin 10%, hematoxylin eosin, xylol, entellan, and paraffin were used.

### Research tools

Tools in this research include cage and wire, food bowl, drinking bottle, and husk bedding. Cage is made of plastic, which separated into two rooms with a separating metal plate placed diagonally. Cotton buds are necessary for giving topical treatments. Animal preparation requires hair clipper, modified thermostat tool, isolator glove, sterile glove, and syringe for sedation. After treatment, skin collecting requires a scalpel, pin set, surgical forceps, and small pots for collecting organ in 10% formalin. Histopathology preparation uses a series of dehydration apparatus, microtome, water bath, hot plate, object glass, and cover glass. The slides are observed with Nikon®Eclipse H600L microscope and DS Fi2 300 megapixel digital camera.

### Experimental animal preparation

Rats were adapted in the laboratory for a week before the procedures. Then, the rats were randomly separated into five groups, with each containing five rats, named T0, T1, T2, T3, and T4. Anesthesia was used with a combination of Ketamin/Xylazine with a dose of Ketamine 100 mg/kg and Xylazine 5 mg/kg [13], followed with hair clipping.

In order to create deep second-degree burn wound on the skin above the right gluteal of rat, modified thermostat with round stainless steel plate and 1 cm of diameter [14,15], contacted firmly to skin [16], for 5 sec in 85°C [15], with average toleration 85°C ± 5°C.

Treatments were administered topically, two times a day for 14 days of therapy. Drug administration started right after the burn procedure.

- Group T0: Albino rat with burn wound treated with a cream base.
- Group T1: Albino rat with burn wound treated with 1% silver sulfadiazine ointment.
- Group T2: Albino rat with burn wound treated with 2.5% standardized pomegranate extract ointment.
- Group T3: Albino rat with burn wound treated with 5% standardized pomegranate extract ointment.
- Group T4: Albino rat with burn wound treated with 10% standardized pomegranate extract ointment.

Rats were euthanized and undergone skin collecting on day 15. Excision of skins was done about  $2 \times 2 \text{ cm}^2$  around the wound, with the depth of full thickness. Skin samples were fixated in 10% buffer formalin for histopathological slides. The specimens were colored with hematoxylin eosin. The observation criteria of histological feature are collagen : none : score = 0, low amount : score = 1, moderate : score = 2, and high amount : score = 3; the number of polymorphonuclear polymorphonuclear (PMN): none : score = 0, low amount : score = 1, moderate : score = 2, and high amount : score = 3; degree of angiogenesis: none : score = 0, less than 5 veins : score = 1, 6–10 veins : score = 2, and more than 10 veins : score = 3; and re-epithelization, none : score = 0, partial : score = 1, complete but with immature epithelium : score = 2, and complete with mature epithelium : score = 3 [17,18].

## Results

Figure 1 showed the histopathological feature of skin burn in day 15. Group T0 showed that there were no collagen bundles, no re-epithelization, high number of PMN, and angiogenesis (A). Almost the same histopathological picture can be seen in T1 (B). However, in T1, there was a better histopathological picture around the burn area, which was marked by a reduced area of inflammation. Low collagen bundles, partial re-epithelization, moderate PMN, and less angiogenesis can be seen on T2 (C). Low collagen bundles, complete immature re-epithelization, low PMN and angiogenesis can be seen on T3 (D). The best feature with moderate collagen bundles, complete mature re-epithelization, low PMN and angiogenesis can be seen on T4 (E).

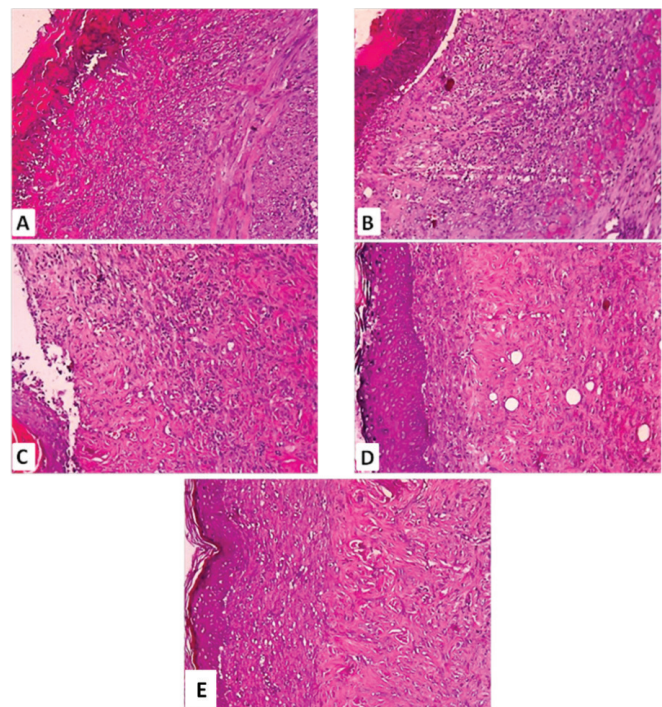
Scoring of collagen formation in the skin was focused on the percentage of collagen bundles in microscopic fields. The result of collagen assessment showed that there is no significant difference between T0 and T1 and also among T2, T3, and T4 ( $p > 0.05$ ). However, the significant difference can be seen in T0 and T1 compared to T2, T3, and T4 ( $p < 0.05$ ).

Re-epithelization score on T0 and T1 have no significant difference ( $p > 0.05$ ) but have a significant difference with T2, T3, and T4 ( $p < 0.05$ ). The highest re-epithelization

score is seen on T4 and has a significant difference with another treatment ( $p < 0.05$ ). Observations of angiogenesis and inflammation in this study showed similar patterns. At T0 and T1, there is no significant difference ( $p > 0.05$ ), but both are significantly different from T2, T3, and T4 ( $p < 0.05$ ) (Tables 1 and 2).

Overall, the re-epithelization from the treatment groups (T2, T3, and T4) was better than the control group (T0 and T1) ( $p < 0.05$ ). The number and the quality of collagen were increased. The inflammatory and angiogenesis processes were better in the treatment groups. The best re-epithelization process was seen on the T4, while moderate re-epithelization also occurred in groups T2 and T3 ( $p < 0.05$ ). The amount and the arrangement of collagen on the group treatments (T2, T3, and T4) were better than the control group.

Angiogenesis is better in Groups T3 and T4 compared to the groups T1 and T2. Based on the score of PMN number,



**Figure 1.** Histopathological appearance of skin on day 15 post-burn treated with (A) cream base, (B) 1% silver sulfadiazine, (C) 2.5% standardized pomegranate extract (SPE), (D) 5% SPE, and (E) 10% SPE. (A) No collagen and re-epithelization, high number of PMN and angiogenesis, (B) no collagen and re-epithelization, high number of PMN and angiogenesis, (C) low collagen bundle, partial-immature re-epithelization, moderate PMN, and low angiogenesis, (D) low collagen bundle, complete-immature re-epithelization, and low PMN and angiogenesis, and (E) moderate, complete-mature re-epithelization, low PMN and angiogenesis.



**Table 1.** Status of histopathological changes in the skin of each treatment group.

Treatment group	Histological Status			
	Re-epithelization	Collagen	Inflammation	Angiogenesis
T0	None	None	High	>10
T1	None	None	High	>10
T2	Partial	Low	Moderate	<5
T3	Complete immature	Low	Low	<5
T4	Complete mature	Moderate	Low	<5

**Table 2.** Scoring of histopathological changes in the skin (mean ± SD) of each treatment group.

Treatment group	Mean ± SD			
	Re-epithelization	Collagen	Inflammation (Number of PMN)	Angiogenesis
T0	0.00 <sup>a</sup> ± 0.000	0.40 <sup>a</sup> ± 0.548	3.00 <sup>a</sup> ± 0.000	3.00 <sup>a</sup> ± 0.000
T1	0.00 <sup>a</sup> ± 0.000	0.40 <sup>a</sup> ± 0.548	3.00 <sup>a</sup> ± 0.000	3.00 <sup>a</sup> ± 0.000
T2	1.40 <sup>b</sup> ± 1.095	1.40 <sup>b</sup> ± 0.548	2.20 <sup>ab</sup> ± 0.837	1.60 <sup>b</sup> ± 0.548
T3	2.40 <sup>b</sup> ± 0.548	1.80 <sup>b</sup> ± 0.447	1.40 <sup>b</sup> ± 0.548	1.20 <sup>b</sup> ± 0.447
T4	3.00 <sup>c</sup> ± 0.000	2.20 <sup>b</sup> ± 0.447	1.00 <sup>b</sup> ± 0.000	1.00 <sup>b</sup> ± 0.000

Values are expressed as mean of five individuals in each group ± SD. Means with different superscripts letters (a, b and c) are significant at  $p < 0.05$ .

the best inflammatory process was seen on the T4 group, while the Groups T2 and T3 are still likely to be longer as the control group.

The best results of the wound healing process are seen in T4, which characterization shows a high density of collagen with a good arrangement accompanied by a complete and mature epithelium, low number of inflammatory cells, and angiogenesis.

## Discussion

Burn wounds are the type of wounds that prone to complications [3]. The presence of complication can worsen the healing process in many ways. In this research, the most probable complication that may occur is an infection. Therefore, topical drugs for burn wounds presumably need the role of antibacterial property, which is effective against both Gram-negative and Gram-positive bacteria, as well as *Candida* sp., inexpensive, and have no harmful side effects [4].

Silver sulfadiazine as control positive (T1) in this research cannot create the optimum result of collagen formation, instead, it creates the worst result. In this experiment, the negative effects of silver sulfadiazine that are observed clearly are retardation of wound contracture and delayed and incomplete epithelialization [19]. Silver sulfadiazine cream, while being effective, causes some systemic complication, which includes neutropenia,

erythema sultiforme, crystalluria, and methemoglobinemia [20].

Prolonged and excessive inflammation process creates the risk of delayed wound healing. Inflammation process has the function to clear damaged cells, vasodilatation, and extravasation of inflammatory cells. Neutrophils and macrophages create chemical mediators, such as IL-1 $\beta$ , tumor necrosis factor (TNF)  $\alpha$ , PDGF, FGF, and EGF. High amount of macrophage and neutrophil in a longer period of time may turn inflammation into chronic one that automatically worsens the wound environment. The examples of the negative impact that can occur are the high amount of metalloproteinase which can degrade the new ECM and the excessive excretion of TNF which can worsen the inflammation. Besides, inflammation can promote the formation and degradation of aerobic cells. This event can create the spontaneous formation of reactive oxygen species (ROS), which result in oxidative stress [7]. High amount of ROS can create necrotic cell death. Oxidative stress can be suppressed by the presence of antioxidant [21].

According to these facts, burn wound, which undergoes high inflammation process and cannot be denied, should be treated with anti-inflammatory and antioxidant substances in order to prevent the probability of delayed wound healing.

Generally, pomegranate has various active substances which individually can act as antibacterial, anti-inflammatory, and strong antioxidant. Some of the potential

substances inside the pomegranate are tannin, flavonoid, puniceic acid, and phytoestrogen. In addition, tannins can specifically act as astringent and natural wound protector to let the skin heal naturally [22].

Ellagic acid is a simplified form of ETs, which genuinely include in tannins. Ellagic acid is an active substance which acts dominantly inside the pomegranate. Ellagic acid individually also has the antibacterial, antiinflammation, and strong antioxidant effect [10].

The addition of ellagic acid in pomegranate standardization can strengthen the function of pomegranate as a topical drug. As explained in Patwardhan et al. [23], Chinese and Indian medicine uses natural herbal materials because of their advantages compared to synthetic drugs. The presence of various active substances inside herbal drugs can presumably expand the therapeutic spectrum and increased the treatment result. This role is principally linked to the mechanism of the body, which engaged organs and cells in the responsibility to repair any disturbance in the body. The disturbance creates a body imbalance. Once the body tries to return the balance, organs and cells are working together to do it. In this principle, it is believed that various active substances inside the herbal materials can complete the need of organs and cells to optimizing the healing process, which single substance cannot.

In previous research, pomegranate can mimic the role of ampicillin [10]. Although the antibacterial mechanism of pomegranate is not fully understood, the active substance inside pomegranate can create toxicity inside the body of bacteria through the change and interaction with enzymes and substrates [24].

In the inflammation process, chemical mediators create the expression of cyclooxygenase-2 (COX-2), which promotes prostaglandins (PGs) synthesis. In this research, the anti-inflammatory function in pomegranate active substances can suppress the COX-2 expression [25].

As the antioxidant properties, active substances in pomegranate can prevent the oxidative stress by maintaining the level of malondialdehyde, glutathione, glutathione peroxidase, and catalase [26].

In this research, the result of good collagen formation can be linked with an optimal healing process of the burn wound. The increased dosage of standardized pomegranate extract with 40% ellagic acid ointments shows significant results of collagen formation. This result proved that standardized pomegranate extract with 40% ellagic acid ointments can create an optimal process of burn wound healing. From these findings, it is known that the addition of 40% ellagic acid in the standardization of pomegranate extract presumably creates a synergic mechanism to support an optimal process of burn wound healing.

## Conclusion

Our result showed that 10% PSE ointment is effective for the treatment of second-degree burns in rats and may be suitable for clinical therapy of second-degree burns.

## Acknowledgments

The authors would like to thank the Faculty of Veterinary Medicine, Universitas Airlangga, Surabaya, for providing facilities and resources for the accomplishment of this research.

## Conflict of Interests

The authors declare that they have no competing interest.

## Author's contribution

Alya Miranti prepared the study design and carried out the research under the supervision of Bambang Sektiari Lukiswanto and Sri Agus Sudjarwo. Wiwik Misaco Yuniarti and Hardany Primarizky performed the statistical analysis and analyzed the main data in the experiments. All authors read and approved the final manuscript.

## References

- [1] Ashkani-Esfahani S, Imanieh MH, Khoshneviszadeh M, Meshksar A, Noorafshan A, Geramizadeh B, et al. The Healing effect of arnebina euchroma in second degree burn wounds in rat as an animal model. *Iran Red Crescent Med J* 2012; 14(2):70–4.
- [2] Aliabadi A, Valadaan V. Comparison between the effect of silymarin and silver sulfadiazine on burned wound healing in rats. *Bulgarian J Vet Med* 2016; 19(3):224–32; <https://doi.org/10.15547/bjvm.890>
- [3] Masood RA, Wain ZN, Tariq R, Asis ullah M, Bashir I. Burn cases, their management and complications: a review. *Int Curr Pharm J* 2016; 5(12):103–5.
- [4] LaDou J, Cohen R. Disorders due to physical agents. In: McPhee SJ, et al. (Eds.). *Current medical diagnosis and treatment*. International Edition, Prentice-Hall International Inc., New York, pp. 1079–84, 2003.
- [5] Ogawa R. Keloid and hypertrophic scars are the result of chronic inflammation in the reticular dermis. *Int J Mol Sci* 2017; 18(606):1–10; <https://doi.org/10.3390/ijms18030606>
- [6] Nema N, Arjariya S, Bairagi SM, Jha M, Kharya MD. *In vivo* topical wound healing activity of punica granatum peel extract on rats. *Am J Phytomed Clin Therap* 2013; 1(2):195–200.
- [7] Röhl J, Zaharia A, Rudolph M, Murray RZ. The role of inflammation in cutaneous Repair. *Wound Prac Res* 2015; 23(1):8–15.
- [8] Olczyk P, Mencner L, Komosinska-Vassev K. The role of the extracellular matrix components in cutaneous wound healing. *BioMed Res Int* 2015; 14:1–8; <https://doi.org/10.1155/2015/549417>
- [9] Miguel MG, Neves MA, Antunes MD. Pomegranate (*Punica granatum* L.): a medicinal plant with myriad biological properties—a short review. *J Med Plant Res* 2010; 4(25):2836–47.
- [10] Jurenka J. Therapeutic applications of pomegranate (*Punica granatum* L.). *Altern Med Rev* 2008; 13(2):128–44.
- [11] Wang R, Ding Y, Liu R, Xiang L, Du L. Pomegranate: constituents, bioactivities and pharmacokinetics. fruit, vegetable and cereal. *Sci Biotechnol* 2010; 4(Special Issue 2):77–87.

- [12] Kunle OF, Egharevba HO, Ahmadu PO. Standardization of herbal medicines—a review. *Int J Biodiv Conservat* 2012; 4(3):101–12; <https://doi.org/10.5897/IJBC11.163>
- [13] Flecknell P. *Laboratory animal anesthesia*. 3rd edition, Academic Press, USA. p. 187, 2009.
- [14] Cai EZ, Ang CH, Raju A, Tan KB, Hing ECH, Loo Y, et al. Creation of consistent burn wounds: a rat model. *Arch Plastic Surg* 2014; 41:317–24; <https://doi.org/10.5999/aps.2014.41.4.317>
- [15] Abdeldjelil MC, Messai A, Boudebza A, Beghou S. Practical aspects to generate cutaneous experimental burns in a rat model scholars. *Der Pharmacia Lett* 2017; 9(1):70–84.
- [16] Porumb V, Trandabst AF, Terinte C, Csruntu ID, Porumb-Andrese E, Dimofte MG, et al. Design and testing of an experimental steam-induced burn model in rats. *BioMed Res Int* 2017; 12(3):1–10; <https://doi.org/10.1155/2017/9878109>
- [17] Shakya P, Sharma AK, Kumar N, Vellachi R, Mathew DD, Dubey P, et al. Bubaline cholecyst derived extracellular matrix for reconstruction of full thickness skin wounds in rats. *Scientifica* 2016; 2(1):1–13; <https://doi.org/10.1155/2016/2638371>
- [18] Nasiri E, Hosseinimehr SJ, Azadbakht M, Akbari J, Enayati-Fard R, Azizi S, et al. The healing effect of arnebia euchroma ointment versus silver sulfadiazine on burn wounds in Rat. *World J Plastic Surg* 2015; 4(2):134–44.
- [19] Saeidinia A, Keihanian F, Lashkari AP, Lahiji HG, Mobayyen M, Heidarzade A, et al. Partial-thickness burn wounds healing by topical treatment, a randomized controlled comparison between silver sulfadiazine and centiderm. *Medicine*, 96(9):1–9; <https://doi.org/10.1097/MD.00000000000006168>
- [20] Han MC, Durmus AS, Karabulut E, Yaman I. Effect of Turkish propolis and silver sulfadiazine on burn wound healing in rats. *Revue Med Vet* 2005; 156(12):624–7.
- [21] Johar D, Roth JC, Bay GH, Walker JN, Krocak TJ, Los M. Inflammatory response, reactive oxygen species, programmed (necrotic-like and apoptotic) cell death and cancer. *Roczniki Akademii Medycznej w Białymstoku* 2004; 49:31–9.
- [22] Jesus NZT, Falcao HS, Gomes I, Leite TJA, Lima GRM, Barbosa-Filho JM, et al. Tannins, peptic ulcers and related mechanisms. *Int J Mol Sci* 2012; 13:3203–28; <https://doi.org/10.3390/ijms13033203>
- [23] Patwardhan CB, Warude D, Pushpangadan P, Bhatt N. Ayurveda and traditional chinese medicine: a comparative overview. *Evid Based Complement Altern Med* 2005; 2(4):465–73; <https://doi.org/10.1093/ecam/neh140>
- [24] Ghudaib KK, Hanna ER, Jawad AH. Effect of ellagic acid on some types of pathogenic bacteria. *J Al-Nahrain Univ* 2010; 13(2):79–85; <https://doi.org/10.22401/JNUS.13.2.09>
- [25] Zarghi A, Arfaei S. Selective COX-2 inhibitors: a review of their structure-activity relationships. *Iran J Pharm Res* 2011; 10(4):655–83.
- [26] Mehan S, Kaur R, Parveen S, Khanna D, Kalra S. Polyphenol ellagic acid-targeting to brain: a hidden treasure. *Int J Neurol Res* 2015; 1(3):141–52; <https://doi.org/10.17554/j.issn.2313-5611.2015.01.20>