

RESEARCH ARTICLE

Experimental fracture healing with external skeletal fixation in a pigeon ulna model

Ahmed Tunio^{1,#}, Abu Jalila^{2,*}, Goh Yong Meng² and Intan Shameha¹

¹Faculty of Veterinary Medicine, Sindh Agriculture University Tandojam, Pakistan;

²Faculty of Veterinary Medicine, University Putra Malaysia, Malaysia.

Corresponding author's e-mail: jalila@upm.edu.my*, ahmedtuniodvm2009@gmail.com #

ABSTRACT

This study was conducted to assess the healing of transverse ulna fracture when fixed with external skeletal fixation (ESF) in pigeon. Ulna fracture was created under Isoflurane anesthesia in pigeons. A total of 12 pigeons were used in this study, and they were divided into three equal groups: Group-1, Group-2 and Group-3. The birds of the three groups were sacrificed at 3, 6, and 12 weeks after successful fracture surgery. It was found that bone union occurred between three and six weeks in all groups. Bone alignment, and callus remodeling were evident at 12 weeks ($p < 0.05$) post fracture fixation. There were no radiographic evidence of callus remodeling in any bird at 3 and 6 weeks post-surgery. The radiographic observations of fracture healing in this study have confirmed that ESF fixation is an effective method to stabilize ulna fracture in pigeons and results in faster fracture healing.

Keywords:

Fracture, External skeletal fixation, Clinical union, Radiology, Pigeon, Ulna model

Received : 06 April 2014,

Revised: 19 April 2014,

Accepted : 20 April 2014,

Published online: 10 May 2014.

INTRODUCTION

Fracture is a challenging problem in domestic as well as in wild birds (Cole, 2007). Wild birds, when caged, are prone to stress and get self-injury (Goody et al., 2012). Wing and leg fractures in birds are most

common problems (Kubiak and Forbes, 2011). Mostly, captive as well as wild birds are predisposed to fractures due to traumatic injury to the bones of birds (Donely, 2011). Fracture treatments of injured birds are important for their survival. External Skeletal Fixation (ESF) is a technique of choice for fracture fixation in birds (Redig and Cruz, 2008; Cole, 2007). Fixation should hold the bone in place, allowing for bone union of the fractured ends. Rigid stabilization provides bone strength and protects from stress. However, the procedures for fracture treatment in birds have been taken from the method used for fracture treatment in small animals and humans (Redig et al., 2008). ESF pins, such as the ESF Type-1 (Redig and Cruz, 2008), and the ESF-IM tie-in fixators (Redig, 2001; Jalila et al., 2004; Cole, 2007) are effective for fracture fixation in birds.

Presently, the ESF pins are being used for the management of long bone fractures in birds with varying degrees of success (Hatt, 2009) because ESF pins are light in weight and are ideal for fracture stabilization in birds (Goody et al., 2012). ESF threaded pins have good bone holding strength for fracture fixation in birds (Degernes et al., 1998). In the meantime, if fracture is not treated with rigid fixation, the fractures will not heal properly and there will be delay in bone healing (Kubiak and Forbes, 2011). Therefore, ESF plays a key role for the successful fracture treatment in birds. Most experimental bone healing studies have been conducted on mammals (Hatt, 2009). Fracture healing in birds has not been focused in detail and limited experiments have been conducted on fracture healing with rigid fixation such

as ESF (Bennett and Kuzma, 1992). Furthermore, there are no general agreements concerning fracture fixation techniques in birds. Very little research has been done to determine the fracture healing using ESF through radiographic evaluation methods on birds.

The radiological evaluation of fracture healing with ESF will further help to assess the fracture healing on experimental research. Radiology can be useful technique for monitoring the fracture healing process. The radiographs are taken postoperatively on the day of surgery and then on the 2nd, 4th, 6th, and 8th week to assess the radiographic union, bone alignment and callus remodelling (Biggam et al., 2008). Fracture management is a major clinical problem in birds. Thus, successful fracture treatment needs proper diagnosis and effective management in birds (Cole, 2007; Redig and Cruz, 2008). Main purpose of fracture management is to restore the bone to its normal function as soon as possible. It was hypothesized that external skeletal fixation pins would probably fix the fracture and provide clinical union in pigeon ulna. The objective of this study was to investigate the speed of fracture healing, and quality of bone union with ESF using radiographic assessment in a pigeon ulna model.

MATERIALS AND METHODS

Animal Care and Use Committee (ACUC) Approval: ACUC of Faculty of Veterinary Medicine, University Putra Malaysia (UPM) has approved this study (UPM/FPV/10 R118/Feb 2011-Jan 2012).

Bird Preparation: A total of 12 healthy birds were used in this experiment. The pigeons were six-month-old and weighing 292.91 ± 9.40 grams (means \pm SD). They were randomly divided into three groups with four birds in each. Each group birds were studied for 3, 6 and 12 weeks post-surgery. All pigeons were off fed for six hours prior to surgery. The experiments were performed with inhalation anaesthesia using 4% to 5% Isoflurane (Piramal Healthcare Ltd, India) for induction and mixed with O₂ (1-1.5L/min). The pigeons were then intubated with a small, semi rigid un-cuffed plastic endotracheal tube (2.5 mm to 4 mm length). Isoflurane anaesthesia was maintained at 1.5-2.5% with O₂ (1-1.5L/min) by using a modified Jackson Rees (MJR) non-rebreathing anaesthesia circuit system. The left wing was prepared using 40% chlorhexidene solution and was painted with 10% Povidone solution. The birds were kept in a state of sternal recumbency on the surgical table over a heating pad to maintain body temperature. For osteotomy, the left wing was

extended and the dorsal approach was used to expose the ulna bone.

Surgical Procedure: A two cm longitudinal incision was made on the skin from cranial to dorsal between the radius and ulna for easy approach. The extensor metacarpi ulnaris, extensor metacarpi radialis and extensor digitorum communis muscles and fascia were retracted (Donely, 2011). The ulna bone was exposed gently and a transverse fracture was created at the mid-shaft of the left ulna. The fracture was created using ESF pins with a mini pin driver inserted in the dorsal and lateral cortex and four holes were gently created around the cortex. Finally, the bones were separated using a bone cutter (Jalila, 2002). Fracture was reduced and stabilized by inserting an external skeleton fixation (ESF) Type-1, size 0.045" (Imex, Veterinary Inc., TX, USA) in the cortex of the left ulna bone of the pigeon. Four positive profile threaded ESF pins were fixed perpendicularly one by one to the long axis of the bone's cortex. A mini Jacobs chuck was used to insert and fix the pins, two proximally and two distally, to the fracture site (Redig, 2001). When ESF pins were fixed in the ulna then fascia and muscles were sutured with Safil-violet 5/0 (Barcelona, Spain). The skin was closed with Safil-violet 5/0 by an interrupted pattern. After that, a latex Penrose tube (3/8" wide and 7 cm long) was inserted over the top of the ESF pins parallel to and above the ulna bone. The latex Penrose tubing was filled with a 10 mL mixture of acrylic material using a plastic syringe (Redig, 2001). When the acrylic material got dried completely, the ESF pins over the column were cut using a pin cutter. Butorphanol tartrate 0.2mg/kg (Torbugesic 2mg/mL, Fort Dodge Animal Health, USA) was injected subcutaneously only once for post-operative analgesia. Terramycin antibiotic ointment (Pfizer, Inc. USA) was applied on the incision and at ESF pin site. The wing wound was covered with a melolin absorbent pad then woven gauze applied to prevent any infection and finally wing was covered with a figure-of-eight bandage.

Radiographic Evaluation of Fracture Healing: Radiographs were exposed at the X-ray Imaging Laboratory of Faculty of Veterinary Medicine, UPM. The ventrodorsal (VD) views were obtained immediately at post-fracture fixation. Then serial radiographs were exposed every three weeks till their end-point of three, six, and 12 weeks post-surgery. The radiographs were taken using an X-ray machine with 125 kV and 200 mAs (Mobileart, Shimadzu Corporation, Kyoto, Japan) and standard avian settings were used at 44 kilo voltage peaks (kVp)

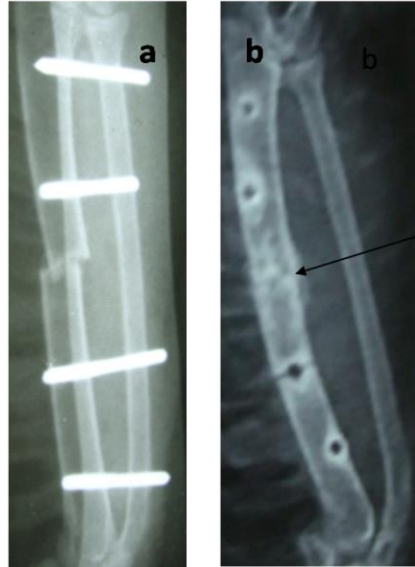

Figure 1. Radiograph shows fracture healing after three weeks; (a) Image exposed immediate after fracture fixation Day-0. (b) Image shows callus formation and arrow for bone union at Day-21.

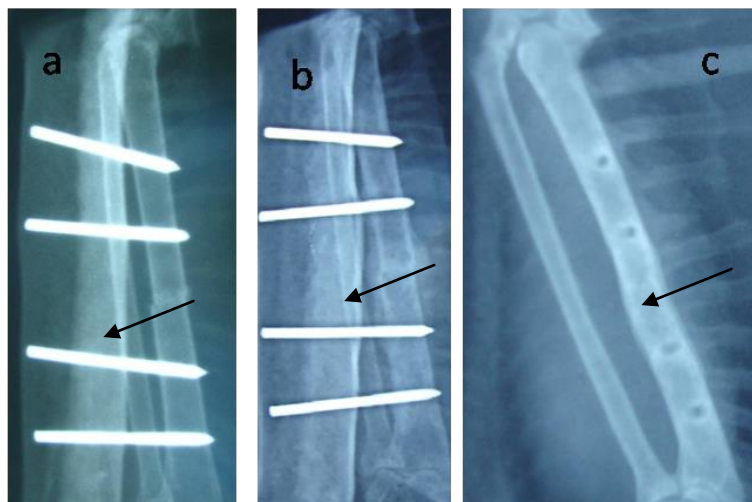


Figure 2. Radiographs shows fracture healing with bone union after six weeks; (a) Radiographic view of (Day-0) post fracture fixation with ESF. Figure (b) Arrow shows callus formation and bone union after week-3 post-fracture fixation. (c) Minimal callus with good cortical union at week-6 post-fracture fixation.

and 2 milliamperere seconds (mAs) with an exposure time of 0.04 milliseconds. The fracture healing process was assessed based on the criteria described in Table 1.

Statistical Analysis: All scores were tested for their conformance to the assumption of normality prior and results were compared across time points using the one way analysis of variance. The scores were compared across at time using non-parametric analysis of variance procedure. All procedures were performed at 95% confidence level based. The statistical analysis was conducted using commercial software in SPSS 20.00 version for windows (SPSS Inc., Chicago, IL, USA).

RESULTS AND DISCUSSION

In this study, we evaluated the transverse ulna fracture healing at three different end-points and stabilized with ESF Type-1 in a pigeon ulna. ESF pins were connected with light acrylic column. Similarly, Rush et al. (2012) who implanted ESF pins for repair of tarsometatarsus fracture and pins were connected with acrylic bar in white-Naped crane. They evaluated fracture healing by radiographic. In current study, after three, six and 12 weeks of fracture healing the birds were sacrificed and radiographs were exposed and evaluated for fracture healing. In a study by Gull et al. (2012) who evaluated the miniplate for fracture

treatment in pigeon ulna. They euthanized the birds at 14 and 28 days of surgery. They found that plate was twisted after healing of ulna and some periosteal callus formation was observed by radiographic examinations.

In our study, the results of group-1, radiographic assessment at three week of fracture healing showed secondary bone union in all the birds (n=4/4) where 100% fracture healing had occurred with callus bridging. The findings of this study are in agreement

with the study by Rush et al. (2012) they also reported that tarsometatarsus fracture of white-Naped crane healed with extensive periosteal callus formation, when fracture was fixed with ESF. Further, fracture line was absent in 50% (2/4) of the birds at three weeks. 50 % (2/4) of the birds had a fracture line that was still visible. Minimal callus occurred in 75% of the birds (3/4), while 25 % (1/4) showed extensive external callus. There was no callus remodelling in any of the birds at three weeks (Figure 1 a&b).

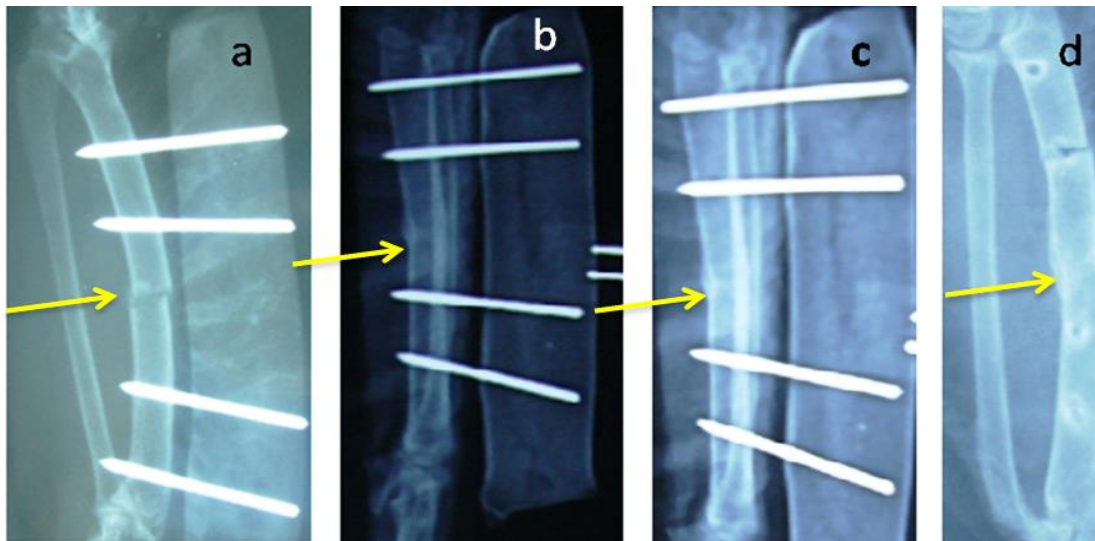


Figure 3. Radiographs shows fracture healing with primary union after 12 weeks; (a) Shows ESF fixation at day 0. (b) Shows bone union at 6 weeks post-surgery. (c) Shows complete fracture healing at 9 weeks post-surgery. (d) Shows callus remodelling at 12 week post-surgery.

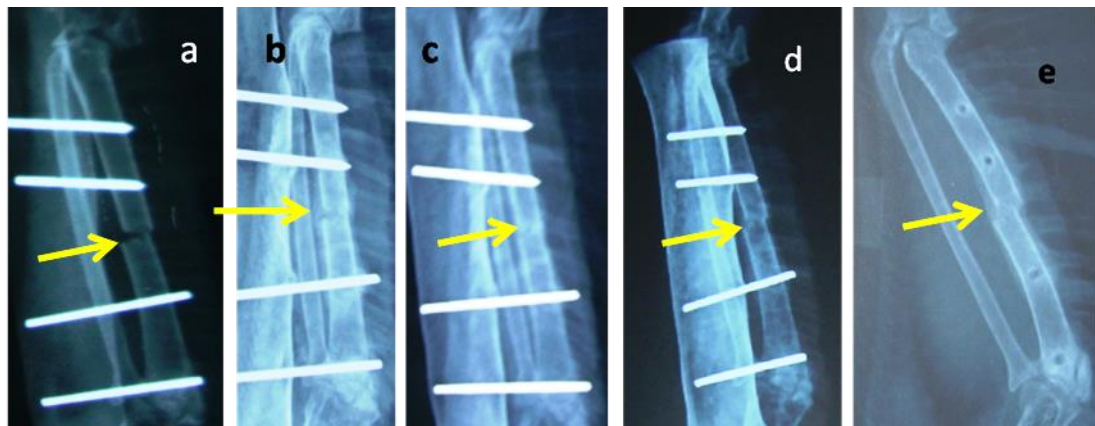


Figure 4. Radiographs shows clinical union and fair alignment after 12 weeks; (a) Image shows fracture fixation (Day-0). (b) Image shows fracture line visible at week-3 post-surgery. (c) Image shows fracture line absent at 6 weeks. (d) Image shows bone union at 9 weeks (e) Image shows fair alignment at 12 weeks.

Table 1: Radiological scoring system for fracture healing in pigeon ulna model

Criteria	Observation	Score
Bone Union	No Union	0
	Secondary Union(With Callus)	1
	Primary Union(No Callus)	2
Fracture Line	Visible	0
	Partial Visible	1
	Absent (Clinical Union)	2
Axial Alignment	Poor	0
	Fair	1
	Good	2
Callus Formation	No Callus	0
	Minimal Callus	1
	Extensive Callus	2
Callus Remodeling	No remodeling	0
	Early sign	1
	Partial	2
	Complete	3

Source: (Jalila, 2002; Koivukangas, 2002).

Table 2: Radiographic assessment of NCSF fracture healing in pigeon ulna model

Score Mean \pm SE (n=4 birds/week in rows)

Parameters	Three Weeks	Six Weeks	Twelve Weeks
Bone Union ^{NS}	1.0 \pm 0.00	1.25 \pm 0.25	1.50 \pm 0.19
Fracture Line ^{NS}	2.0 \pm 0.00	2.0 \pm 0.00	2.0 \pm 0.00
Axial alignment ^{NS}	1.5 \pm 0.29	1.5 \pm 0.29	1.75 \pm 0.16
Callus Formation ^{a,b}	1.25 \pm 0.25 ^b	1.0 \pm 0.00 ^{a, b}	0.375 \pm 0.18 ^a
Callus Remodelling ^{a,b}	0.0 \pm 0.00 ^a	0.0 \pm 0.00 ^a	2.50 \pm 0.27 ^b

^{NS}=Not significantly different at $p < 0.05$. ^{a,b}=Means with different superscripts differed significantly within rows ($p < 0.05$).

Present findings in group-2, at six weeks, radiographic evidence showed that bony callus united the fractured ends, while primary bone union had occurred in 25% (n=1/4) of the birds and secondary union occurred in 75% (n=3/4) of the birds. The fracture line was absent in 100% (n=4/4) of the birds, thus showing clinical union in all the birds. Good axial alignment was seen in 50% (2/4) of the birds, while the other 50% (2/4) showed poor alignment. Complete clinical union was achieved at 6 weeks in all the birds Figure 2 (a, b and c). Moreover, our results were further in agreement with the findings by Alievi et al. (2008), where they used Kirshner-pins for humerus fracture fixation in pigeon. They found faster fracture healing at 33 \pm 3.74 days without any complications. Additionally, our study is further supported by Hat (2009), who reported that ESF type-1 is the best choice for wing fracture treatment in birds and concluded it as a successful technique in avian surgery.

However, results of this study in group-3, radiographic assessment at 12 weeks of fracture healing (n=4), showed there was excellent clinical union and healing

with minimal external callus formation at the end point. A rapid return of the cortical bone and the remodelling of callus were seen at week-12 (Figure 3d). Primary bone union occurred in 50% of the birds (n=2/4) and 50% of the birds (n=2/4) were healed with secondary union (callus formation). The remodelling of callus occurred in 50% (n=2/4) of the birds in this group, while 50% (2/4) showed callus united at the proximal and distal sides of the bone (Figure 4d). Similarly, Gull et al. (2012) reported that rigid stabilization led to minimal callus formation than fracture fixation with bandages. However, minimal callus formation is also important in radius and ulna fracture healing because, excessive callus formation could lead to synostosis formation.

The mean summary of this study indicated the values of the radiological assessments of fracture healing with ESF (Table 2). The fracture line was absent in all groups. Clinical union occurred at the shortest time of three weeks post-fracture fixation with ESF fixation in the birds. There were no significant differences between the respective post-fracture fixation groups

when the birds were kept for 12 weeks because the fracture was united earlier at 3 and at 6 weeks. The axial alignment was satisfactory in all groups because the ESF stabilized the fracture in the birds. Callus formation was significantly different among the groups at $p < 0.05$ and minimal callus was observed at 12 weeks and callus had significantly decreased (Table-2). Overall, results of this study showed that ESF provided good stabilization for the transverse fracture healing in the pigeon ulna in all groups. This ESF technique was used to compare the fracture healing process in a normal bird model. The serial radiographs were exposed for the confirmation of the fracture healing. The results of present study are in agreement with the observation of Rosenthal et al. (1992) regarding the stabilization of cockatoo femur and tibiotarsus fracture using the ESF Type-1 fixator connected with an acrylic bar. Such a fixation method provides excellent fracture repair and an early return to function. However, ESF pins are light in weight and cost-effective for fracture repair in birds (Bennett and Kuzma, 1992).

Many fracture fixation techniques described in the literature could be useful for the repair of fractures in birds. However, ESF is the most frequently used method for fracture stabilization in birds. This technique has its advantages as there is less damage to vascularity and it provides good stability (Hatt, 2009). Similar findings were observed by Redig (2001) and Bennett and Kuzma (1992) who reported that ESF provided good stability when pins were fixed in the thin cortex where they had minimum interference in the bone cavity. In this study, ESF pins were also inserted in the cortex of the pigeon's ulna and no any complications observed. Similarly, our results are in agreement on a review reports by Bennett and Kuzma, (1992) who mentioned that when a rigid fixation and proper reduction of fracture is not applied, fracture heal by indirect bone healing. Serial radiographic examination of ulna fracture showed good bone healing with ESF pins in this study. A radiographic assessment of the fracture healing showed that bone union, fracture line, axial alignment and callus formation were achieved between three and six weeks in all the groups with the ESF pins. However, similar findings were observed at 4.6 weeks in the ulna transverse fracture of the pigeons when the fracture was stabilized with the IM-ESF tie-in technique (Jalila, 2002). In addition, similar results were found in raptors by Redig (2001), who reported that clinical union was observed at 4.4 weeks after fracture stabilization with the ESF-IM fixator tie-in technique, and he further

found earlier clinical union at three weeks post-fixation in birds.

Radiographic healing of long bone fractures has shown a higher endosteal callus formation and less periosteal callus formation in birds'. In addition Kaveh et al. (2009) also found callus formation at 3 weeks post fracture stabilization in rabbit study. Furthermore, endosteal callus formation was observed at three weeks and six weeks. In a study, Bennett and Kuzma (1992) reported that ESF provided good bone alignment and strength, which promoted bone healing with minor callus formation. The ESF Type-1 has been proven to be effective for fracture fixation and is better tolerated by all birds. These results indicated that the fractures of the ulna bones that were fixed with ESF demonstrated good cortical union. The transverse fracture managed with the ESF showed healing with primary bone union as well as indirect bone union or callus formation. The same findings were observed by Rodriguez-Quiros et al. (2001). In this study, the ulna fracture was managed by rigid stabilization with ESF and provided good bone healing and remodelling after three months. Fracture healing in birds has not been well studied. While primary fracture healing in birds is lacking and primary bone healing occurs in mammals in cases of rigid stabilization (Bennett and Kuzma, 1992). Radiographic examination is the best method for assessment of fracture healing process in birds.

CONCLUSIONS

Fracture of pigeon ulna fixed with ESF provided excellent fracture healing and good clinical union. Results of this study showed ESF as a safe and suitable method for use in fracture fixation in birds. It was concluded that ESF might accelerate fracture healing and could be convenient for fracture fixation in birds for clinical fracture management. However, fracture fixation with ESF for wing bone stabilization needs to be further studied in birds.

COMPETING INTERESTS

The authors declare that they have no any competing interests.

REFERENCES

- Alievi MM, Schossler JE, Oliveira AN, Ferreira PA, Traesel C, Guimarães L (2008). Osteossíntese de úmero em pombos domésticos (*Columba livia*) associando-se pinos metálicos e polimetilmetacrilato intramedulares após

- osteotomia diafisária. Arquivo Brasileiro de Medicina Veterinária e Zootecnia, 60: 843-850.
- Bennett RA, Kuzma AB (1992). Fracture management in birds. *Journal of Zoo and Wildlife Medicine*, 23: 5-38.
- Bigham AS, Dehghani SN, Shafiei Z, Nezhad ST (2008). Xenogenic demineralized bone matrix and fresh autogenous cortical bone effects on experimental bone healing: radiological, histopathological and biomechanical evaluation. *Journal of Orthopaedics and Traumatology*, 9: 73-80.
- Coles B (2007). *Essentials of avian medicine and surgery*, Wiley; pp 131-141.
- Degernes LA, Roe SC, Abrams C (1998). Holding power of different pin designs and pin insertion methods in avian cortical bone. *Veterinary Surgery*, 27: 301-306.
- Donely B (2011). *Avian Medicine and Surgery in Practice*, Manson, UK; p 11.
- Goody A, Head J, Gianopoulos A, Liu S, McCoy B (2012). A novel approach to tibiotarsal fracture management in the Hawaiian Nene. *Journal of Wildlife Rehabilitation*, 32: 7-10.
- Gull JM, Saveraid TC, Szabo D, Hatt JM (2012). Evaluation of three miniplate systems for fracture stabilization in pigeons (*Columba livia*). *Journal of Avian Medicine and Surgery*, 26: 203-212.
- Hatt JM (2009). Osteosynthesis in avian surgery with special consideration on external fixation. *Praktische Tierarzt*, 90: 398-406.
- Jalila A (2002). Evaluation of the effects of intramuscular implantation of avian demineralized bone matrix (ADBM) and the use of ADBM in created ulna defects managed by the intramedullary pin-external skeletal fixator (IM-ESF) tie-in technique in pigeons. Doctoral dissertation.
- Jalila A, Redig PT, Wallace L J, Ogema T R, Bechtold JE, Kidder L (2004). The effect of chicken, pigeon, and turkey demineralized bone matrix (DBM) implanted in ulnar defects fixed with the intramedullary-external skeletal fixator (IM-ESF) tie-in in pigeons (*Columba livia*): histological evaluations. *The Medical Journal of Malaysia*, 59: 125-126.
- Kaveh K, Ibrahim R, Bakar MZA, Ibrahim TA (2009). Repair of compact bone critical sized defect with natural originated scaffold in rabbit. *Journal of Animal and Veterinary Advances*, 8: 1616-1623.
- Koivukangas A (2002). Effects of long-term clodronate administration on bone and on fracture healing in rat, University of Oulu.
- Kubiak M, Forbes N (2011). Veterinary care of raptors. *In Practice*, 33: 50-57.
- Redig PT (2001). Effective methods for management of avian fracture and other orthopedic problems. The 6th European Association of Avian Veterinarians Proceeding, Munich, Germany; pp 26-42.
- Redig P, Cruz L (2008). Fractures. In: *Avian Medicine*, Philadelphia, USA. Mosby Elsevier; pp 215-247.
- Rodriguez-Quiros J, San Roman F, Rodriguez-Bertos A (2001). Clinical and pathological changes induced by the use of corticocancellous auto graft during healing process in experimental fractures tibiotarsus in pigeons. The 6th European Association of Avian Veterinarians Proceeding, Munich, Germany; pp 43-49.
- Rosenthal K, Hillier E, Mathiessen D (1992). Stifle luxation repair in a Moluccan cockatoo and a barn owl. *Journal of Association of Avian Veterinarians*, 4: 235-238.
- Rush EM, Turner TM, Montgomery R, Ogburn AL, Urban RM, Sidebotham C, LaVasser A (2012). Implantation of a titanium partial limb prosthesis in a white-naped crane (*Grus vipio*). *Journal of Avian Medicine and Surgery*, 26: 167-175.