

ORIGINAL ARTICLE

The use of multicomponent ear drops in the treatment of otitis of various etiologies in animals

Mikhail Vladimirovich Arisov, Evgenia Nikolaevna Indyuhova, Gulnara Bakitovna Arisova
Ectoparasitosis Laboratory, VNIIP – FSC VIEV, Moscow, Russia

ABSTRACT

Objective: The objective of this study was to investigate the efficacy of newly developed multi-component ear drops for the treatment of otitis caused by parasites, bacteria, and fungi in dogs, cats, ferrets, fancy rabbits, and foxes.

Materials and Methods: A new drug for veterinary use was developed that contained levofloxacin hemihydrate (0.3%), clotrimazole (0.1%), dexamethasone sodium phosphate (0.1%), and moxidectin (0.01%). In the initial stage of otoacariasis (or the ear form of psoroptic scab), the drug was used twice with an interval of 5–7 days. When otoacariasis (psoroptic scab) was complicated by otitis of bacterial and/or fungal etiology, the drug was used as follows: instilled once a day, within 10–14 days in the ear canal for 2–5 drops of the drug. The study of therapeutic efficacy was performed on cats, dogs, ferrets, foxes, and fancy rabbits with ear pathology.

Results: The recovery of cats, ferrets, dogs, and foxes after the double use of ear drops during otoacariasis was established. In the ear form of psoroptic scab in fancy rabbits after treatment, *Psoroptes cuniculi* mites were not detected. The specific (antimicrobial and antifungal) activity of the drug was confirmed *in vivo* using the following scheme of drug use: the drug was instilled once a day, within 10–14 days in the ear canal, 2–5 drops of the drug in animals with external otitis and otitis media.

Conclusion: The rational combination of active components developed in this study is effective and safe for use in animals with microbial diseases of the ears.

ARTICLE HISTORY

Received August 29, 2019
Revised December 18, 2019
Accepted December 20, 2019
Published January 25, 2020

KEYWORDS

Otitis; animals; moxidectin;
levofloxacin; clotrimazole;
dexamethasone



This is an Open Access article distributed under the terms of the Creative Commons Attribution 4.0 Licence (<http://creativecommons.org/licenses/by/4.0>)

Introduction

One of the most common parasitic diseases in domestic animals is otoacariasis [1–5]. The pathogen of otoacariasis – *Otodectes cynotis* – causes inflammation and disrupts the functioning of the ceruminous glands. In addition, due to the parasitizing of *O. cynotis*, the host may have an allergic reaction. Mites may cause sensitization of the host to their salivary antigens. It is known that the disease is often complicated by the secondary microflora. Parasitizing of ear mites often leads to excessive growth of opportunistic microflora and fungi of the genus *Candida* and *Malassesia* [6,7]; therefore, a complicated form of otodecosis should be considered as an associative disease, the primary cause of which are mites *O. cynotis* and secondary are pathogenic and opportunistic bacteria and fungi [8].

In this regard, an integrated approach to therapy is necessary for the successful treatment of the disease with different etiologies. The finished dosage forms should contain, if possible, active components providing a comprehensive effect on the pathological focus while minimizing the number of injections of various drugs and the time spent by veterinary specialists on additional treatments [9]. Therefore, it is necessary to introduce products that are complex and safe in their medicinal composition, and are user-friendly and multi-faceted in their pharmacological action [10,11]. The causes of otitis in animals mainly come down to three main agents: parasitic, bacterial, and fungal [12–19]. Therefore, the use of ear drops with a single-component composition – acaricide or antibiotic or antimycotic – is impractical and allows veterinarians to create a combined drug with polytropic action.

Correspondence Evgenia Nikolaevna Indyuhova ✉ zxcv33980@yandex.ru 📧 Ectoparasitosis Laboratory, VNIIP – FSC VIEV, Moscow, Russia.

How to cite: Arisov MV, Indyuhova EN, Arisova GB. The use of multicomponent ear drops in the treatment of otitis of various etiologies in animals. *J Adv Vet Anim Res* 2020; 7(1):115–26.

The German company Neoterica GmbH jointly and on the basis of CJSC Scientific Research and Production Company Ekoprom developed a drug formulation for veterinary use (levofloxacin hemihydrate, 0.3%; clotrimazole, 0.1%; dexamethasone sodium phosphate, 0.1%; moxidectin, 0.01%; and excipients) [20]. The combination of active ingredients and excipients is presented in the form of ear drops. The choice of the dosage form is associated with the possibility of rapid and free penetration of the drug into hard-to-reach places with otitis media of various localization. When auricular use is applied, the optimal concentration of the drug in the focus of inflammation achieves. Systemic absorption of active components of the drug (levofloxacin, clotrimazole, moxidectin and dexamethasone) is very low, and the drug is practically not absorbed and does not enter the systemic blood.

In a previous report [21], the need for treatment of secondary bacterial and/or fungal otitis after the use of macrocyclic lactones in mono mode for parasitic otitis is noted. This drug contains clotrimazole, which has a pronounced fungicidal action [22]. Clotrimazole (imidazole derivative) is a broad-spectrum antifungal agent for topical use [23]. The antifungal effect of clotrimazole is associated with disturbances in ergosterol synthesis forming the cell membrane of fungi, which leads to the changings in the membrane permeability and causes cell lysis. Clotrimazole is active against *Aspergillus niger*, *Microsporum* spp., *Trichophyton* spp., *Candida* spp., and *Malassezia pachydermatis*. Clotrimazole is practically not absorbed through intact and inflamed skin [24,25].

The drug includes an antibiotic – levofloxacin. Levofloxacin is a compound of the fluoroquinolone group and has a broad spectrum of antibacterial action against gram-positive and gram-negative bacteria, including *Staphylococcus* spp., *Streptococcus* spp., *Pseudomonas* spp., *Escherichia coli*, *Proteus mirabilis*, *P. vulgaris*, *P. mirabilis*, *Staphylococcus* spp., *Mycoplasma* spp., and *Chlamydia* spp. It blocks bacterial topoisomerase IV and DNA-gyrase (topoisomerase II) – enzymes that are necessary for replication, transcription, repair and recombination of DNA, and causes profound morphological changes in the cytoplasm, cell wall, and membrane of bacteria [26]. The use of this fluoroquinolone is associated with the risk of damage to animal cartilage growth points in this regard, so its use is limited in dogs and cats under the age of 4 months [27].

The dexamethasone sodium phosphate which is a part of drops of ear causes anti-inflammatory effect. Dexamethasone is a synthetic glucocorticoid, mainly used as an anti-inflammatory and immunosuppressive agent. It can inhibit allergic reactions, both immediate and delayed-type. When locally applied, the therapeutic activity of dexamethasone is due to anti-inflammatory, anti-allergic, and anti-proliferative effects. Dexamethasone reduces

capillary permeability and proliferation, local exudation, cell infiltration, and phagocytic activity; inhibits the formation of scar tissue; and helps to eliminate itching [28].

Moxidectin has a stimulating effect on the secretion of gamma-aminobutyric acid and causes a violation of muscle innervation, paralysis, and ectoparasite death by binding to postsynaptic receptors. It should be noted that a high therapeutic effect of the use of drugs based on moxidectin in the treatment of ectoparasitosis of domestic animals has been established [29,30].

The drug according to the level of exposure belongs to low-hazard substances (hazard class 4 according to GOST 12.1.007-76 Occupational Safety Standards System (OSSS). Harmful substances. Classification and general safety requirements (with Amendments N 1, 2)) [31] do not have a local irritating and skin resorptive action.

Efficacy study of each new drug for veterinary use is an essential condition. The drug efficacy is a measure of the degree of their positive effect on the course of the disease. Therapeutic efficacy studies of new drugs allow us to assess possible risk versus predicted benefit for target animals (e.g., dogs and cats). The conducted studies allow us to characterize the specific activity of the drug, its features and advantages as compared to previously known and well-studied drugs of a similar type of action. Furthermore, these studies confirm the safety of new drugs. Thus, therapeutic efficacy studies of new veterinary drugs are an integral part of the practical effectiveness, tolerability, and safety of using new pharmacological combinations in veterinary practice. The objective of this study to assess the efficacy of new multicomponent ear drops for otitis of parasitic, bacterial, and fungal origin in dogs, cats, ferrets, fancy rabbits, and foxes.

Materials and Methods

Ethical approval

The study of the efficacy of the drug was approved at the meeting of the Scientific Council of the Federal Scientific Center (No. 2019/04/FSC VIEV RAS). The research work was carried out in accordance with the legislation of the Russian Federation [32] and international standards [33].

The study of the acaricidal activity of the drug against scabies ticks *in vitro*

The acaricidal activity of the drug was studied on 630 isolated *P. cuniculi* ticks. The experiments were carried out according to the method proposed by Strinadkin et al. [34] In the central part of white tissues, 9 × 9 or 10 × 10 cm in size, 30 ticks in the adult or nymph phase were placed. The tissue was placed in a Petri dish, the test liquid (0.0001%; 0.001%; 0.01%; 0.05%; 0.1%; and 0.2% concentration of moxidectin in the preparation) was applied dropwise to

it in a volume of 1–1.5 ml and left at room temperature (+18–20°C). After 24, 48, and 72 h, the state of ticks was determined. The experiments were performed in triplicate. Each experiment was accompanied by control.

Ticks were considered dead when they completely had no response to light, thermal stimuli; paralyzed ones were incapable of movement, but with a response. A light microscope was used for evaluating the activity of ticks. To activate ticks before and after drug effect, a heat source “Sterilizer with a thermostat for determining the viability of sarcoptoid ticks” was used.

Determination of antimicrobial and antifungal activity of the drug in vitro

To study bactericidal activity, *E. coli* (stamp 1257), *S. aureus* (stamp 906), and *Pseudomonas aeruginosa* (strain ATCC 27853) were used as test microorganisms. They are cultivated on the following nutrient media: *Escherichia coli* – on Endo agar at 35.0–37.0°C for 24 h, *Staphylococcus aureus* – on casein broth at 32.5±2.5°C for 18–24 h, *Pseudomonas aeruginosa* – on meat-peptone mug with the addition of 40% solution of glucose at 37°C for 18–24 h.

Antimicrobial activity was studied by a suspension method. About 4.5 ml of the solution was poured into sterile tubes into which 0.5 suspensions of test microorganisms or a broth culture containing 1×10^9 c/ml were added and thoroughly mixed. At certain time intervals (5 min), 0.5 suspensions of the “test microorganism + model sample” are added to a test tube with 4.5 ml of sterile water, after which 0.1 ml of this sample is added to test tubes with 5 ml of liquid and to the surface solid nutrient medium. In control experiments, sterile water is used instead of the model sample.

The results of the experiment were evaluated by the presence or absence of the growth of microorganisms in liquid and solid nutrient media. The comparison is carried out with the control of the experience, which is the sowing of test microorganisms in a nutrient medium without adding a model sample.

In the study of the fungicidal activity of model samples, fungal cultures are used as test microorganisms: *C. albicans* (strain 15) – to evaluate fungicidal activity against fungi of the genus *Candida*; *Trichophyton gyrseum* (mus. Strain NIID) – to evaluate fungicidal activity against fungi of the genus *Trichophyton*; and *Malassezia sp.* (strain 14/13) – to assess fungicidal activity against fungi of the genus *Malassezia*.

The conditions for the cultivation of test mushrooms. They cultivate on the following nutrient media: *C. albicans* – on Saburo broth, Sabar agar at a temperature of 27°C for 2–10 days; *T. gyrseum* – on Saburo broth, Sabar agar at a temperature of 27°C for 28 days; and *Malassezia sp.* – on

Saburo broth with the addition of olive oil at a temperature of 36°C for 24–48 h however, in some cases, malassezia growth can be observed only on 3–4 days.

The fungicidal activity was studied by a suspension method. Each solution in an amount of 4.5 ml was poured into sterile tubes into which 0.5 suspension of test mushroom containing 1×10^9 CFU / ml was added and thoroughly mixed. At certain time intervals (15 min), 0.5 suspension of “test mushroom + model sample” is added to a test tube with 4.5 ml of sterile water, then 0.1 ml of this sample is placed in test tubes with 5 ml of liquid and onto the surface solid nutrient medium. In control experiments, sterile water is used instead of model samples. The incubation temperature of crops in the thermostat and the timing of the results of the experiment depend on the type of mushroom. The results of the experiment were evaluated by the presence or absence of fungal growth in liquid and solid nutrient media. The comparison is carried out with the control of the experience, which is the sowing of the test mushroom in a nutrient medium without adding a model sample.

Dosing schedule, method of administration, and use of the drug

The drug for veterinary use contains active ingredients such as levofloxacin hemihydrate, 0.3%; clotrimazole, 0.1%; dexamethasone sodium phosphate, 0.1%; moxidec-tin, 0.01%; and excipients: dimethyl sulfoxide, tween-80, and polyethylene glycol (PEG 400).

In the initial stage of otoacariasis (or the ear form of psoroptic scab), the drug is used twice at an interval of 5–7 days. The external auditory meatus is cleaned from scabs and crusts, then two to five drops of the preparation are instilled into each ear (for cats, small dogs, ferrets, and rabbits, two to three drops; for medium dogs and foxes, four drops; for large dogs, five drops). The auricle is folded along in half, and its base is massaged. If the animal shakes its head after using the drug, it is necessary to fix the head for several minutes to prevent the splashing of preparation. The drug must be injected into both ears, even if clinical signs of disease are detected in only one ear. If otoacariasis (psoroptic scab) is complicated by otitis media of bacterial and/or fungal etiology, the drug was used as follows: 2–5 drops of the drug were instilled once a day within 10–14 days into the ear canal.

All animals were kept in standard conditions at full feeding, under optimal care [35]. They did not receive local and systemic therapy with antibiotics, antimycotics, corticosteroids for 30 days prior to testing. Animals with perforated eardrums were not included.

Inspection of animals with ear pathology: assessment of the head position in space; palpation of the ear and

lymph nodes near the ear canal; the presence of excretion, odor from the external auditory canal, hearing screening in an animal. Examination with an otoscope: holding an inspection of the vertical and horizontal channels, checking the integrity of the eardrum. During the treatment of animals with ear pathology, there was no increase in total body temperature.

Experimental groups

The diagnosis was made comprehensively, based on anamnesis, epizootological data, clinical signs, otoscopy, and laboratory tests (microbiological examination of swabs from the auditory canals and/or acarological examination of the contents of the auditory canals).

The preparations (smears from the ear canal) were initially stained with Diff-Quik® stain. The obtained material was fixed by heating above the burner flame. The finished preparations were evaluated under an $\times 100$ lens (under immersion) using a Zeiss light microscope with an AxioCamHRc camera. Examples of smear assessment results are presented in Figure 1.

The study of the antimicrobial and antifungal activity of the drug was carried out on the basis of veterinary clinics in Moscow and the Moscow region in accordance with

regulatory documents [36,37]. The scrapings were taken from the inner surface of the auricle using a sterile cotton probe-tampon of the transport system, intensively rotating it in the ear canal.

Acarological examination of the auditory meatuses was performed using a light microscope with an abiotic method of research: the particles of the tested material were transferred onto a glass slide, filled with some few drops of kerosene, covered with another glass slide, and examined (A.M. Priselkova's method).

The first group with a diagnosis of otoacariasis included 8 dogs, 28 cats, 25 foxes, and 13 ferrets and the second group included 27 rabbits diagnosed with ear psoroptic scab. 32 cats, 27 dogs, 8 rabbits, 6 ferrets, and 8 foxes of different breeds and ages had a diagnosis of otitis of bacterial and/or fungal etiology and were selected for the experiment.

Result and Discussion

Evaluation of the efficacy of an acaricidal agent against scabies mites in vitro

Acaricidal activity of the drug was studied by conventional methods on isolated ticks. The results of the study

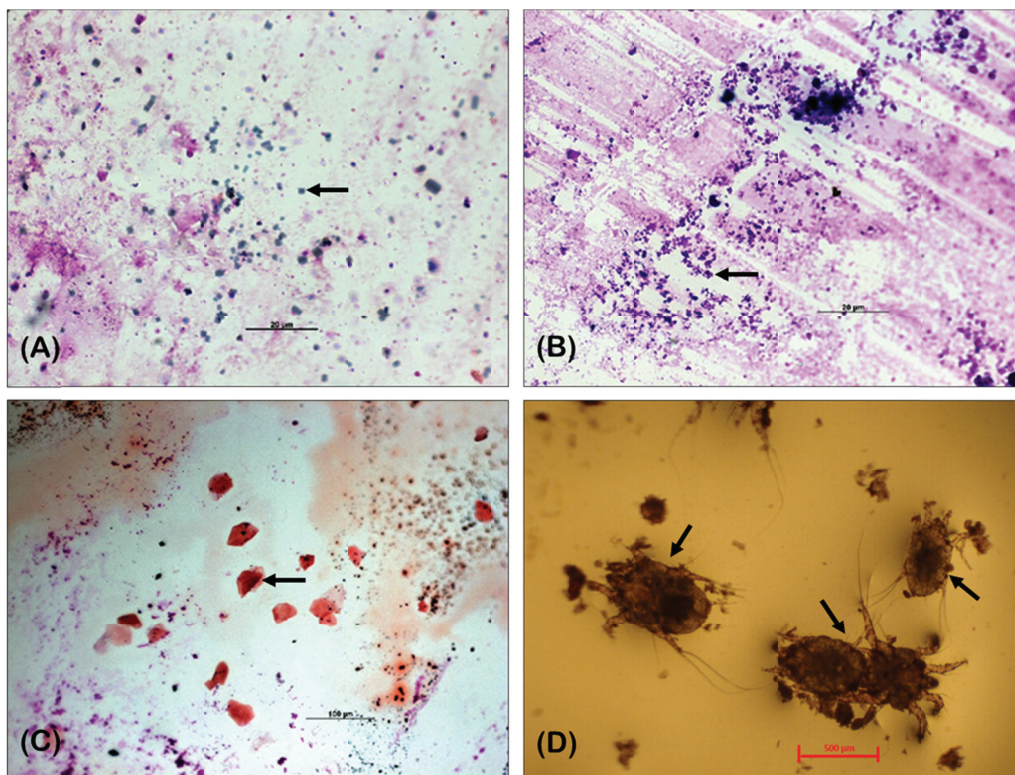


Figure 1. (A) *Mallasezia* spp., (B) *Staphylococcus* spp., (C) material from the dog's ear after treatment. Keratinized epithelial cells are present, (D) microscopy of scrapings from the inner surface of the auricle of the fox with otoacariasis (*Otodectes cynotis*).

Table 1. The results of the study of acaricidal activity of the drug after 24, 48 and 72 h.

The concentration of the drug for moxidectin, %	Number of ticks	Research results								
		After 24 h			After 48 h			After 72 h		
		Actively moving	Paralyzed	Dead	Actively moving	Paralyzed	Dead	Actively moving	Paralyzed	Dead
Experiment No. 1										
0.0001	30	2	20	8	0	10	20	0	2	28
0.001	30	0	10	20	0	4	26	0	2	28
0.01	30	0	0	30	0	0	30	0	0	30
0.05	30	0	0	30	0	0	30	0	0	30
0.1	30	0	0	30	0	0	30	0	0	30
0.2	30	0	0	30	0	0	30	0	0	30
Control (distilled water)	30	30	0	0	30	0	0	30	0	0
Experiment No. 2										
0.0001	30	4	22	4	2	20	8	0	12	18
0.001	30	0	14	16	0	10	20	0	4	26
0.01	30	0	0	30	0	0	30	0	0	30
0.05	30	0	0	30	0	0	30	0	0	30
0.1	30	0	0	30	0	0	30	0	0	30
0.2	30	0	0	30	0	0	30	0	0	30
Control (distilled water)	30	30	0	0	30	0	0	30	0	0
Experiment No. 3										
0.0001	30	5	10	15	4	4	22	2	1	27
0.001	30	0	3	27	0	2	28	0	0	30
0.01	30	0	0	30	0	0	30	0	0	30
0.05	30	0	0	30	0	0	30	0	0	30
0.1	30	0	0	30	0	0	30	0	0	30
0.2	30	0	0	30	0	0	30	0	0	30
Control (distilled water)	30	30	0	0	30	0	0	30	0	0

are presented in Table 1. Based on Table 1, it follows that the drug with concentrations of moxidectin in the range of 0.01%–0.2% has a pronounced acaricidal effect. The lowest effective concentration of moxidectin in the preparation is 0.01%.

Determination of antimicrobial and fungicidal activity of the drug in vitro

Evaluation of antimicrobial and fungicidal activity was carried out on the basis of seven concentrations of levofloxacin hemihydrate (0.1%; 0.15%; 0.2%; 0.25%; 0.3%; 0.35%; 0.4%; Table 2) and six concentrations of clotrimazole (0.05%; 0.1%; 0.15%; 0.2%; 0.25%; 0.3%; Table 3).

To study the bactericidal activity (Table 4), *E. coli* (stamp 1257), *S. aureus* (stamp 906), and *P. aeruginosa* (strain ATCC 27853) were used as test microorganisms.

Antimicrobial activity was studied by a suspension method. The concentration of the agent is considered

effective when the experiment which was repeated three times at a certain exposure time gives a negative result (lack of growth of microorganisms) in the presence of a typical growth of the test culture in the control.

A typical growth of microorganisms (*E. coli*, *S. aureus*, and *P. aeruginosa*) was observed in the control. It can be seen from Table 4 that levofloxacin hemihydrate exhibits an antimicrobial effect on all three microorganisms in concentrations of 0.1%–0.4% and precisely those microorganisms that are excreted in animal otitis media. In the study of fungicidal activity (Table 5) of model samples, fungal cultures were used as test microorganisms: *C. albicans* (strain 15), *T. gyrseum* (mus. strain NIIID), and *Malassezia* sp. (strain 14/13).

The concentration of the agent is considered effective when the experiment that was repeated three times at a certain exposure time gives a negative result (lack of mushroom growth) in the presence of a typical growth of the test fungus in the control.

Table 2. The model samples composition.

Component name	Sample No.						
	1	2	3	4	5	6	7
	The concentration of substances, %						
Levofloxacin hemihydrate	0.1	0.15	0.2	0.25	0.3	0.35	0.4
Clotrimazole	0.1	0.1	0.1	0.1	0.1	0.1	0.1
Dexamethasone sodium phosphate	0.1	0.1	0.1	0.1	0.1	0.1	0.1
Moxidectin	0.01	0.01	0.01	0.01	0.01	0.01	0.01
Dimethyl sulfoxide	20.0	20.0	20.0	20.0	20.0	20.0	20.0
Tween-80	2.0	2.0	2.0	2.0	2.0	2.0	2.0
Polyethylene glycol (PEG 400)	Up to 100.0	Up to 100.0	Up to 100.0	Up to 100.0	Up to 100.0	Up to 100.0	Up to 100.0

Table 3. The model samples composition.

Components name	Sample No.					
	1	2	3	4	5	6
	The concentration of substances, %					
Levofloxacin hemihydrate	0.3	0.3	0.3	0.3	0.3	0.3
Clotrimazole	0.05	0.1	0.15	0.2	0.25	0.3
Dexamethasone sodium phosphate	0.1	0.1	0.1	0.1	0.1	0.1
Moxidectin	0.01	0.01	0.01	0.01	0.01	0.01
Dimethyl sulfoxide	20.0	20.0	20.0	20.0	20.0	20.0
Tween-80	2.0	2.0	2.0	2.0	2.0	2.0
Polyethylene glycol (PEG 400)	Up to 100.0	Up to 100.0	Up to 100.0	Up to 100.0	Up to 100.0	Up to 100.0

In the control, a typical growth of fungi was observed (*C. albicans*, *T. gyrseum*, and *Malassezia sp.*). From the table, you can set the optimal concentration of clotrimazole – 0.1%. Thus, a preparation with a moxidectin concentration of 0.01% has a pronounced acaricidal effect. The pronounced antimicrobial and fungicidal activity of levofloxacin hemihydrate (0.3%) and clotrimazole (0.1%) was revealed, respectively, related to strains of microorganisms and fungi that are specific for veterinary medicine and most often appear in cases of otitis media of bacterial and/or fungal etiology in animals (complicated form of otodectosis and psoroptosis). Accordingly, the ingredients of the pharmaceutical composition are determined based on our own research. In addition, our drug contains dexamethasone sodium phosphate at a concentration of 0.1%. This concentration of dexamethasone sodium phosphate is often used in medicinal compositions applied to treat ear pathologies [38,39].

Study of the efficacy of the drug for parasitic otitis in dogs, cats, furbearers and fancy rabbits

The first group consisted of 8 dogs, 28 cats, 25 foxes, and 13 ferrets diagnosed with otoacariasis and the second group

included 27 rabbits diagnosed with psoroptic scab. In cats, dogs, ferrets, and foxes, otoacariasis was manifested by the following clinical signs: anxiety of animals, inflammation of the skin of the external auditory canal, and itching in the ear. During the examination of animals, wounds were found along the edges of the auricle, and the external auditory meatus was heavily polluted with a dark crumbly exudate. The diagnosis was confirmed by microscopic investigation of scrapings from the outer ear (distal part of the auditory meatus) according to the Priselkova's method. At the same time, many *O. cynotis* mites were found at all stages of development – from egg to imago (Fig. 1).

After using the drug, the general condition of the animals of the first group was improved, the hyperemia and swelling of the inner surface of the auricles disappeared, the elasticity of the auricle was restored, they became almost clean, *O. cynotis* mites were not detected after the course of treatment, only dead mites and its parts were fixed. After double treatment, mites that were alive were not found. Thus, the 100% efficacy of ear drops is confirmed by two acarological studies. The following clinical signs were observed in rabbits diagnosed with the ear form of psoroptic scab: anxiety, severe itching, inflammation of

Table 4. Antimicrobial activity of model samples.

Levofloxacin hemihydrate, %	Microorganisms		
	<i>Escherichia coli</i>	<i>Staphylococcus aureus</i>	<i>Pseudomonas aeruginosa</i>
Experiment No. 1			
0.1	+	+	+
0.15	+	+	+
0.2	+	+	+
0.25	+	+	+
0.3	+	+	+
0.35	+	+	+
0.4	+	+	+
Control (sterile water)	-	-	-
Experiment No. 2			
0.1	+	+	+
0.15	+	+	+
0.2	+	+	+
0.25	+	+	+
0.3	+	+	+
0.35	+	+	+
0.4	+	+	+
Control (sterile water)	-	-	-
Experiment No. 3			
0.1	+	+	+
0.15	+	+	+
0.2	+	+	+
0.25	+	+	+
0.3	+	+	+
0.35	+	+	+
0.4	+	+	+
Control (sterile water)	-	-	-

+ = fungicidal activity, - = no fungicidal activity.

the inner surface of the auricle, and the diagnosis was confirmed by the detection of *P. cuniculi* mites in the ear crusts. After treatment, the hyperemia and puffiness of the skin of the inner surface of the auricles in the rabbits were disappeared, they became practically clean, *P. cuniculi* mites were not detected after two treatments. Infection of fancy rabbits with *P. cuniculi* ear mites can cause the development of external and otitis media [40].

There is an extensive market for veterinary drugs aimed at the treatment of parasitic diseases of domestic animals. Drugs are available in the form of spot-on, tablets for oral use, insectoacaricidal collars (polymeric tapes), and sprays for external use. The active substances are compounds of various classes and different mechanisms of action [41]. The use of effective active ingredients with a

Table 5. Fungicidal activity of model samples.

Clotrimazole, %	Microorganisms		
	<i>Candida albicans</i>	<i>Trichophyton gyrseum</i>	<i>Malassezia sp.</i>
Experiment No. 1			
0.05	-	-	-
0.1	+	+	+
0.15	+	+	+
0.2	+	+	+
0.25	+	+	+
0.3	+	+	+
Control (sterile water)	-	-	-
Experiment No. 2			
0.05	-	-	-
0.1	+	+	+
0.15	+	+	+
0.2	+	+	+
0.25	+	+	+
0.3	+	+	+
Control (sterile water)	-	-	-
Experiment No. 3			
0.05	-	-	-
0.1	+	+	+
0.15	+	+	+
0.2	+	+	+
0.25	+	+	+
0.3	+	+	+
Control (sterile water)	-	-	-

+ = fungicidal activity, - = no fungicidal activity.

safe minimum concentration allows minimizing the strain on the animal body by chemotherapeutic agents. In addition, the combination of some active ingredients in a single dosage form allows creating a universal drug for veterinary use.

It should be noted that not only the choice of acaricide but also its pharmacological lability in relation to other medicinal substances does matter during creating a new veterinary drug with acaricidal properties. For example, in otoacariasis (ear form of psoroptic scab), in some cases, parallel use of antimicrobial and anti-inflammatory drugs is necessary. Therefore, the creation of new multicomponent effective combinations in the form of ear drops is an important task for veterinary specialists.

It is known that parasitizing ear mites in animals provokes serious inflammation of the skin and hyperkeratosis of its papillary layer [42]. The article by Yang and Huang [43] reflects the efficacy of various drugs aimed at the

treatment of otoacariasis. Thus, the efficacy of the drug in the form of injections based on doramectin was 90.0%, the therapeutic effect of the spot-on use of selamectin was 96.7%. After using fipronil in the ears directly, a therapeutic effect of 94.9% was established. An efficacy of 92.8% was detected with the use of insectoacaricide drops based on 10% imidacloprid and 1% moxidectin in the spot-on form. Ivermectin-based injections showed 90.0% efficacy. The efficacy of ivermectin-based otic ear drops – 92.5%.

In our presented studies, 100% therapeutic efficacy of otic ear drops based on moxidectin, levofloxacin hemihydrate, clotrimazole, dexamethasone sodium phosphate in the treatment of parasitogenic otitis was noted. Treatment of parasitic otitis with acaricide agents in combination with antimycotics and antibiotics can prevent the development of complicated otitis. In addition, it is possible to use this pharmacological composition for the treatment of postotoacariasis (postpsoroptic scab) complications.

Study of the efficacy of the drug in external acute and chronic otitis of bacterial and/or fungal origin (complicated forms of otoacariasis or psoroptic scab) in dogs, cats, furbearers, and fancy rabbits

According to Korbelik et al. [44] external otitis of bacterial or fungal etiology reaches 10%–20% among all diseases of dogs. Tang et al. [45] note that out of 221 cases of ear pathologies in dogs were observed 84.62% of animals with external otitis. In addition, bacterial etiology of external otitis was found in 44.10% of dogs, and in 21 cases, external otitis of fungal etiology was detected (32.31 %). The diagnosis in our studies was made comprehensively, based on history, epizootological data, clinical signs, otoscopy, and laboratory tests (microbiological examination of a smear from the auditory canal). Confirmation of the etiology of otitis in the laboratory took place within 5–7 days. Seven cats, eight dogs, two fancy rabbits, one ferret, and 2 foxes were diagnosed: acute otitis external of bacterial and/or fungal etiology.

Clinical signs in animals diagnosed with acute external otitis of bacterial and/or fungal etiology: defluidum from the ear of a different nature, redness and swelling of the external auditory canal, often a strong smell of secretion, and pain on palpation in the ear. The skin of the inner surface of the auricle is hyperemic, edematous with ulcerations. If the animal is anxious, there is an itching in the ear. The auditory acuity is intact. In cases of otoscopy in the acute stage, hyperemia and infiltration of the skin were noted. In the depth of the auditory meatus, a mushy mass was observed. In some animals, the eardrum is moderately hyperemic.

Nine cats, seven dogs, three decorative rabbits, three ferrets, and two foxes were diagnosed with chronic external otitis of bacterial and/or fungal etiology. Clinical

signs in animals diagnosed with chronic external otitis of bacterial and/or fungal etiology: defluidum from the ear of a different nature, redness and slight swelling of the external auditory meatus, often a strong smell of secretion, and pain on palpation in the ear. The skin of the inner surface of the auricle is hyperemic, edematous, with ulcerations. The owners have noted the long-term nature of the course of the disease (more than 4–6 weeks). Microbiological studies of ears secretion in animals were carried out according to the appropriate generally accepted methods, and conditionally pathogenic microflora and/or fungi were found when analyzing the contents of the auditory meatus.

In cats, a diagnosis of acute external otitis of bacterial etiology revealed *S. aureus*, *S. simulans*; *M. pachydermatis* detected with a diagnosis of acute external otitis of the fungal etiology; diagnosed with acute external otitis of mixed etiology revealed by *M. pachydermatis* with *S. hyicus*, *S. aureus*, and *S. simulans*. *S. simulans* and *S. aureus* were detected in cats with a diagnosis of chronic external otitis media of bacterial etiology; *M. pachydermatis* and yeast-like fungi of the genus *Candida* were diagnosed with a diagnosis of chronic otitis externa of the fungal etiology; chronic external otitis of bacterial and fungal etiology revealed *M. pachydermatis* with *S. hyicus*, *S. aureus*.

In dogs, through a diagnosis of acute external otitis of bacterial etiology, *S. simulans* and *S. aureus* were detected; *M. pachydermatis* was found with acute external otitis of fungal etiology; with a diagnosis of acute external otitis of mixed etiology – *M. pachydermatis* with *S. aureus*, *S. simulans* and yeast-like fungi of the genus *Candida* with *S. aureus*. In dogs with chronic external otitis media of bacterial etiology, conditionally pathogenic microflora of *S. hyicus* and *S. aureus* has been established; with a diagnosis of chronic external otitis of fungal etiology, *M. pachydermatis* and yeast-like fungi of the genus *Candida* were detected; *S. aureus* + *M. pachydermatis* were detected in chronic external otitis of mixed etiology.

In fancy rabbits, with acute external otitis of bacterial etiology, *S. simulans* was detected; in chronic external otitis, *S. hyicus* and *S. simulans* were detected; diagnosed with acute external otitis of fungal etiology, *M. pachydermatis* was detected. In ferrets, acute external otitis of bacterial etiology was accompanied by a marked increase in *S. aureus*; *M. pachydermatis* was detected with a diagnosis of chronic external otitis of fungal etiology; *M. pachydermatis* + *S. hyicus* and *S. aureus* + yeast-like fungi of the genus *Candida*. In foxes with acute external otitis of bacterial etiology, *S. hyicus* was detected; in chronic external otitis – *S. hyicus*; with a diagnosis of acute external otitis of bacterial and fungal etiology, *S. hyicus* and *M. pachydermatis* were detected, and in chronic external otitis, *S. aureus* and yeast-like fungi of the genus *Candida* were found.

During the treatment of animals with a diagnosis of acute external otitis of bacterial and/or fungal etiology, there was no pain in the ear, local temperature, and hyperemia in 3–5 days after the start of the drug use. During the examination of eight animals (two cats, three dogs, one fancy rabbit, one ferret, and one fox) on the eleventh day after treatment, the absence of clinical signs of the disease and the growth of conditionally pathogenic microflora and fungi in the auditory canal were found. The rest of the animals diagnosed with acute external otitis of bacterial and/or fungal etiology after 14 days of using the ear drops: the ears became cleaner, itching and inflammation were stopped, and no conditionally pathogenic microflora and fungi were detected during microbiological studies.

During the treatment, animals with a diagnosis of chronic external otitis of bacterial and/or fungal etiology determined the absence of pain in the ear, local temperature and hyperemia in 2–7 days after the start of the treatment. During the examination of two cats and one fancy rabbit on the eleventh day of the treatment, there was no clinical evidence of disease; and in microbiological studies of swabs from the auditory meatus, no conditionally pathogenic microflora and fungi were detected. Other animals had no signs of inflammation in 14 days after the application of the ear drops; no conditionally pathogenic microflora and fungi were detected during microbiological studies of swabs from the external auditory meatus. During the treatment and after it within 10–14 days, no complications and side effects were noted in animals (cats, dogs, fancy rabbits, ferrets, and foxes).

Study of the efficacy of the drug in acute and chronic otitis media of bacterial and fungal origin (complicated forms of otocariasis or psoroptic scab) in dogs, cats, furbearers, and fancy rabbits

The diagnosis was made in a comprehensive manner. Confirmation of the etiology of otitis in the laboratory took place for 5–7 days. Eight cats, six dogs, one fancy rabbit, and one ferret were diagnosed with acute otitis media of bacterial and/or fungal etiology. Clinical signs in animals diagnosed with acute otitis media of bacterial and/or fungal etiology: hearing disorder, abundant defluvium of a different nature from the ear, redness and swelling of the ear canal, narrowing of the ear canal, a strong defluvium smell, and pain on palpation in the ear area. The skin of the inner surface of the auricle is hyperemic, edematous, cankering, animal shakes its head, holds its head on one side when the one ear is hurt, rubs affected ear with paws, has anorexia. During the otoscopy, inflammation of the eardrum and the presence of exudate were detected.

Animals with a diagnosis of chronic bacterial otitis media and/or fungal etiology were eight cats, six dogs, two fancy rabbits, one ferret, and four foxes. Clinical signs

in animals diagnosed of chronic otitis media of bacterial and/or fungal etiology: defluvium from the ear of a different nature, redness and swelling of the external auditory canal, narrowing of the auditory canal, often a strong smell of leakage, and pain to palpation in the ear area. The skin of the inner surface of the auricle is hyperemic, edematous, cankering. During the otoscopy, turbidity and thickening of the eardrum were detected. Hearing disorder was noted. The owners have noted the long-term nature of the disease (more than 6–8 weeks).

Microbiological studies of defluvium from ears in animals were carried out according to the appropriate generally accepted methods, and conditionally pathogenic microflora and/or fungi were found when analyzing the contents of the auditory canals.

In cats, acute and chronic otitis media of bacterial etiology revealed *S. aureus*, *S. hyicus*; in acute otitis media of fungal etiology, *M. pachydermatis* and yeast-like fungi of the genus *Candida* were identified; in animals, with a diagnosis of acute otitis media of mixed etiology, *S. simulans* + *M. pachydermatis* and *S. simulans* + yeast-like fungi of the genus *Candida* were found. In cats with chronic otitis media of fungal etiology, *M. pachydermatis* was detected; in chronic otitis media with bacterial and fungal etiology, *S. aureus* + *M. pachydermatis*, and *S. simulans* + *M. pachydermatis* were defined.

In dogs diagnosed with acute otitis media with a bacterial etiology, *S. hyicus* was detected; in chronic otitis media with bacterial etiology, *Staphylococcus aureus* and *S. hyicus* were detected. *M. pachydermatis* and yeast-like fungi of the genus *Candida* were found in animals diagnosed with acute otitis media of fungal etiology. In dogs with acute otitis media, bacterial and fungal agents of *S. simulans* + yeast-like fungi of the genus *Candida* and *S. aureus* + yeast-like fungi of the genus *Candida* were detected. In the chronic course of otitis media with fungal etiology, *M. pachydermatis* and yeast-like fungi of the genus *Candida* were identified; in dogs diagnosed with chronic otitis media with bacterial and fungal etiology, *S. aureus* + yeast-like fungi of the genus *Candida* and *S. simulans* + *M. pachydermatis* were found.

In fancy rabbits with acute otitis media, *S. simulans* was detected; in rabbits, with chronic otitis media, *S. hyicus* was found. Yeast fungi of the genus *Candida* were found in one rabbit diagnosed with chronic otitis media of fungal etiology. In ferrets with acute otitis media, *S. simulans* was detected; in chronic otitis media of bacterial and fungal etiology, yeast-like fungi of the genus *Candida* + *S. simulans* were detected.

In foxes with a chronic course of otitis media, *S. aureus* + *M. pachydermatis* was detected; *S. simulans* + yeast-like fungi of the genus *Candida* and *Staphylococcus hyicus* + *M. pachydermatis*; in the chronic course of otitis media with bacterial etiology, *S. hyicus* was detected.

Animals with a diagnosis of acute otitis media of bacterial and/or fungal etiology had no pain in the ear, the elevation of local temperature and hyperemia in 4–7 days after the start of the drug use.

During the examination of animals for 10 days after using ear drops (two cats, one dog, and one ferret), there were no clinical signs, and during microbiological examination of scrapings from the auditory canal, conditionally pathogenic microflora and fungi did not reveal in four animals. Other animals with otitis media after 14 days of using the ear drops had no itching and inflammation; no conditionally pathogenic microflora and fungi were detected during microbiological examinations of swabs from the external auditory canal.

Animals with a diagnosis of chronic otitis media with a bacterial and/or fungal etiology had no pain in the ear, an increase in local temperature, and hyperemia in 5–8 days after the start of treatment. In 14 days after the application of the ear drops, the signs of inflammation were ceased and microbiological studies of swabs from the external auditory canal showed no conditionally pathogenic microflora and fungi.

During and after treatment for 10–14 days, no complications and side effects were observed in animals (dogs, cats, ferrets, fancy rabbits, and foxes). Usually, a combination of active substances is used in the form of ear drops. For example, they are ciprofloxacin and dexamethasone, gentamicin C, and hydrocortisone [46]. These drugs also have a positive therapeutic effect. However, the introduction of complex multicomponent drops allows you to minimize the number of veterinary manipulations and to observe the recovery of animals in a shorter time accordingly. In addition, our drug can be used to many types of animals (dogs, cats, fancy rabbits, ferrets, and foxes).

In an article by King et al. [47], the study of the efficacy of combination drugs aimed at the treatment of external otitis is illustrated. Drugs are presented in gel form (active ingredients are florfenicol, terbinafine, and betamethasone acetate) and in the suspension form (active ingredients are hydrocortisone aceponate, miconazole, and gentamicin). The gel was applied twice with an interval of 7 days, and the suspension was applied daily for 5 days. In general, a positive therapeutic effect was revealed; however, a relapse was observed in 11% of cases using the above drugs in sick animals.

A positive therapeutic effect was noted with the use of the combined drug based on marbofloxacin, clotrimazole and dexamethasone in the treatment of fungal otitis in dogs, compared with the local use of miconazole. The advantages of the combined drug were as follows: reduction of hyperemia, itching, which indicates the effective action of the glucocorticoid and implementation of its anti-inflammatory, anti-proliferative and antipruritic properties accordingly [48].

The authors presented the results of a study of the efficacy of a multicomponent drug in the ointment form with the following list of active ingredients: neomycin sulfate, nystatin, triamcypenol, and permethrin, so antibiotics, such as antimycotic, glucocorticoid, and acaricide, are contained in it. The drug showed a high therapeutic effect in parasitic, bacterial and fungal otitis [21]. In our opinion, the most convenient dosage form in the treatment of otitis of various etiologies is a solution for auricular use (ear drops) due to the rapid penetration of the drug into the inflammatory focus with minimal losses.

The composition of microbial associations in otitis media was studied in detail. Bacteria in the form of monoculture were isolated in 39.5% of cases, monoculture of fungi was detected in 27.2% of cases, in the form of microbial associations – 33.3% of cases. Thus, microorganisms in the form of monoculture were most often isolated in our studies. Our studies are consistent with the work [49], in which bacterial monoinfection is most often isolated in cases of otitis media in pets. In cases of otitis media, mixed microbial associations including microorganisms and microscopic fungi prevailed in studies [50].

Conclusion

The use of a pharmacological composition based on levofloxacin hemihydrate, clotrimazole, dexamethasone sodium phosphate, and moxidectin in the form of ear drops allows for simultaneous etiotropic, pathogenetic and symptomatic therapy. It must be specially noted that the use of polytropic drugs can stop the pathological process in the auditory analyzer caused by various agents (conditionally pathogenic microflora, fungi, and/or ear mites). The use of one drug with several pharmacological properties is more convenient from a practical and economic point of view for animal owners and veterinary specialists.

Acknowledgments

The funding source for this work is “Scientific-Production Firm “Ekoprom”.

Conflict of Interest

Authors declared that there is no conflict of interest.

Authors' Contributions

Mikhail Vladimirovich Arisov has prepared a study design, interpreted the results of experiments. Evgenia Nikolaevna Indyuhova conducted research in veterinary clinics, collected data, compiled a manuscript. Gulnara Bakitovna Arisova analyzed the data obtained, prepared a literature review on the research topic. All authors have confirmed the final version of the manuscript for publication.

References

- [1] Maslova EN. The clinical picture of otocariasis in dogs and cats. *Mod Probl Sci Educ* 2015; 2:779.
- [2] Combaros D, Boncea AM, Bourdeau P, Bruet V. Comparison of the methods for the diagnosis of otocariasis due to *Otodectes cynotis* in dogs and cats. *Vet Dermatol* 2019; 30(4):334-e96; doi:10.1111/vde.12753
- [3] Iovenko AV, Koval GM. Monitoring of contagious skin diseases of dogs and cats in Odessa. *Sci Messenger LNU Vet Med Biotechnol: Vet Sci* 2019; 21(93):160-3; doi:10.32718/nvlvet9328
- [4] Zhukov VM, Dolgopolova TS. Organopathology of cats' skin in the veterinary clinic of Barnaul. *Bull Altai State Agrarian Univ* 2018; 5(163):149-54.
- [5] Moskvina TV, Izrailskaia AV, Tsybul'sky AV. Parasites of stray and client-owned domestic cats in urban areas in Russia during 2000-2015. *Trop Biomed* 2018; 35(1):267-79.
- [6] Kostilyova OA. Staphylococcosis of dogs and cats, accompanying the manifestation of otocariasis. *Vet Pathol* 2007; 3:82-4.
- [7] Litvinov AM, Ivchenko OV, Kasyanov AI. *Malassezia* in animals. *Vet Med* 2010; 6:13-5.
- [8] Chudnova EM, Vorontsova AA. Treatment of otocariasis in cats. *Electron Sci J* 2017; 19:112-3.
- [9] Trofimova EN. Labor standards for the diagnosis of diseases of small domestic animals. *Proc Kazan State Acad Vet Med named after Bauman N.E.* 2011; 88:228-33.
- [10] Arisov MV, Belykh IP, Artyomov VV. Inspector Quadro – a complex drug for the treatment of ecto- and endoparasites in dogs and cats. *Russ Parasitol J* 2018; 12(2):75-84; doi:10.31016/1998-8435-2018-12-2-75-84
- [11] Arisov MV, Induyhova EN, Koshkarev EA, Arisova GB. Toxicity parameters of combined insectoacaricidal drug Neoterica Protecto 4. *Vet Zootechny Biotechnol* 2018; 2:57-63.
- [12] Korbelik J, Singh A, Rousseau J, Scott Weese J. Characterization of the otic bacterial microbiota in dogs with otitis externa compared to healthy individuals. *Vet Dermatol* 2019; 30:228-37; doi:10.1111/vde.12734
- [13] Tyler S, Swales N, Foster AP, Knowles TG, Barnard N. Otopscopy and aural cytological findings in a population of rescue cats and cases in a referral small animal hospital in England and Wales. *J Feline Med Surg* 2019; Article ID 1098612X19834969; doi:10.1177/1098612X19834969
- [14] Brilhante RSN, Rocha MGD, Guedes GMM, Oliveira JS, Araújo GDS, España JDA, et al. *Malassezia pachydermatis* from animals: planktonic and biofilm antifungal susceptibility and its virulence arsenal. *Vet Microbiol* 2018; 220:47-52; doi:10.1016/j.vetmic.2018.05.003
- [15] Goodale EC, Outerbridge CA, Write SD. *Aspergillus otitis* in small animals – a retrospective study of 17 cases. *Vet Dermatol* 2015; 27:3-10; doi:10.1111/vde.12283
- [16] Barnard N. Feline versus canine otitis: the difference in aetiology and management. In *BSAVA Congress Proceedings*, 2017, pp 241-2. Available via <https://doi.org/10.22233/9781910443439.27.7>.
- [17] Paterson S. Discovering the causes of otitis externa. In *Practice* 2016, May 7-11. Available via <https://doi.org/10.1136/inp.i470>.
- [18] Rotaru V, Dărăbuș G, Mederle N, Suici T, Sîrbu C, Luca I, et al. How useful are signalments to diagnose otitis externa in dogs and cats. *Med Vet* 2018; 51(3):84-8.
- [19] Pye C. *Pseudomonas otitis* externa in dogs. *Can Vet J* 2018; 59(11):1231-4.
- [20] Arisov MV, Induyhova EN, Antipov AA. The effectiveness of a new complex drug in the treatment of otocariasis in foxes based on histological examination of the skin. *Russ J Parasitol* 2016; 3(1):67-75; doi: 10.12737/18363
- [21] Roy J, Bedard Ch, Moreau M. Treatment of feline otitis externa due to *Otodectes cynotis* and complicated by secondary bacterial and fungal infections with Oridermyl auricular ointment. *Can Vet J* 2011; 52(3):277-82.
- [22] Dundar R, Iynen I. Single dose topical application of clotrimazole for the treatment of otomycosis: is this enough? *J Audiol Otol* 2019; 23(1):15-9; doi:10.7874/jao.2018.00276
- [23] Wiegand S, Berner R, Schneider A, Lundershausen E, Dietz A. Otitis externa: investigation and evidence-based treatment. *Dtsch Arztebl Int* 2019; 116:224-34; doi:10.3238/arztebl.2019.0224
- [24] Mahmoud A, Ghannoum MA, John R. Perfect JR (eds.). *Antifungal therapy*. 2nd edition, CRC Press Taylor & Francis Group, New York, 472 pp, 2019.
- [25] Hay R. Review therapy of skin, hair and nail fungal infections. *J Fungi* 2018; 4(3):99; doi:10.3390/jof4030099
- [26] Davis R, Bryson HM. Levofloxacin a review of its antibacterial activity, pharmacokinetics and therapeutic efficacy. *Drugs* 1994; 47(4):677-700; doi:10.2165/00003495-199447040-00008
- [27] Padeyskaya EN. Quinolones in pediatric practice and during pregnancy. Proof of their application. *Antimicrob Drugs* 2004; 6(4):377-93.
- [28] Carlotti Dn. The role of topical corticosteroids in the treatment of external otitis. *VETPHARMA* 2015; 1(23):34-6.
- [29] Arisov MV, Shemyakov DN, Induyhova EN. "Inspector" spray – the basis of a successful fight against otocariasis and ctenocephalides in dogs and cats. *Vet Zootechny Biotechnol* 2014; 9:23-7.
- [30] Arisov MV, Induyhova EN, Kuznetsova EA, Stepanov VA, Stepanov AA. Therapeutic efficacy of drugs "Gelmintal K" and "Gelmintal C". *Vet Zootechny Biotechnol* 2014; 10:6-9.
- [31] GOST 12.1.007-76 Occupational Safety Standards System (OSS). Harmful substances. Classification and general safety requirements (with Amendments N 1, 2).
- [32] Rules of work with the use of experimental animals, approved by Order No. 755 of August 12, 1977.
- [33] European convention for the protection of vertebrate animals used for experimental and other scientific purposes, Strasbourg, 18.III.1986.
- [34] Strinadkin PS, Andrichuk BV, Domatsky NI. Initial selection of new acaricides and studying their activity against sarcoptoid mites. *Vet Arachno-Entomol Issues*. 1980; 20:15-23.
- [35] Medvedsky VA, Sobolev DT, Mazolo NV. Feeding and housing dogs, cats, zoo animals and birds. *Data-Computing Centre of Treasury* 2014; 239 p.
- [36] Order of April 22, 1985 No. 535 The unification of microbiological (bacteriological) research methods used in the clinical diagnostic laboratories of medical institutions.
- [37] Guidelines for the laboratory diagnosis of animal dermatophytosis, approved by the Main Veterinary Department of the Ministry of Agriculture of the Russian Federation on March 18, 2008.
- [38] Mosges R, Schroder T, Baues CM, Sahin K. Dexamethasone phosphate in antibiotic ear drops for the treatment of acute bacterial otitis externa. *Curr Med Res Opin* 2008; 24(8):2339-47; doi:10.1185/03007990802285086
- [39] Wall GM, Stroman DW, Roland PS, Dohar J. Ciprofloxacin 0.3%/dexamethasone 0.1% sterile otic suspension for the topical treatment of ear infections: a review of the literature. *Pediatr Infect Dis J* 2009; 28(2):141-4; doi:10.1097/INF.0b013e31818b0c9c
- [40] Johnson JC, Burn CC. Lop-eared rabbits have more aural and dental problems than erect-eared rabbits: a rescue population study. *bioRxiv* 2019; 1-28; doi:10.1101/671859
- [41] Morris DO, Kennis RA. *Clinical dermatology, an issue of veterinary clinics: small animal practice*. Elsevier, Philadelphia, p 55, 2013. Available via <https://doi.org/10.1016/j.cvsm.2012.09.013>
- [42] Cherkay ZN. Experience in application of ear drops Anandin plus in otocariasis in cats. *Vet Feed* 2007; 6:27.
- [43] Yang C, Huang H-P. Evidence-based veterinary dermatology: a review of published studies of treatments for *Otodectes cynotis* (ear mite) infestation in cats. *Vet Dermatol* 2016; 27(4):221-35; doi:10.1111/vde.12340

- [44] Korbelik J, Singh A, Rousseau J, Weese JS. Analysis of the otic mycobiota in dogs with otitis externa compared to healthy individuals. *Vet Dermatol* 2018; 29(5):1–10; doi:10.1111/vde.12665
- [45] Tang F-L, Yang H-Q, Ma X-W, Lu D-Z. Epidemiological analysis of ear diseases in 221 dogs in northwest of China. *bioRxiv* 2019; 1–23; doi:10.1101/541516
- [46] Chong L-Y, Head K, Tu N, Burton MJ, Schilder AGM, Brutta MF, et al. Topical antibiotics with steroids for chronic suppurative otitis media. *Cochrane Database Syst Rev* 2018; 6:1–25; doi:10.1002/14651858.CD013054
- [47] King SB, Doucette KP, Seewald W, Forster SL. A randomized, controlled, single-blinded, multicenter evaluation of the efficacy and safety of a once weekly two dose otic gel containing florfenicol, terbinafine and betamethasone administered for the treatment of canine otitis externa. *BMC Vet Res* 2018; 14(307):1–9; doi:10.1186/s12917-018-1627-5
- [48] Bensignor E, Grandemange E. Comparison of an antifungal agent with a mixture of antifungal, antibiotic and corticosteroid agents for the treatment of *Malassezia* species otitis in dogs. *Vet Rec* 2006; 158:193–5; doi:10.1136/vr.158.6.193
- [49] Agnihotri D, Charaya G, Chhabra R, Kumar T, Jain VK. Antibiogram of bacteria isolated from dogs suffering from otitis externa. *Indian J Comp Microbiol Immunol Infect Dis* 2019; 1:15–20; doi:10.5958/0974-0147.2019.00003.5
- [50] Grecu M, Rimbu CM, Tanase OI, Mares M, Nastasa V, Rusu OR. Microbial flora assessment and efficacy of a topical antimicrobial – anti-inflammatory combination in otitis externa therapy in dogs and cats. *Lucrari Stiintifice* 2018; 1:39–50.