

ORIGINAL ARTICLE

Immunolocalization of IL-6 and IL-10 in the testicular tissue of testicular dysfunction rat treated with secretome

Surya Agus Prihatno¹, Yosua Kristian Adi¹, Teguh Budipitojo²

¹Department of Reproduction and Obstetrics, Faculty of Veterinary Medicine, Universitas Gadjah Mada, Yogyakarta, Indonesia

²Department of Anatomy, Faculty of Veterinary Medicine, Universitas Gadjah Mada, Yogyakarta, Indonesia

ABSTRACT

Objective: This study was carried out to find out the immunolocalization of Interleukin 6 (IL-6) and Interleukin 10 (IL-10) in the testicular tissue of testicular dysfunction rat treated with secretome from human umbilical stem cells.

Materials and methods: Rats were induced with cisplatin for testicular dysfunction condition. After that, the rats were grouped into two categories and were treated with secretome at 0.2 and 0.5 ml/kg BW once every week for 4 weeks. One week later, after the secretome treatment, the rats were sacrificed for histological evaluation using the immunohistochemical method. The preparation slides were examined using a light microscope and were analyzed descriptively and quantitatively.

Results: There were no IL-6 and IL-10 immunoreactivities seen in the testicular tissue after cisplatin induction. However, the immunoreactivities of IL-6 and IL-10 were detected after secretome treatment, with both dosages of 0.2 and 0.5 ml/kg BW. These immunoreactivities were detected in the spermatogonia, spermatid/luminal tissue of seminiferous tubule, spermatogenic cells, and Leydig cells. In the cell calculation, the numbers of IL-6 immunoreactive cells were higher at the lower secretome dosage. In contrast, the numbers of IL-10 immunoreactive cells were higher at the higher secretome dosage.

Conclusion: IL-6 and IL-10 can be localized in the testicular tissue of testicular dysfunction rat after secretome treatment.

ARTICLE HISTORY

Received January 13, 2020

Revised May 13, 2020

Accepted June 19, 2020

Published August 22, 2020

KEYWORDS

IL-6; IL-10; immunohistochemistry; secretome; testicular dysfunction rat



This is an Open Access article distributed under the terms of the Creative Commons Attribution 4.0 Licence (<http://creativecommons.org/licenses/by/4.0>)

Introduction

Cell signaling is an important mechanism in the physiological processes across systems. This involves cytokines, hormones, neurotransmitters, growth factors, extracellular matrix components, etc., as messengers [1]. In the testicular tissue, complex cell integration between the spermatogenic cells and interstitial cells of the testicular microenvironment is needed for the spermatogenesis process. These include paracrine, autocrine, and endocrine mechanisms. Cytokines' action is pleiotropic and redundant. The same cytokines can have different effects on different cells and different cytokines can have the same effects on specific cells [2]. IL-6 and IL-10 type of cytokines are involved in the spermatogenesis process, especially as paracrine/autocrine regulators [3,4]. Sertoli cells

and Leydig cells produce these cytokines in response to stimulation by gonadotropins [3,5]. IL-6 is already known to have a specific action for maintaining the function of Sertoli cells and germ cells [6,7]. In contrast, IL-10 acts as an immunoregulator secreted by testicular non-immune cells, Sertoli cells [8]. However, the study about IL-6 and IL-10 in the testicular dysfunction rat treated with secretome has never been published before. Secretome is a mixture of secreted molecules, such as cytokines, growth factors, chemokines, and extracellular vesicles [9–12], produced by mesenchymal stem cells in the medium of cells culture [13]. Secretome has a potential effect on regenerating tissue damage in the degenerative disorder [13,14]. These cytokines in the secretome are essential in influencing many aspects of fertility regulation and reproductive

Correspondence Teguh Budipitojo ✉ budipitojo@ugm.ac.id 📧 Department of Anatomy, Faculty of Veterinary Medicine, Universitas Gadjah Mada, Yogyakarta, Indonesia.

How to cite: Prihatno SA, Adi YK, Budipitojo T. Immunolocalization of IL-6 and IL-10 in the testicular tissue of testicular dysfunction rat treated with secretome. *J Adv Vet Anim Res* 2020; 7(3):514–520.

physiology [15]. In our previous study, we have shown the regeneration of spermatogenesis in the testicular dysfunction rat after treatment with secretome from the human umbilical cord. Spermatogenesis regeneration was proved by increasing the sperm number and motility. Also, there was improvement in the structure of seminiferous tubules [16]. However, the presence of cytokines, especially IL-6 and IL-10, in the regeneration of testicular dysfunction rat treated with secretome has not been studied yet. Evaluation of the presence of IL-6 and IL-10 in the testicular tissue can prove the return of cytokines that are needed during spermatogenesis. This research was carried out to determine the immunolocalization of IL-6 and IL-10 in the tissue of the testicles of testicular dysfunction rat after treatment with secretome from human umbilical stem cells. Immunolocalization was carried out using an immunohistochemical method.

Materials and Methods

Ethical approval

We obtained ethical approval from the Gadjah Mada University Ethics Committee before the research process began. The ethical approval letter number is 00035/04/LPPT/V/2017.

Animals experiment

Eighteen healthy male adult Wistar rats of the same age were used in this research. The rats were adapted in the animal house facility for a week before the experiment began. The rats were maintained with the relatively same temperature and humidity of the tropical region under a controlled 12 h light/dark cycle. Seventeen rats were induced with cisplatin for testicular dysfunction condition, and one rat was not given any treatment as a standard control rat. The induction of testicular dysfunction with cisplatin in the rats was adapted from the method reported by Reddy et al. [17]. One week after the induction, one testicular dysfunction rat and the normal control rat were sacrificed, and the testicular tissues were collected. The remaining rats were grouped into two categories. Group 1 was treated with secretome with the dosage of 0.2 ml/kg BW once every week for 4 weeks, and group 2 was treated with secretome with the dosage of 0.5 ml/kg BW once every week for 4 weeks. Secretome was given intraperitoneally. A week after each secretome treatment, one rat from each group were sacrificed, and the testicular tissues were collected. The testicular tissues were fixed with Bouin's solution immediately after collection.

Tissue processing

Fixed testicular tissues were processed with the paraffin method. The process began with dehydration in a series of

ethanol solutions from 70%, 80%, 90%, absolute I, II, and III for 1 h, respectively. Then, it was continued with clearing in xylene solution I, II, and III for 30 min, respectively. After that, paraffin infiltration was done with incubation in the liquid paraffin 3 times at a temperature of 60°C for 1 h, respectively. Testicular tissue embedding was done in the liquid paraffin. The tissue in the paraffin block was cut to a thickness of 5-micron using a microtome. The cut tissue was moved into the gelatin-coated slide. After that, the slide was placed on the slide warmer for 2 h.

Immunohistochemical staining

The tissue slides were deparaffinized using xylene before rehydration in a series of ethanol solutions. After that, the tissue slides were washed in running water for 5 min. Antigen retrieval was performed using a microwave. The incubation of tissue slides using a blocking endogenous peroxidase solution was performed for 30 min. Rabbit-DAB (Poly-HRP) Detection IHC Kit (Cat. No. IHC0007, FineTest®) was used to visualize the immunoreactivities of antibodies. After washing, using phosphate buffered saline (PBS), the tissue slides were incubated in blocking serum for 1 h. The antibodies were dripped into the tissue slides then were incubated overnight at 4°C. The antibodies used in this experiment were IL-6 Polyclonal Antibody (1:200, Cat. No. bs-0379R, Bioss®) and IL-10 Polyclonal Antibody (1:200, Cat. No. bs-0698R, Bioss®). The next day, after washed using PBS, the tissue slides were incubated using Poly-HRP-Goat Anti-Rabbit IgG for 1 h. Before incubation, using the DAB-Reagent solution for 30 min, the tissue slides were washed again using PBS three times. After that, the tissue slides were washed in running water for at least 5 min before counterstaining using Hematoxylin and coverslip.

Analysis

The preparation slides were examined using a light microscope. The photograph of the preparation slides was taken with a digital camera (Optilab) that was fixed in the light microscope. The immunoreactivities of IL-6 and IL-10 antibodies in the testicular tissue were analyzed descriptively. IL-6 and IL-10 immunoreactive cells were counted from 5 fields of view with 400 magnification.

Results

Immunohistochemical staining

Immunoreactivity of IL-6 and IL-10 antibodies in immunohistochemical staining was shown as a brown color precipitate in the prepared slides. In the normal testicular tissue slides, the immunoreactivity of IL-6 and IL-10 antibodies can be seen in the spermatogonia, spermatid, and Leydig cells (Fig. 1). In the absence of IL-6 and IL-10 antibodies,

there was no brown color precipitate in the prepared slides. These slides were used as negative control staining.

Immunoreactivity of IL-6 Antibody

Immunoreactivities of IL-6 antibody in the testicle tissue slides of the normal control rats were shown dominantly in the spermatogonia (black arrow, Fig. 1A), whereas in the testicular dysfunction rat induced with cisplatin, there was no immunoreactivity in the testicular tissue slides (Fig. 2A). One week after the first secretome treatment with 0.2 ml/kg BW, there were slight immunoreactivities in the luminal tissue of seminiferous tubule (blue arrow, Fig. 2B). These immunoreactivities were still seen after the second secretome treatment (blue arrow, Fig. 2C). After the third secretome treatment, the immunoreactivities were

seen in the spermatogenic cells (black arrow, Fig. 2D). Unfortunately, we could not get the testicular tissue sample after the fourth secretome treatment because there was no rat left. Similar results were obtained in the second treatment group. Although the immunoreactivities have not been seen after the first secretome treatment with 0.5 ml/kg BW (Fig. 2E), the immunoreactivities in the luminal tissue of seminiferous tubule were seen after the second secretome treatment (blue arrow, Fig. 2F). After the third secretome treatment, the immunoreactivities were seen in the luminal tissue (blue arrow, Fig. 2G) and spermatogenic cells (black arrow, Fig. 2G). In the last secretome treatment, the immunoreactivities could be seen in the luminal tissue (blue arrow, Fig. 2H), spermatogenic cells (black arrow, Fig. 2H), and Leydig cells (red arrow, Fig. 2H). IL-6

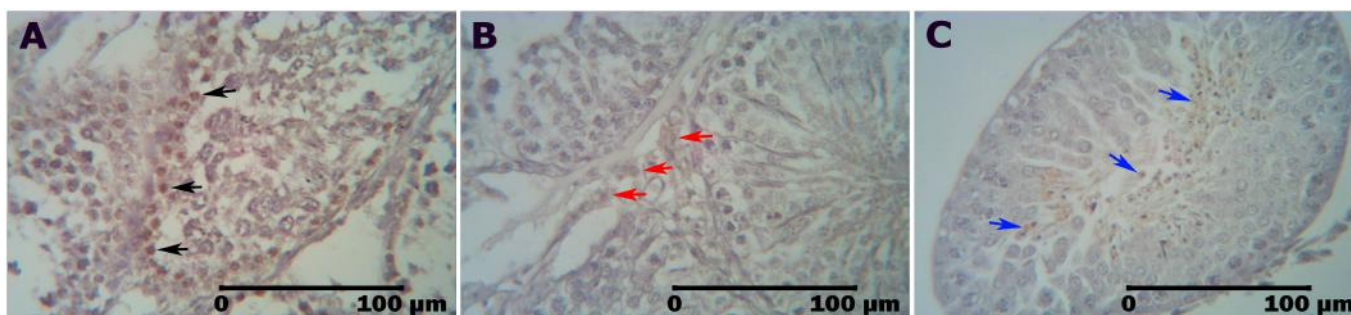


Figure 1. Immunoreactivity of IL-6 and IL-10 in the testicular tissue of a normal rat. Immunoreactivity can be seen as a brown precipitate in the spermatogonia (black arrow, A), Leydig cells (red arrow, B), and spermatid/luminal tissue (blue arrow, C).

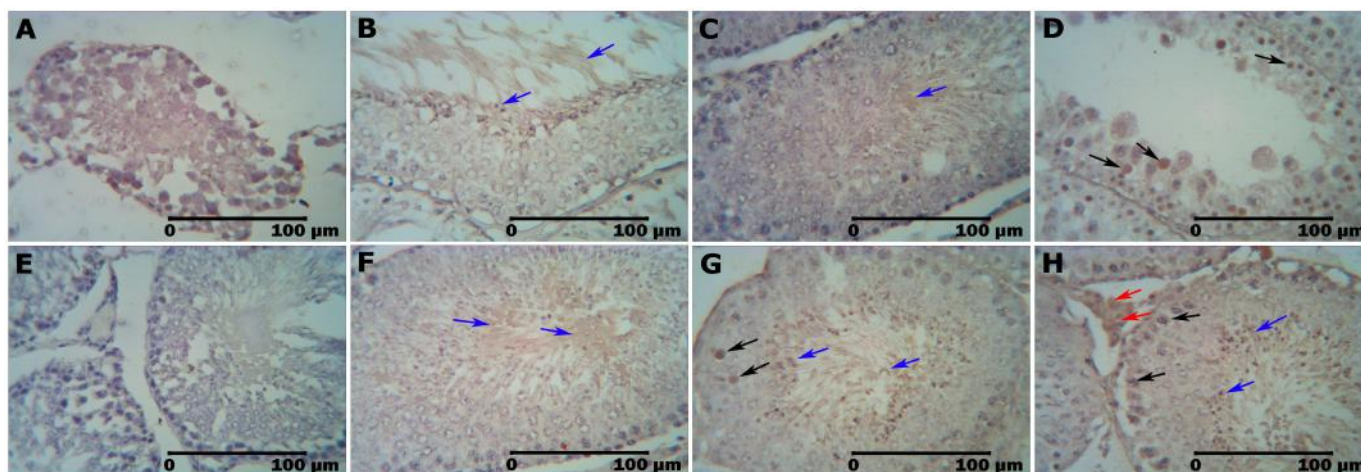


Figure 2. Immunoreactivity of IL-6 in the testicular tissue of the testicular dysfunction rat treated with secretome. Immunoreactivities of IL-6 can be detected in the Leydig cells (red arrow), spermatogenic cells (black arrow), and luminal tissues (blue arrow). Figure 2A shows IHC staining of testicular dysfunction rat; 2B 1 week after the first secretome treatment with 0.2 ml/kg BW; 2C 1 week after the second secretome treatment at the dosage of 0.2 ml/kg BW; 2D 1 week after the third secretome treatment with 0.2 ml/kg BW; 1 week after the second secretome treatment with 0.2 ml/kg BW; 2E 1 week after the first secretome treatment with 0.5 ml/kg BW; 2F 1 week after the second secretome treatment with 0.5 ml/kg BW; 2G 1 week after the third secretome treatment with the dosage of 0.5 ml/kg BW; 2H 1 week after the fourth secretome treatment with 0.5 ml/kg BW.

immunoreactive cells count showed that there were 27 immunoreactive cells after the third secretome treatment with 0.2 mg/kg BW. In the higher dose, there were 7 immunoreactive cells after the third secretome treatment. This number increased after the fourth secretome treatment to 16 immunoreactive cells (Table 1).

Immunoreactivity of IL-10 Antibody

Immunoreactivities of IL-10 antibody in the testicle tissue slides of normal control rats were shown dominantly in the spermatid/luminal tissues of the seminiferous tubule (blue arrow, Fig. 1C) and Leydig cells (red arrow, Fig. 1B), whereas in the testicular dysfunction rat induced with cisplatin, there was no immunoreactivity in the testicular tissue slides. One week after the first (Fig. 3B) and second (Fig. 3C) secretome treatments with 0.2 ml/kg BW, there were no immunoreactivities in the testicular tissues slide. However, the immunoreactivities of spermatogenic cells in the seminiferous tubule could be seen after the third secretome treatment (black arrow, Fig. 3D). Unfortunately, we

could not get the testicular tissue sample after the fourth secretome treatment because there was no rat left. Very dynamic results were shown in the second treatment group. After the first secretome treatment with 0.5 ml/kg BW, the immunoreactivities were seen in the luminal tissue of seminiferous tubule (blue arrow, Fig. 3E). However, there were no immunoreactivities seen after the second secretome treatment (Fig. 3F). The immunoreactivities reappeared dominantly in the spermatogonia after the third secretome treatment (black arrow, Fig. 3G) and disappeared again after the fourth secretome treatment (Fig. 3H). IL-10 immunoreactive cells count showed that there were 7 immunoreactive cells after the third secretome treatment with 0.2 mg/kg BW. In the higher dose, there were 27 immunoreactive cells after the third secretome treatment (Table 2).

Discussion

Cytokines in the testicular tissue are strictly controlled to protect and ensure spermatozoa production. In normal

Table 1. The number IL-6 immunoreactive cells in the testicular tissue of the testicular dysfunction rat treated with secretome.

Dosage	One week after 1st secretome treatment	One week after 2nd secretome treatment	One week after 3rd secretome treatment	One week after 4th secretome treatment
0.2 mg/kg BW	0	0	27	N/A
0.5 mg/kg BW	0	0	7	16

N/A = not available data.

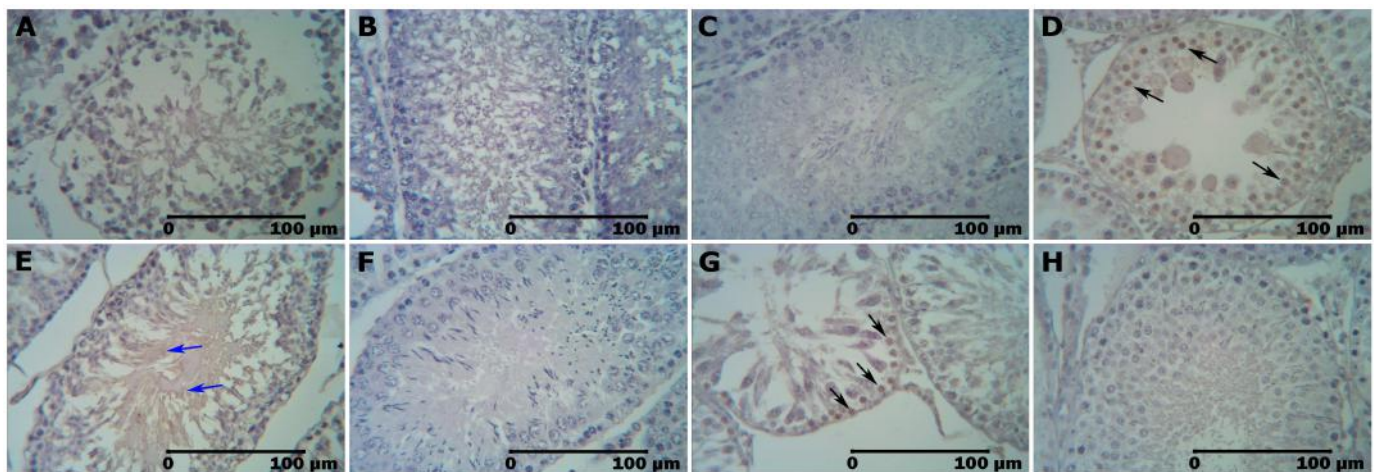


Figure 3. Immunoreactivity of IL-10 in the testicular tissue of the testicular dysfunction rat treated with secretome. Immunoreactivities of IL-10 can be detected in the spermatogenic cells (black arrow) and luminal tissues (blue arrow). Figure 2A shows IHC staining of the testicular dysfunction rat; 2B 1 week after the first secretome treatment with 0.2 ml/kg BW; 2C 1 week after the second secretome treatment with 0.2 ml/kg BW; 2D 1 week after the third secretome treatment with 0.2 ml/kg BW; 1 week after the second secretome treatment with 0.2 ml/kg BW; 2E 1 week after the first secretome treatment with the dosage of 0.5 ml/kg BW; 2F 1 week after the second secretome treatment with 0.5 ml/kg BW; 2G 1 week after the third secretome treatment with 0.5 ml/kg BW; 2H 1 week after the fourth secretome treatment with 0.5 ml/kg BW.

Table 2. The number IL-10 immunoreactive cells in the testicular tissue of testicular dysfunction rat treated with secretome.

Dosage	One week after 1st secretome treatment	One week after 2nd secretome treatment	One week after 3rd secretome treatment	One week after 4th secretome treatment
0.2 mg/kg BW	0	0	7	N/A
0.5 mg/kg BW	0	0	27	0

N/A = not available data.

testicular tissue, cytokines are secreted by non-immune cells. Pro-inflammatory and immunoregulatory cytokines, in this case, like IL-6 and IL-10, were secreted under normal conditions and in response to inflammatory stimuli by testicular somatic and spermatogenic cells. These types of cytokines give signals through cell surface receptors [18]. IL-6 can be generated by Sertoli and Leydig cells to modulate Sertoli cells itself and the development of spermatogenic cells [19]. In pathological condition, such as seminomas/testicular cancer, IL-6 production was significantly increased [20]. The other report explained that IL-6 was a cell growth-stimulating factor in organs/disease [21].

In contrast to IL-6, IL-10 level remained similar to the normal level in seminomas/testicular cancer. This suggests that IL-10 has immunosuppressive properties [22]. Rival et al. [23] reported that the immunoreactivity of IL-6 could be localized in the Leydig cells, Sertoli cells, and macrophage, while IL-6 receptor immunoreactivity was localized in the Leydig cells, macrophage, and germ cells. The IL-6 level in humans increased in several conditions, such as genital infection [24] and infertile with varicoceles [25]. Jiang et al. [26] reported that there was a different concentration of IL-6 in control, abnormal semen with high Reactive Oxygen Species (ROS) levels, and normal semen with elevated ROS levels.

However, in this study, there was no IL-6 immunoreactivity detected in the testicular tissue of the testicular dysfunction rat induced with cisplatin. We assumed that cisplatin has a direct effect on IL-6-producing cells or IL-6-targeted cells. After secretome treatment, with both 0.2 and 0.5 ml/kg BW, IL-6 was found in the luminal tissue of seminiferous tubule and proved by IL-6 immunoreactivity. Further secretome treatment showed a good effect, which proved the presence of IL-6 immunoreactivity in spermatogenic cells. Gan reported that IL-6 signaling has essential roles in the restructuring of the testicular cell junction [27]. This structure is also essential for supporting spermatogenesis [28].

Furthermore, IL-10 was produced by a resident of mast cells and macrophages in the testicular tissue, as well as non-immune somatic cells, like Sertoli cells [29,30]. In the testicular tissue, macrophages produced IL-10 to regulate the reaction of the humoral immune and the response of cellular immune [31,32] through its immunosuppressive

properties [22]. In our study, we detected IL-10 immunoreactivity dominantly in the spermatid and luminal tissue of the seminiferous tubule. We assumed that a high concentration of IL-10 in the luminal tissue correlates with immune function. Corticosterone, testosterone, and PGE2 are known to induce the secretion of IL-10 [33]. In the testicular tissue of the testicular dysfunction rat induced with cisplatin, there was no IL-10 immunoreactivity. After the third secretome treatment with 0.2 ml/kg BW, there were very few IL-10 immunoreactivities detected in the spermatogenic cells. However, in the secretome treatment with 0.5 ml/kg BW, there was some inconsistency of the presence of IL-10 in the testicular tissue. IL-10 immunoreactivity was detected in the luminal tissue of the seminiferous tubule after the first secretome treatment, but lacked after second secretome treatment. IL-10 immunoreactivity reappeared in the spermatogonia after the third secretome treatment, but was not detected again after the fourth secretome treatment. This unclear dynamic of IL-10 immunoreactivity probably is caused by short-acting and short-lived cytokines [18]. However, the presence of IL-10 indicated the return of immunoregulation in the testicular tissue. The control of the immune environment in the testicular tissue is essential to maintain immune homeostasis that is necessary for normal spermatogenesis [34].

Conclusion

IL-6 and IL-10 immunoreactivities can be detected in the testicular tissue of the testicular dysfunction rat after treatment with secretome from the human umbilical cord. We believed that the presence of IL-6 and IL-10 after treatment with secretome from the human umbilical cord correlated with the returning cell signaling mechanism and immunoregulation in the testicular tissue of the testicular dysfunction rat. However, the mechanism needs to be studied furthermore.

Acknowledgments

The authors thank the Directorate General of Higher Education, Ministry of Research, Technology, and Higher Education, for providing full funding to this study (Grant number: 160/UN1/DITLIT/DIT-LIT/LT/2017).

Conflict of interest

The authors declare that there was no conflict of interest.

Authors' contribution

TB designed the study, interpreted the results, and arrange the publication draft. SAP and YKA were involved in the collection of data and contributed to paper preparation. TB, SAP, and YKA took part in preparing and critically checking this manuscript.

References

- [1] Nair A, Chauhan P, Saha B, Kubatzky KF. Conceptual evolution of cell signaling. *Int J Mol Sci* 2019; 20(13):3292; <https://doi.org/10.3390/ijms20133292>
- [2] Zhang JM, An J. Cytokines, inflammation and pain. *Int Anesthesiol Clin* 2007; 45(2):27–37; <https://doi.org/10.1097/AIA.0b013e318034194e>
- [3] Huleihel M, Lunenfeld E. Regulation of spermatogenesis by paracrine/autocrine testicular factors. *Asian J Androl* 2004; 6(3):259–68; <http://www.asiaandro.com/archive/1008-682X/6/259.htm>
- [4] Syriou V, Papanikolaou D, Kozyraki A, Goulis DG. Cytokines and male infertility. *Eur Cytokine Netw* 2018; 29(3):73–82; <https://doi.org/10.1684/ecn.2018.0412>
- [5] Hedger MP. Testicular leukocytes: what are they doing? *Rev Reprod* 1997; 2:38–47; <https://doi.org/10.1530/revreprod/2.1.38>
- [6] Zhang H, Yin Y, Wang G, Liu Z, Liu L, Sun F. Interleukin-6 disrupts blood-testis barrier through inhibiting protein degradation or activating phosphorylated ERK in Sertoli cells. *Sci Rep* 2014; 4:4260; <https://doi.org/10.1038/srep04260>
- [7] Lampiao F, du Plessis SS. TNF-alpha and IL-6 affect human sperm function by elevating nitric oxide production. *Reprod Biomed Online* 2008; 17(5):628–31; [https://doi.org/10.1016/S1472-6483\(10\)60309-4](https://doi.org/10.1016/S1472-6483(10)60309-4)
- [8] Cecilia VP, María ST, Patricia VJ, Sabrina JD, Vanesa AG, Livia L. Dual role of immune cells in the testis. *Spermatogenesis* 2013; 3:1, e23870; <https://doi.org/10.4161/spmg.23870>
- [9] Schinköthe T, Bloch W, Schmidt A. In vitro secreting profile of human mesenchymal stem cells. *Stem Cells Dev* 2008; 17:199–206; <https://doi.org/10.1089/scd.2007.0175>
- [10] Park CW, Kim KS, Bae S, Son HK, Myung PK, Hong HJ, et al. Cytokine secretion profiling of human mesenchymal stem cells by antibody array. *Int J Stem Cells* 2009; 2:59–68; <https://doi.org/10.15283/ijsc.2009.2.1.59>
- [11] Nakano N, Nakai Y, Seo TB, Yamada Y, Ohno T, Yamanaka A, et al. Characterization of conditioned medium of cultured bone marrow stromal cells. *Neurosci Lett* 2010; 483:57–61; <https://doi.org/10.1016/j.neulet.2010.07.062>
- [12] Kupcova SH. Proteomic techniques for characterisation of mesenchymal stem cell secretome. *Biochimie* 2013; 95:2196–211; <https://doi.org/10.1016/j.biochi.2013.07.015>
- [13] Cunningham CJ, Redondo-Castro E, Allan SM. The therapeutic potential of the mesenchymal stem cell secretome in ischaemic stroke. *J Cereb Blood Flow Metab* 2018; 38(8):1276–92; <https://doi.org/10.1177/0271678X18776802>
- [14] Pawitan JA. Prospect of stem cell conditioned medium in regenerative medicine. *Biomed Res Int* 2014; 2014:1–14; <https://doi.org/10.1155/2014/965849>
- [15] Havrylyuk A, Chopyak V, Boyko Y, Kril I, Kurpisz M. Cytokines in the blood and semen of infertile patients. *Cent Eur J Immunol* 2015; 40(3):337–44; <https://doi.org/10.5114/ceji.2015.54596>
- [16] Prihatno SA, Padeta I, Larasati AD, Sundari B, Hidayati A, Fibrianto YH, et al. Effects of secretome on cisplatin-induced testicular dysfunction in rats. *Vet World* 2018; 11(9):1349–56; <https://doi.org/10.14202/vetworld.2018.1349-1356>
- [17] Reddy YVK, Reddy PS, Shivalingam MR. Cisplatin or carboplatin caused suppression in antioxidant enzyme defense system in liver, kidney and testis of male albino rats. *J Biomed Sci Res* 2010; 2(1):23–8; <http://jbsr.pharmainfo.in/documents/vol2issue1/2010020104.pdf>
- [18] Loveland KL, Klein B, Pueschl D, Indumathy S, Bergmann M, Loveland BE, et al. Cytokines in male fertility and reproductive pathologies: immunoregulation and beyond. *Front Endocrinol* 2017; 8:307; <https://doi.org/10.3389/fendo.2017.00307>
- [19] Hedger MP, Meinhardt A. Cytokines and the immune-testicular axis. *J Reprod Immunol* 2003; 58:1–26; [https://doi.org/10.1016/S0165-0378\(02\)00060-8](https://doi.org/10.1016/S0165-0378(02)00060-8)
- [20] Bialas M, Fiszer D, Rozwadowska N, Kosicki W, Jedrzejczak P, Kurpisz M. The role of IL-6, IL-10, TNF-alpha and its receptors TNFR1 and TNFR2 in the local regulatory system of normal and impaired human spermatogenesis. *Am J Reprod Immunol* 2009; 62(1):51–9; <https://doi.org/10.1111/j.1600-0897.2009.00711.x>
- [21] Cai Q, Huang H, Bai B, Lin S, Gao Y, Xia Y, et al. IL-6 promotes cell proliferation and antiapoptosis through activation of the JAK/STAT3 pathway in patients with NK/T – cell lymphoma and correlates with poor treatment outcome. *Blood* 2013; 122:1758; <https://doi.org/10.1182/blood.V122.21.1758.1758>
- [22] Mittal SK, Roche PA. Suppression of antigen presentation by IL-10. *Curr Opin Immunol* 2015; 34:22–7; <https://doi.org/10.1016/j.coi.2014.12.009>
- [23] Rival C, Theas MS, Guazzone VA, Lustig L. Interleukin-6 and IL-6 receptor cell expression in testis of rats with autoimmune orchitis. *J Reprod Immunol* 2006; 70(1–2):43–58; <https://doi.org/10.1016/j.jri.2005.10.006>
- [24] Martinez-Prado E, Camejo Bermudez MI. Expression of IL-6, IL-8, TNF-alpha, IL-10, HSP-60, anti-HSP-60 antibodies, and anti-sperm antibodies, in semen of men with leukocytes and/or bacteria. *Am J Reprod Immunol* 2010; 63(3):233–43; <https://doi.org/10.1111/j.1600-0897.2009.00786.x>
- [25] Tremellen K. Oxidative stress and male infertility—a clinical perspective. *Hum Reprod Update* 2008; 14(3):243–58; <https://doi.org/10.1093/humupd/dmn004>
- [26] Jiang L, Zheng T, Huang J, Mo J, Zhou H, Liu M, et al. Association of semen cytokines with reactive oxygen species and histone transition abnormalities. *J Assist Reprod Genet* 2016; 33:1239–46; <https://doi.org/10.1007/s10815-016-0756-7>
- [27] Gan RY. Regulation and functions of interleukin-6 in the mammalian testis. *Int J Modern Biol Med* 2014; 5(2):81–90; <http://www.modernscientificpress.com/journals/ViewArticle.aspx?oNi57ml-9FIF90KRLCcg8EZvdZVyFh8ZVICjguBmBrLaPds89za63JAUjrN-blyshg>
- [28] Nguyen TMX, Vegrichtova M, Tlapakova T, Krulova M, Krylov V. The interconnection between cytokeratin and cell membrane-bound β -catenin in Sertoli cells derived from juvenile *Xenopus tropicalis* testes. *Biol Open* 2019; 8:bio043950; <https://doi.org/10.1242/bio.043950>
- [29] O'Bryan MK, Gerdprasert O, Nikolic-Paterson DJ, Meinhardt A, Muir JA, Foulds LM, et al. Cytokine profiles in the testes of rats treated with lipo-polysaccharide reveal localized suppression of inflammatory responses. *Am J Physiol Regul Integr Comp Physiol* 2005; 288(6):R1744–55; <https://doi.org/10.1152/ajpregu.00651.2004>
- [30] Rival C, Lustig L, Iosub R, Guazzone VA, Schneider E, Meinhardt A, et al. Identification of a dendritic cell population in normal testis and in chronically inflamed testis of rats with autoimmune orchitis. *Cell Tissue Res* 2006; 324(2):311–8; <https://doi.org/10.1007/s00441-005-0129-5>

- [31] Bryniarski K, Szczepanik M, Maresz K, Ptak M, Ptak W. Subpopulations of mouse testicular macrophages and their immunoregulatory function. *Am J Reprod Immunol* 2004; 52:27–35; <https://doi.org/10.1111/j.1600-0897.2004.00178.x>
- [32] Winnall WR, Muir JA, Hedger MP. Rat resident testicular macrophages have an alternatively activated phenotype and constitutively produce interleukin-10 in vitro. *J Leukoc Biol* 2011; 90:133–43; <https://doi.org/10.1189/jlb.1010557>
- [33] Wang M, Fijak M, Hossain H, Markmann M, Nusing RM, Lochnit G, et al. Characterization of the micro-environment of the testis that shapes the phenotype and function of testicular macrophages. *J Immunol* 2017; 198:4327–40; <https://doi.org/10.4049/jimmunol.1700162>
- [34] Qu N, Itoh M, Sakabe K. Effects of chemotherapy and radiotherapy on spermatogenesis: the role of testicular immunology. *Int J Mol Sci* 2019; 20:957; <https://doi.org/10.3390/ijms20040957>