

ORIGINAL ARTICLE

## Differential efficacies of marigold leaves and turmeric paste on the healing of the incised wound in sheep

Md. Tuhinur Rahman<sup>1,2</sup>, Moinul Hasan<sup>1</sup>, Muhammad Tofazzal Hossain<sup>3</sup>, Md. Sayedul Islam<sup>3,4</sup>, Md. Aatur Rahman<sup>2</sup>, Md. Rafiqul Alam<sup>1</sup>, Nasrin Sultana Juyena<sup>1</sup>

<sup>1</sup>Department of Surgery and Obstetrics, Bangladesh Agricultural University, Mymensingh-2202, Bangladesh

<sup>2</sup>Department of Surgery and Radiology, Bangabandhu Sheikh Mujibur Rahman Agricultural University, Gazipur, Bangladesh

<sup>3</sup>Department of Microbiology and Hygiene, Bangladesh Agricultural University, Mymensingh-2202, Bangladesh

<sup>4</sup>Department of Microbiology and Public Health, Bangabandhu Sheikh Mujibur Rahman Agricultural University, Gazipur, Bangladesh

### ABSTRACT

**Objective:** This study was undertaken to compare the curative efficacy of marigold leaf paste and turmeric paste on healing the incised wound in sheep. The study also determined the antimicrobial effects and histopathological changes in a wound's healing process treated with these medicinal herbs.

**Materials and Methods:** Surgical wounds ( $n = 18$ ) were created aseptically in the skin of the flank region of six healthy sheep dividing them into three experimental groups. Follow-up data were taken up to day 21. Different morphological characteristics of the wound and wound contraction (length and width) were recorded weekly. Samples were collected on days 1, 2, and 3 to test the antimicrobial effects and on days 1, 3, and 7 for histopathological studies.

**Results:** Treatment with marigold leaf paste and turmeric paste resulted in a swelled wound area of  $11.78 \pm 0.38$  mm and  $11.52 \pm 0.27$  mm, respectively. The wound areas were comparatively lower than that of the control group ( $11.44 \pm 0.20$  mm). Moreover, the least elevation ( $2.44 \pm 0.12$  mm) of the sutured line from the skin surface was noted and compared between the marigold leaf paste and normal saline ( $2.74 \pm 0.13$  mm). Bacterial colonies in the nutrient agar medium cultured with swabs from the normal saline-treated group's wound area were found on day 1. On the contrary, bacterial colonies were absent on days 2 and 3 of treatment in the groups treated with both the paste of marigold leaves and turmeric. Less intense tissue reactions and higher keratinization of epithelium were shown in the group treated with marigold leaf paste than turmeric paste and saline-treated groups.

**Conclusion:** Marigold leaf paste showed less tissue reaction and healed the wounds effectively. Thus, this paste could be used for the treatment of superficial wounds in sheep.

### ARTICLE HISTORY

Received July 12, 2020

Revised November 15, 2020

Accepted November 15, 2020

Published December 05, 2020

### KEYWORDS

Histopathological study;  
Microbiological culture;  
Wound healing



This is an Open Access article distributed under the terms of the Creative Commons Attribution 4.0 Licence (<http://creativecommons.org/licenses/by/4.0>)

### Introduction

The interruption of regular anatomical arrangements and tissue function is defined as a wound and can be differentiated by its etiology, duration, or location. Wound healing involves a chain of well-organized cellular and biochemical events regarding the development and regeneration of tissues in a definite fashion, including blood clotting, inflammation, tissue regeneration, epithelialization, collagen synthesis, and wounded tissue remodeling [1]. Different

serious consequences may occur if the wound is not treated duly. The complications of wound healing in Bangladesh commonly occur due to lack of modern treatment facilities, high cost of medicines, and the management of wounds by unauthorized persons [2].

Wound healing is suppressed by different immunosuppressive agents, cytotoxins, and non-steroidal anti-inflammatory drugs. Antibiotics, herbal drugs, and analgesics expedited wound healing [3]. Despite trade drugs being

**Correspondence** Nasrin Sultana Juyena ✉ [nsjuyena@bau.edu.bd](mailto:nsjuyena@bau.edu.bd) 📧 Department of Surgery and Obstetrics, Bangladesh Agricultural University, Mymensingh, Bangladesh.

**How to cite:** Rahman MT, Hasan M, Hossain MT, Islam MS, Rahman MA, Alam MR, Juyena NS. Differential efficacies of marigold leaves and turmeric paste on the healing of the incised wound in sheep. *J Adv Vet Anim Res* 2020; 7(4):750–757.

used instead of medicinal plants, people still use medicinal herbs for primary healthcare worldwide [4–7]. Tribes in India use many plants and their extracts for cuts, wounds, and burn treatment [8]. In current years, the antimicrobial activities of plants and their extracts have been documented [9]. *Calendula officinalis*, a herb known as marigold, has exceptional healing powers, and it is fantastic in the treatment of wounds. Marigold is beneficial as an antiseptic and an excellent remedy for wound treatment [10]. According to Ayurvedic and Unani medicine, the flowers and leaves of marigold have anti-inflammatory, antipyretic, antimicrobial, and antiepileptic effects [11].

Marigolds are generally administered in tinctures, ointments, and infusions to treat wounds for inflammation of the skin and mucous membranes [12]. Polysaccharides having (1→3)-linked  $\beta$ -D-galactan are isolated from aqueous marigold extract, which stimulates phagocytosis of granulocytes in humans [13]. Curcumin, the main active component of *Curcuma longa* (Turmeric), has also been studied for an extended period. Turmeric has many bio-functional properties, such as antioxidants, free radical scavengers, antimicrobial, and anti-inflammatory actions, that are responsible for the healing process [14]. The main ingredients of the turmeric essential oil identified were  $\beta$ -sesquiphellandrene (38.69%),  $\alpha$ -curcumene (18.44%), and *p*-mentha-1,4 (8)-diene (16.29%). Hassan et al. [15] reported that the extract of turmeric showed the utmost Mg (49.4 mg/l) concentration after Ca (35.42 mg/l) and Fe (1.27 mg/l).

Paul et al. [3] used marigold flower and turmeric root in the goat's wound healing. They studied some physical parameters and histological appearances of the wound, but they did not test these herbs for antimicrobial activities. Moreover, marigold leaves might be more available than flowers in terms of quantity year-round. Miah et al. [16] used turmeric in the wound healing of black Bengal goat and carried out antimicrobial tests and histological and morphological parameters. However, they did not compare the efficacy of turmeric with other herbal plants. No such comparative study of the herbal plants on wound healing of sheep was carried out in Bangladesh. In this study, we tested the relative efficacy of marigold and turmeric to recover surgical wounds. We also justified the antimicrobial activities and observed histopathological changes of wounds treated with marigold leaves paste and turmeric paste.

## Materials and Methods

### Ethical approval

This study was conducted ensuring the guidelines and approval from the Animal Experimentation Ethics Committee (AEEC), Department of Surgery and

Obstetrics, Bangladesh Agricultural University (BAU), Mymensingh-2202, Bangladesh (Approval number: 03/2017/AEEC).

### Study period and population

This experiment was carried out on indigenous sheep to determine the effect of marigold leaves paste on wound healing. The study was conducted at the Research Animal Farm of the Department of Surgery and Obstetrics, BAU, from July 2017 to December 2017. Six sheep with normal signs of health were selected for the experiment. The bodyweight of the sheep varied between 11.5 and 14 kg. The study animals were nourished in conventional housing systems with routine veterinary supervision. Adequate food and water were given *ad libitum*. Before the experiment, the sheep were kept in quarantine for 14 days. Anthelmintic at 25 mg/kg body weight (Renadex®, Renata pharmaceuticals, Bangladesh Ltd.) was given. The animals were vaccinated with the peste des petits ruminant (PPR) vaccine (PPR Vaccine®, Livestock Research Institute, Bangladesh) for immunization against PPR1 disease.

### The assortment of agents and drug formulation

Fresh turmeric root and marigold leaves were collected locally, of good quality in size, shape, and color. After washing, the turmeric was skinned and cleaned frequently with fresh water. Turmeric was sliced and dried overnight in a hot air oven. Dry slices of turmeric were powdered manually, and the powder was then preserved in an airtight container. The marigold leaves were cleaned with fresh water and cut into small pieces. Then, it was made into a paste with the help of a mortar and pestle.

A 10% solution of povidone-iodine (Povisep®, Jayson pharmaceuticals, Bangladesh) was used to prepare the operation site. 2% lidocaine hydrochloride (Jasocaine A®, Jayson pharmaceuticals, Bangladesh) was used as local anesthetics. Making of an aseptic wound, suturing the wound edges, drug formulation and application, sample collection and preservation, and regular wound observation were carried out at the Research Animal Farm, Department of Surgery and Obstetrics, and BAU. A microbiological study was conducted at the Department of Microbiology and Hygiene, BAU. Histological slides were prepared and observed at the Department of Pathobiology and Central Laboratory, Faculty of Veterinary Medicine and Animal Sciences (FVMAS), Bangabandhu Sheikh Mujibur Rahman Agricultural University (BSMRAU), Gazipur-1706, respectively.

### Design of experiment

Six healthy sheep were collected for this study and separated into three equal groups, and each group confined

two sheep with three wounds in each. By ensuring the animal's presurgical preparations, three wounds (incised) in each sheep were produced aseptically through a vertical incision in the flank region's skin. The incised wounds were approximately 2.5 cm long and 1.0 cm deep. A horizontal mattress suture (8-mm apart) with silk (black braided non-absorbable suture material waxed silk, U.S.P 2-0; Japan) was used for wound closure. The average distance between suture bites and the border of wound edges was 5 mm. No antibiotic, anti-inflammatory, and antihistaminic drugs were applied for the healing of the wounds. The fresh marigold leaves paste and turmeric paste (turmeric powder:distilled water = 1:1) were prepared daily just before application. Six incised wounds were treated with marigold leaves paste locally for 7 days. Another six wounds were treated with turmeric paste in the same way. The remaining six wounds were treated with 0.9% normal saline (NS®, The Acme Laboratories Ltd., Bangladesh) for 7 days and considered as a control. After 7 days of treatment, sutures were removed and maintained carefully to avoid the formation of granulation tissues.

#### **Observation of wounds**

Routine follow-up data were documented up to day 21 (D<sub>21</sub>). Various morphological wound factors, such as swelling area (mm), the width of the sutured area (mm), the elevation of suture line (mm), and the wound contraction per week (mm), were measured using slide calipers. The swelling area of the wound was measured for up to 3 days. The sutures were removed after 7 days, and elevation of the suture line was noted. The width of the suture area was recorded on days 0 (D<sub>0</sub>), 3 (D<sub>3</sub>), 7 (D<sub>7</sub>), 14 (D<sub>14</sub>), and 21 (D<sub>21</sub>) to determine the status of healing. All wounds were supervised daily to note any complications, such as hemorrhage, unusual swelling, wound dehiscence, stitch abscess, exudation, putrefaction, and infection.

#### **Bacteriological study**

Sterile cotton buds were used to collect samples aseptically from the experimental wounds. Then, samples were transferred into the nutrient broth in screw-capped test tubes. Samples from wounds were incubated for 12 h in nutrient broth at 37°C. After that, the samples were inoculated in the specific agar according to the streak plate method. Then, the inoculated samples were incubated overnight to grow bacterial colonies at 37°C [17]. Gram stain protocol was conducted to know the staining and morphological characteristics of specific bacteria [18].

#### **Biopsy and histopathology**

The biopsy samples (15 × 10 mm) were collected on days 1 (D<sub>1</sub>), 3 (D<sub>3</sub>), and 7 (D<sub>7</sub>) from the wounds of each

group. For histopathology, 10% buffered neutral formalin solution was used to fix the dermis and epidermis tissues. Preparation of histopathological slides was carried out according to the method of Luna [19]. The whole procedure was conducted at the Pathology Laboratory of the Department of Pathobiology, FVMAS, BSMRAU, Gazipur-1706. The stained slides were examined at a 4x objective view under an inverted microscope (Primovert®, Compact inverted microscope, Germany) in the Central Laboratory of FVMAS, BSMRAU, Gazipur-1706, to identify reactive cells, debris, clots, and keratin layer among the test and control groups.

#### **Statistical analysis**

Data were shown as Mean ± SEM. The *t*-test was carried out to compare data among the groups. The data analysis was carried out in R-software (version 3.3.6). The value of probability, *p* < 0.05, was regarded as statistically significant.

#### **Results**

Eighteen incised wounds were classified into three groups, which consisted of six wounds in each group. The first two groups were treated with marigold leaf paste and turmeric root paste to evaluate their healing effects. Another six wounds were treated with normal saline and were considered as control. Morphological, microbiological, and histopathological changes were studied to assess and compare the groups' healing efficiency.

#### **Morphological changes**

In this study, parameters such as swollen area (mm), the altitude of suture line (mm), wound contraction, and girth of sutured area (mm) of wounds were estimated. The swelling was detected up to D<sub>3</sub> post-operation in all groups. The more swollen area (11.78 ± 0.38 mm) in the wounds was seen in the case of the control group treated with normal saline solution. Marigold leaf paste and turmeric paste-treated groups resulted in swollen areas of 11.44 ± 0.20 mm and 11.52 ± 0.27 mm, respectively, which were lesser than the control. However, the differences in swelled areas of wounds among the groups differed insignificantly.

The external sutures were detached on the D<sub>7</sub> post-operation, and suture lines' altitudes were recorded. The height of suture lines in marigold leaf paste and turmeric paste-treated groups was 2.44 ± 0.12 mm and 2.74 ± 0.13 mm, respectively, which were remarkably lower than the control (3.68 ± 0.14 mm) (Table 1). Therefore, the presence of a significantly lower elevation of the suture line and the less swollen area indicates better anti-inflammatory effects in the wounds of the marigold leaves paste and turmeric paste-treated groups than that of the control group.

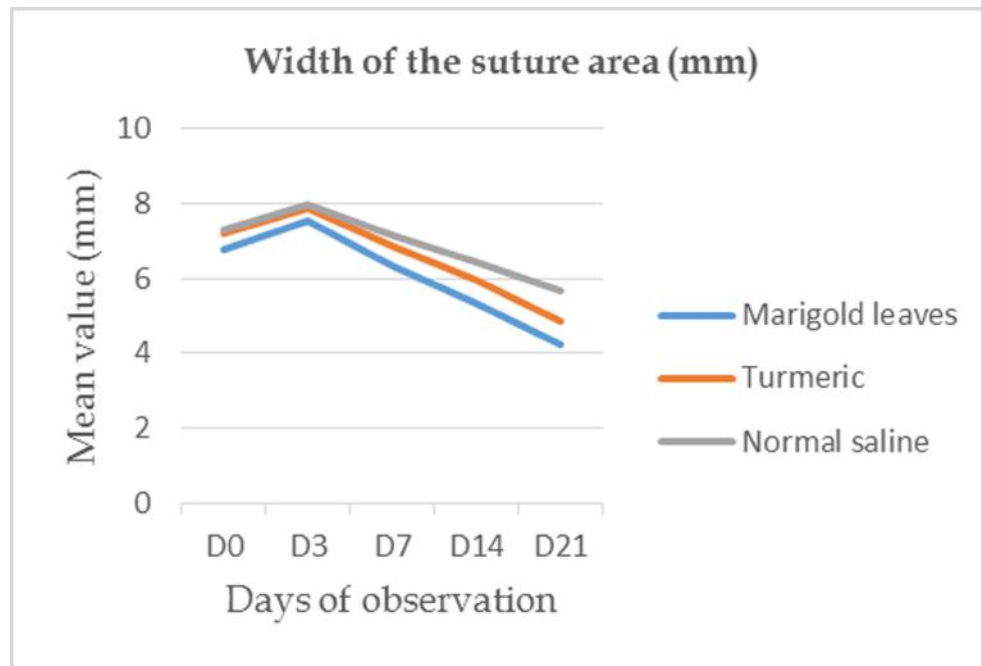
**Table 1.** Various parameters related to the morphology of wounds in marigold leaf extract, turmeric paste, and normal saline-treated groups (Mean  $\pm$  SEM).

Morphological Parameters	Marigold leaf paste group	Turmeric paste group	Normal saline group	Significance
Swelling of the suture area ( $D_0$ - $D_3$ )	11.44 $\pm$ 0.20	11.52 $\pm$ 0.27	11.78 $\pm$ 0.38	NS
Elevation of the suture line ( $D_0$ - $D_7$ )	2.44 $\pm$ 0.12 <sup>b</sup>	2.74 $\pm$ 0.13 <sup>b</sup>	3.68 $\pm$ 0.14 <sup>a</sup>	***
Average contraction length (mm/week)	1.49 $\pm$ 0.08 <sup>b</sup>	1.69 $\pm$ 0.07 <sup>ab</sup>	1.84 $\pm$ 0.14 <sup>a</sup>	NS

Values of a and b differ significantly among groups in the same row.

NS = non-significant.

\*\*\* $p < 0.001$



**Figure 1.** The breadth of the sutured area from day 0 ( $D_0$ ) up to day 14 ( $D_{14}$ ) in all groups.

Wound contraction length per week was measured as another physical characteristic, and it was inferior in the marigold leaf paste-treated group than in the other two groups (Table 1). After the operation, from  $D_0$  up to  $D_{21}$ , the width of the suture area of the wounds was recorded to realize the contraction of the healing process (Fig. 1). The width of the suture area of the wounds of all the groups was amplified up to  $D_3$ . After  $D_3$ , it diminished steadily in all the groups (Table 2). The results of observations on  $D_7$  and  $D_{14}$  demonstrated that wounds treated with marigold leaf paste resulted significantly ( $p \leq 0.05$ ) in a lesser width of the suture area than the control.

On the other hand, wounds treated with turmeric paste did not indicate a significant variation at all with the other groups. However, the results of observations on  $D_{21}$  demonstrated that wounds treated with marigold leaf paste resulted significantly ( $p \leq 0.001$ ) in a lesser width of

the suture area than the other two groups. The morphological parameters' findings confirmed the complete healing of wounds treated with both the marigold leaves paste and turmeric paste within 21 days of treatment. On the contrary, there were some postoperative complications such as excessive swelling, exudation with a foul odor, and stitch abscess in the control group treated with normal saline until  $D_{21}$  and later.

#### Bacteriological observation

The swab sample was collected following the usual procedure on  $D_1$ - $D_3$  postoperative days for bacteriological study. On  $D_1$ , bacterial colonies were seen in the culture media of all the samples. However, in the culture media of both marigold leaf and turmeric paste wounds' samples, bacterial colonies were absent on  $D_2$  and  $D_3$  for bacteriological study. On the contrary, bacterial colonies were present in



**Table 2.** Swelling area (mm) of wounds in marigold leaf extract, turmeric paste, and normal saline-treated groups (Mean  $\pm$  SEM).

Days of Observation	Swelling area of wound in mm			Significance
	Marigold leaf paste group	Turmeric paste group	Normal saline group	
D <sub>0</sub>	6.79 $\pm$ 0.24	7.19 $\pm$ 0.24	7.3 $\pm$ 0.20	NS
D <sub>3</sub>	7.56 $\pm$ 0.23	7.88 $\pm$ 0.27	7.99 $\pm$ 0.24	NS
D <sub>7</sub>	6.35 $\pm$ 0.19 <sup>b</sup>	6.85 $\pm$ 0.18 <sup>ab</sup>	7.16 $\pm$ 0.20 <sup>a</sup>	*
D <sub>14</sub>	5.33 $\pm$ 0.27 <sup>b</sup>	5.95 $\pm$ 0.32 <sup>ab</sup>	6.46 $\pm$ 0.27 <sup>a</sup>	*
D <sub>21</sub>	4.24 $\pm$ 0.14 <sup>c</sup>	4.83 $\pm$ 0.11 <sup>b</sup>	5.66 $\pm$ 0.25 <sup>a</sup>	***

Values of a, b, and c differ significantly among groups in the same row.

NS = non-significant.

\* $p < 0.05$ ; \*\*\* $p < 0.001$ .

the samples' culture media collected from wounds treated with normal saline on D<sub>2</sub> and D<sub>3</sub>. Gram stain technique was used to confirm the possible existence of *Staphylococcus* spp. and *Escherichia coli*. The *Staphylococcus* spp. showed gray-white to yellowish colonies on mannitol salt agar media. *E. coli* was incubated in eosin methylene blue agar media, which showed metallic sheen colonies.

#### Histopathological observation

For the histopathological study, biopsies were collected on D<sub>1</sub>, D<sub>3</sub>, and D<sub>7</sub> postoperative days from various surgical wounds, which focused on the presence of tissue debris, hemorrhages, and infiltration of reactive cells, indicating the degree of inflammation. The epidermal regeneration and the propagation of connective tissue were also observed (4x) to understand wound healing progress (Figs. 2–4). The histopathological study results on D<sub>1</sub> demonstrated that less tissue debris and hemorrhage were present in the wounds treated with marigold leaves paste and turmeric paste than the control group (Figs. 2a, 3a, and 4a). Besides, on D<sub>3</sub> of observation, the infiltration of more reactive cells was present in the wounds treated with marigold leaves paste than the other two groups (Figs. 2b, 3b, and 4b). Moreover, epidermal regeneration and the proliferation of connective tissue (thickening of the keratin layer) were more prominent in the wound treated with marigold leaves paste than the other two groups (Figs. 2c, 3c, and 4c).

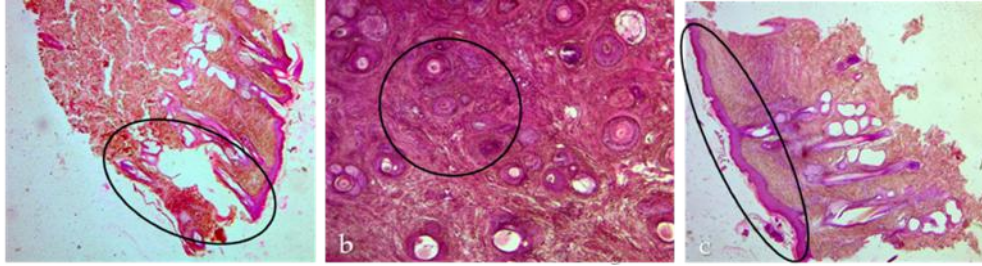
#### Discussion

The sutured wound's breadth was documented from D<sub>0</sub> up to D<sub>21</sub> to realize the reduction of the wound. Results indicated that the sutured area's breadth was remarkably reduced from the D<sub>7</sub> (Table 2) irrespective of treatments. Wound contraction is the inward motion of cutting edges that helps close a wound, which occurs throughout 5–15 days of wounding [20]. Insignificant ( $p > 0.05$ ) difference was detected in terms of the weekly decline of contraction

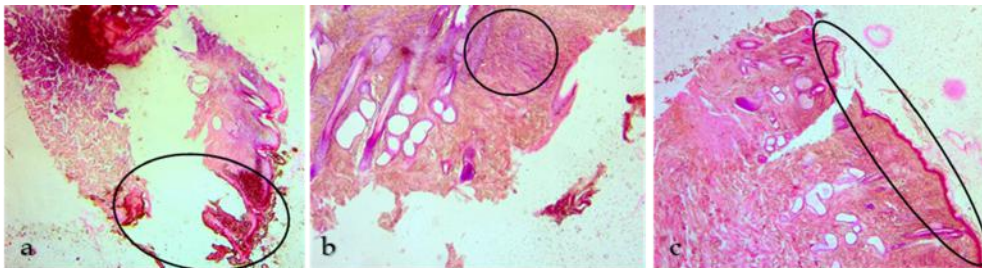
length (Table 1) in the wounds of all groups. This result conforms with the proposition of Yannas et al. [21]. They stated that in the skin, the spontaneous wound healing process occurred through a contractile mechanical area to make collagen fiber meshwork. They also noted that contraction and regeneration of wounds are belligerently related to each other, where wound contraction is a dominant process during the natural healing of wounds.

Among the three treatment groups, the marigold leaves paste and turmeric paste resulted in a lower elevation of the suture line and a swollen area of wounds compared to control. Therefore, the results suggested an obvious tissue reaction in the wounds, which was established by histopathological findings. Infiltration of various inflammatory cells, the existence of hemorrhages, and proliferation of fibroblast tissue were characterized in the histopathological study. This experiment's histological results revealed noticeable infiltration of macrophages in samples obtained from marigold leaf paste and turmeric paste-treated group from D<sub>3</sub> to D<sub>7</sub> (Figs. 2b, 2c, 3b, and 3c). Still, less infiltration of macrophages existed in control (Fig. 4b and c). The infiltration of macrophages indicates the stimulatory effect of the healing of marigold leaves and turmeric paste. The macrophage is beneficial for healing, which promotes inflammation. As a multifunctional cell, the macrophage reduces fibrous and scar tissue formation and improves wounds' healing [22]. The application of marigold leaf extracts twice daily for 3 weeks achieved complete epithelialization in all patients and reduced 41.71% of venous ulcers' surface in the leg [23]. In the present study, marigold leaf paste exhibited better efficacy in the restorative activity of incised wounds.

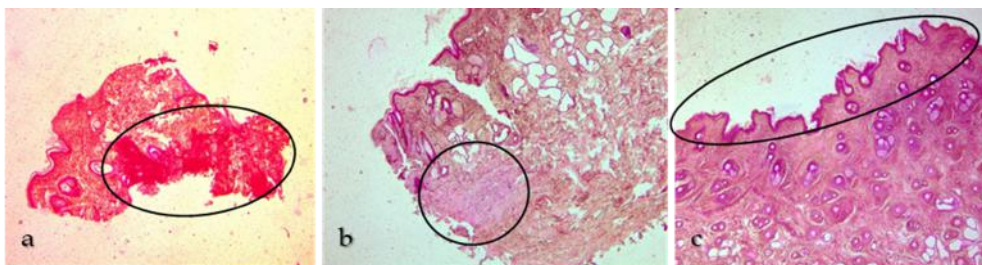
The microbiological study suggested different bacterial colonies were absent in the samples of marigold leaf paste and turmeric paste-treated groups following D<sub>1</sub>. However, the bacterial colonies existed in the culture of samples of the normal saline-treated group until D<sub>3</sub>. Moreover, through Gram stain, cultured samples proved the existence



**Figure 2.** Histological analysis of wound healing processes with marigold leaf paste-treated group stained with H&E (4x). The biopsy samples were collected on days 1 (a), 3 (b), and 7 (c) post-operatively. The existence of ample hemorrhages and tissue debris in the surgical wounds was observed on day 1 (a, black circle). On day 3 post-operation, there was a massive intrusion of inflammatory cells and few hemorrhages in the wound (b, black circle). On day 7, histological analysis showed that there were a satisfactory number of inflammatory cells. Besides, much of the hemorrhages and debris disappeared simultaneously. A thick layer of keratin emerged on the experimental wounds' epidermis (c, black circle).



**Figure 3.** Histological assessment of the biopsies from a group of wounds treated with the turmeric paste and stained with H&E dye (4x). On day 1 (a, black circle), clot, debris, and hemorrhages were perceived on the incised wound. Histological study on day 3 (b, black circle) represents that there were accesses of reactive cells with moderate congestion and hemorrhage. On day 7 (c, black circle), the wound seemed to heal through the intrusion of less reactive cells and the development of a thin layer of keratin on the wound's surface.



**Figure 4.** Histological evaluation of the samples from the normal saline-treated wounds and stained with H&E dye (4x). On day 1 (a, black circle), profuse hemorrhages and tissue debris were seen in the wounds. There were fewer infiltrations of reactive cells with undesired hemorrhages and congestion (b, black circle) on day 3 of the study. On day 7 (c, black circle), the experimental samples contained a small line of keratin and a minimal amount of inflammatory cells. There was less affinity for healing due to a gap between the incised wound's edges (c, black circle).

of *Staphylococcus* spp. and *E. coli*. The bacteria gradually reduced their susceptibility to elimination by the host immune response and antibiotics. Different types of bacteria, such as *Staphylococcus* spp., hemolytic *Streptococci*, and *Pseudomonas* spp. are mostly found in surgical wounds [16]. We have discovered the splendid antibacterial

activity of both the marigold leaf paste and turmeric paste in wound healing in sheep, which is analogous to the findings of Nandita et al. [24] and Dasgupta et al. [25]. They showed the comparative antibacterial action of marigold leaves extracts against *E. coli*, *Staphylococcus aureus*, and *Salmonella typhimurium*.

According to Mir et al. [26], the marigold plant has some unique phytoconstituents useful in wound healing. They also stated that marigolds' pharmacological aspects have antibacterial, antifungal, larvicidal, insecticidal, nematocidal, mosquitocidal, and wound healing activity. Various phytochemicals such as thiophenes, flavonoids, carotenoids, and triterpenoids are isolated from different parts of the plant. Flavonoids have antibacterial activity, and hydro-alcoholic extract of leaves have anti-inflammatory activity [27]. Dasgupta et al. [25] stated that marigold leaf extract has excellent blood clotting properties. Different phenolic composites (gallic acid, ferulic acid, quercetin, and scopoletin) were recognized and measured for blood coagulation. The counts of white blood cells and platelet were increased significantly by the marigold extract. Several alkaloids and calcium ions in the marigold extracts shortened the bleeding and clotting times [28].

On the other hand, various ingredients such as bisacurone B, ar-turmerone, bisdemethoxycurcumin demethoxycurcumin, and curcumin are found in turmeric [29]. Among them, curcumin is the most active component of *C. longa*. It has different bio-functional properties like a free radical scavenger, antioxidant, anti-inflammatory, and antimicrobial activities that help in wound healing progression [14]. According to Zdrojewicz et al. [30], curcumin has wide-ranging applications and anti-inflammatory effects in the cure of various ailments, such as diseases dermis, arthritis, psoriasis, acne, and itching. Curcumin has anti-inflammatory activity and an anti-metastatic impact as well [30,31].

On the contrary, Paul et al. [3] stated that the clinical efficacy of marigold flower paste was not as satisfactory as the turmeric in the wound healing of goat, which is slightly contradictory to our findings. But in their experiment, they did not explain the reasons suggesting their conclusions. The difference in animal species and the use of flowers instead of leaves of marigold might be the reason for this variation.

Some postoperative complications such as excessive swelling, exudation with a foul odor, and stitch abscess in the control group were treated with normal saline. In this research, marigold leaf paste and turmeric paste showed outstanding wound healing progress devoid of any postoperative complications.

## Conclusion

The results of the morphological parameters of wounds and the bacteriological study suggest that both the marigold leaf paste and turmeric paste are similarly effective in healing the incised wound in sheep. However, histopathological studies indicate that the marigold leaf paste is more effective in recovering wounds than the turmeric paste.

Therefore, veterinary practitioners may use the pastes of marigold leaf and turmeric as herbal medicine to treat superficial wounds.

## Acknowledgments

The authors acknowledge and are sincerely grateful to the authority and staff of the Research Animal Farm and Department of Surgery and Obstetrics, BAU, Mymensingh-2202, for their kind support throughout the study period. The authors are also grateful to the Department of Microbiology and Hygiene, BAU, Mymensingh-2202, for facilitating the microbiological study.

## Conflict of interest

The authors do not have any competing interests.

## Authors' contribution

MTR designed and executed the study and also drafted the manuscript. MH drafted and critically reviewed the paper. MTH, MSI, MAR, and MRA reviewed the draft paper and delivered recommendations. NSJ was involved in the study design and thorough supervision of research activities. All the authors read and approved the final version for publication.

## References

- [1] Kumar DA. Evaluation of wound healing activity of leaves of *Bombax Ceiba*. *J Med Sci Clin Res* 2018; 6(12):119–26; <https://doi.org/10.18535/jmscr/v6i12.18>
- [2] Sarker N, Samaddar K, Haq M, Rahman M. Surgical affections of cattle in the milk-shed areas of Bangladesh. *Bangladesh Vet* 2015; 31(1):38–45; <https://doi.org/10.3329/bvet.v31i1.22841>
- [3] Paul S, Rahman ANMA, Al Mahmud MA, Uzzal AR, Das ZC. Wound healing by marigold (*Calendula officinalis*) and turmeric (*Curcuma longa*) paste: a comparative approach. *J Adv Vet Anim Res* 2017; 4(4):333–42; <https://doi.org/10.5455/javar.2017.d229>
- [4] Dall'Acqua S, Cervellati R, Loi MC, Innocenti G. Evaluation of *in vitro* antioxidant properties of some traditional Sardinian medicinal plants: investigation of the high antioxidant capacity of *Rubus ulmi-folius*. *Food Chem* 2008; 106:745–9; <https://doi.org/10.1016/j.foodchem.2007.06.055>
- [5] Abbasi AM, Khan MA, Ahmad M, Zafar M, Jahan S, Sultana S. Ethnopharmacological application of medicinal plants to cure skin diseases and in folk cosmetics among the tribal communities of North-West Frontier Province. *Pak J Ethnopharmacol* 2010; 128:322–35; <https://doi.org/10.1016/j.jep.2010.01.052>
- [6] Passalacqua NG, Guarrera PM, De Fine G. Contribution to the knowledge of the folk plant medicine in Calabria region (Southern Italy). *Fitoterapia* 2007; 78:52–68; <https://doi.org/10.1016/j.fitote.2006.07.005>
- [7] Yoshikawa M, Murakami T, Kishi A, Kageura T, Matsuda H. Medicinal flowers. III. Marigold. (1): Hypoglycemic, gastric emptying inhibitory, and gastroprotective principles and new oleanane-type triterpene oligoglycosides, calendasaponins A, B, C, and D, from Egyptian *Calendula officinalis*. *Chem Pharm Bull* 2001; 49:863–70; <https://doi.org/10.1248/cpb.49.863>



- [8] Kumar B, Vijayakumar M, Govindarajan R, Pushpangadan P. Ethnopharmacological approaches to wound healing—exploring medicinal plants of India. *J Ethnopharmacol* 2007; 114(2):103–13; <https://doi.org/10.1016/j.jep.2007.08.010>
- [9] Jain P, Bansal D, Bhasin PA, Anjali A. Antimicrobial activity and phytochemical screening of five wild plants against *Escherichia coli*, *Bacillus subtilis* and *Staphylococcus aureus*. *J Pharm Res* 2010; 3(6):1260–2.
- [10] Oguwike FN, Onubueze DPM, Ughachukwu P. Evaluation of activities of marigold extract on wound healing of albino wister rat. *IOSR J Dent Med Sci* 2013; 8(5):67–70; <https://doi.org/10.9790/0853-0856770>
- [11] Kasiram K, Sakharkar PR, Patil AT. Antifungal activity of *Calendula officinalis*. *Indian J Pharm Sci* 2000; 62(6):464.
- [12] Bisset NG, Wichtl M. Herbal drugs and phytopharmaceuticals. 2nd edition. Medpharm Scientific Publishers, Stuttgart, Germany, pp 118–20, 2001.
- [13] Varljen J, Lipták A, Wagner H. Structural analysis of a rhamnoarabinogalactan and arabinogalactans with immuno-stimulating activity from *Calendula officinalis*. *Phytochemistry* 1989; 28(9):2379–83; [https://doi.org/10.1016/S0031-9422\(00\)97988-3](https://doi.org/10.1016/S0031-9422(00)97988-3)
- [14] Tejada S, Manayi A, Daglia M, Nabavi SF, Sureda A, Hajheydari Z, et al. Wound healing effects of curcumin: a short review. *Curr Pharm Biotechnol* 2016; 17(11):1002–7; <https://doi.org/10.2174/1389201017666160721123109>
- [15] Hassan W, Gul S, Rehman S, Kanwal F, Afridi MS, Fazal H, et al. Gas chromatography coupled with mass spectrometric characterization of *Curcuma longa*: protection against pathogenic microbes and lipid peroxidation in rat's tissue homogenate. *Pak J Pharm Sci* 2016; 29(2):615–21.
- [16] Miah MA, Hasan M, Sarker YA, Alam MM, Juyena NS. Clinical evaluation of ethanolic extract of curcumin (*Curcuma longa*) on wound healing in Black Bengal goats. *J Adv Vet Anim Res* 2017; 4(2):181–6; <https://doi.org/10.5455/javar.2017.d209>
- [17] Food and Drug Administration. Bacteriological Analytical Manual. 7th edition, Association of Official Analytical Chemists, Arlington, VA. 1992.
- [18] Raheel IAER, Hassan WH, Salem SSR, Salam HSH. Biofilm forming potentiality of *Escherichia coli* isolated from bovine endometritis and their antibiotic resistance profiles. *J Adv Vet Anim Res* 2020; 7(3):442–51; <http://doi.org/10.5455/javar.2020.g440>
- [19] Luna LG. Methods for carbohydrates and mucoproteins. Manual of histologic staining methods of the armed forces institute of pathology. New York, NY: Blakiston Division, McGraw-Hill, pp 153–73, 1968.
- [20] Haque MA, Juyena NS, Hoque MF, Rima UK, Juli SB, Mobarak H, et al. Efficacy of Garlic (*Allium Sativum*) and synthetic antibiotic (Neomycin+ Bacitracin) on the healing of surgical wound in Rabbits. *Int J Agric Sci Vet Med* 2016; 4(3):101–11.
- [21] Yannas IV, Tzeranis DS, So PT. Regeneration of injured skin and peripheral nerves requires control of wound contraction, not scar formation. *Wound Repair Regen* 2017; 25(2):177–91; <https://doi.org/10.1111/wrr.12516>
- [22] Koh TJ, DiPietro LA. Inflammation and wound healing: the role of the macrophage. *Expert Rev Mol Med* 2011; 13; <https://doi.org/10.1017/S1462399411001943>
- [23] Duran V, Matic M, Jovanovć M, Mimica N, Gajinov Z, Poljacki M, et al. Results of the clinical examination of an ointment with marigold (*Calendula officinalis*) extract in the treatment of venous leg ulcers. *Int J Tissue React* 2005; 27(3):101–6.
- [24] Nandita D, Shivendu R, Proud S, Rahul J, Swati M, Arabi MSMA. Antibacterial activity of leaf extract of Mexican marigold (*Tagetes erecta*) against different Gram positive and Gram negative bacterial strains. *J Pharm Res* 2012; 5:4201–3.
- [25] Dasgupta N, Ranjan S, Shree M, Arabi MSMA, Ramalingam C. Blood coagulating effect of marigold (*Tagetes erecta* L.) leaf and its bioactive compounds. *Orient Pharm Exp Med* 2016; 16:67–75; <https://doi.org/10.1007/s13596-015-0200-z>
- [26] Mir RA, Ahanger MA, Agarwal RM. Marigold: from mandap to medicine and from ornamentation to remediation. *Am J Plant Sci* 2019; 10(02):309. <https://doi.org/10.4236/ajps.2019.102024>
- [27] Sing Y, Gupta A, Kannoja P. *Tagetes erecta* (Marigold) -a review on its phytochemical and medicinal properties. *Curr Med Drugs Res* 2020; 4(1):1–6.
- [28] Oguwike FN, Onubueze DPM, Ughachukwu P. Evaluation of activities of Marigold extract on wound healing of albino Wister rat. *IOSR J Dent Med Sci* 2013; 8(5):67–70; <https://doi.org/10.9790/0853-0856770>
- [29] Wang Y, Wang L, Zhu X, Wang D, Li X. Choleric activity of turmeric and its active ingredients. *J Food Sci* 2016; 81(7):H1800–6; <https://doi.org/10.1111/1750-3841.13348>
- [30] Zdrojewicz Z, Szyca M, Popowicz E, Michalik T, Śmieszniak B. Turmeric-not only spice. *Pol Merkur Lekarski* 2017; 42(252):227–30.
- [31] Choi MA, Kim SH, Chung WY, Hwang JK, Park KK. Xanthorrhizol, a natural sesquiterpenoid from *Curcuma xanthorrhiza*, has an anti-metastatic potential in experimental mouse lung metastasis model. *Biochem Biophys Res Commun* 2004; 326(1):210–7; <https://doi.org/10.1016/j.bbrc.2004.11.020>