

## Case Report

# Steps of Distal Radical Gastrectomy for Carcinoma of the antrum and Roux-en-Y gastro-jejunosomy: A case presentation

\*Sardar Rezaul Islam<sup>1</sup>, Mohammad Hanif<sup>2</sup>, Shaikh Mahmud Kamal Vashkar<sup>3</sup>, Shahadat Hossain<sup>4</sup>

### Abstract

A 75 year old man presented with gastric outlet obstruction with a history of vomiting and weight loss for a period of 4 months. He had severe electrolyte imbalance, anemia and malnutrition. CT-scan revealed a huge antral carcinoma occupying the distal half of stomach. Firstly, his anemia and electrolyte imbalance was corrected, followed by preoperative parenteral nutrition. Stapler assisted distal radical gastrectomy and Roux-y gastro-jejunosomy was performed. The patient had excellent post-operative recovery. He was discharged on resumption of oral feeding and referred to the oncologist for adjuvant therapy. This case report, is on steps of stapler assisted distal radical gastrectomy with high resolution operative picture from the Department of Surgery, AWMCH.

**Key words:** Antral carcinoma, distal radical gastrectomy, Bill Roth -II gastro-jejunosomy, Roux-en-Y gastro-jejunosomy.

### Introduction

Gastric cancer (GC) remains a highly malignant tumor with limited therapeutic effect. According to latest statistics of over one million new cases diagnosed worldwide, GC ranked as the 5th most common cancer and fourth most aggressive type with lethal characteristics.<sup>1</sup> In the past few decades, a great progress has been made in its treatment, where radical surgical resection remains the only potential curative option.<sup>2</sup> For most GC cases located in the middle and lower third of the stomach, particularly in the antrum and lesser curvature, distal gastrectomy (resection of the distal two-thirds of the stomach and anastomosis of the proximal stomach to the small bowel) has been recommended.<sup>3</sup> Various reconstruction methods after distal radical gastrectomy have also been introduced.

But, the preferred approach still remains controversial. We report here, a simplified, yet, safe technique of Roux-en-Y anastomosis using linear cutter stapler.

### The Case Details

A 75 year old man attended our surgery Dept. with vomiting and weight loss for 4 months. He had generalized weakness, anemia, malnutrition, hyponatremia, hypokalemia and hypoalbuminemia. On examination, a palpable lump in the epigastrium was found. Upper GI endoscopy could not be performed due to his insubstantial condition. CT scan of the whole abdomen with oral and intra-venous contrast revealed a large growth in the distal stomach occupying the lower half. There was no evidence of liver metastasis. The patient was prepared for surgery with gastric lavage, correction of anemia, correction of electrolyte imbalance and parenteral nutrition support.

### Surgical Technique/ Procedure followed

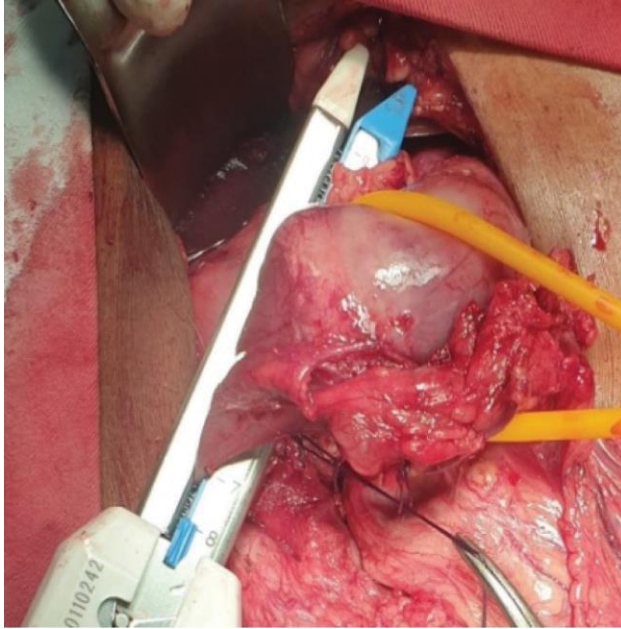
Abdomen was opened by upper midline incision. A huge antral tumor (Malignant Cancer) was found occupying the lower half of the stomach. The tumor was mobile and operable. No liver or peritoneal metastasis was detected. Distal radical Gastrectomy (DG) with Roux-en-Y gastro-jejunosomy was planned, especially for such small gastric segment. Two-third of distal stomach was mobilized and was de-vascularized with liga-sure and vicryl ligature. Duodenum was transected from the tumor by blue cartridge linear cutter stapler (Auto-suture) as shown in Fig-1.

1. \*Professor and Head, Department of Surgery, Ad-din Women's Medical College Hospital (AWMCH)
2. Assistant Professor, Department of Surgery, Ad-din Women's Medical College Hospital (AWMCH)
3. Registrar, Department of Surgery, Ad-din Women's Medical College Hospital (AWMCH)
4. Associate Professor, Department of Pathology, Ad-din Women's Medical College Hospital (AWMCH)

**Correspondence:** Prof. Sardar Rezaul Islam, Professor and Head, Department of Surgery, Ad-din Women's Medical College Hospital (AWMCH)

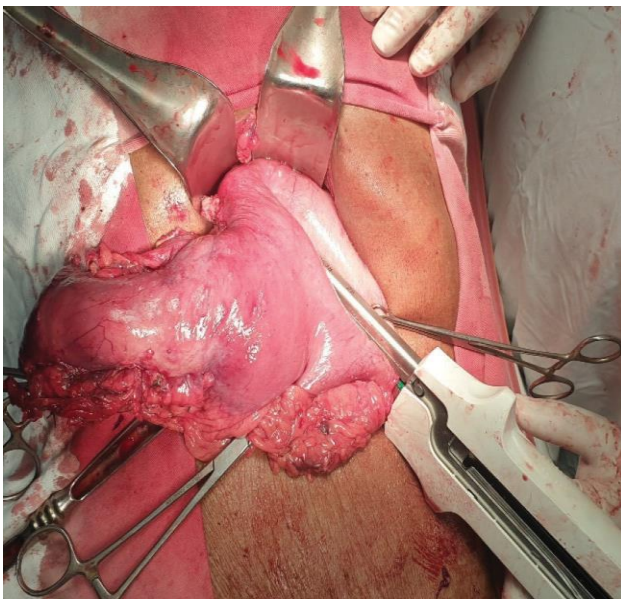
**Received Date :** 02 October, 2021

**Accepted Date :** 25 December, 2021

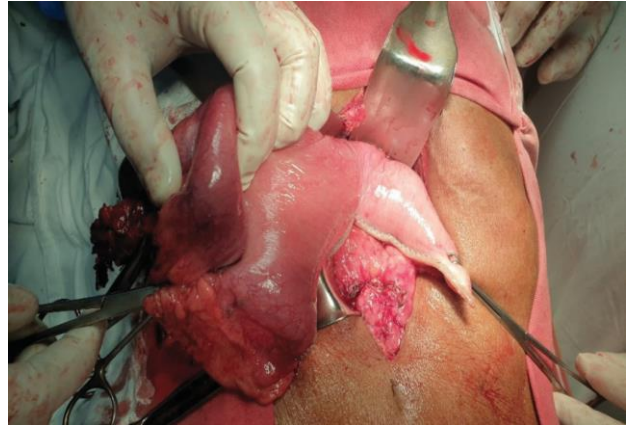


**Fig-1:** Application of Linear stapler (Blue cartridge) between duodenum and the tumor

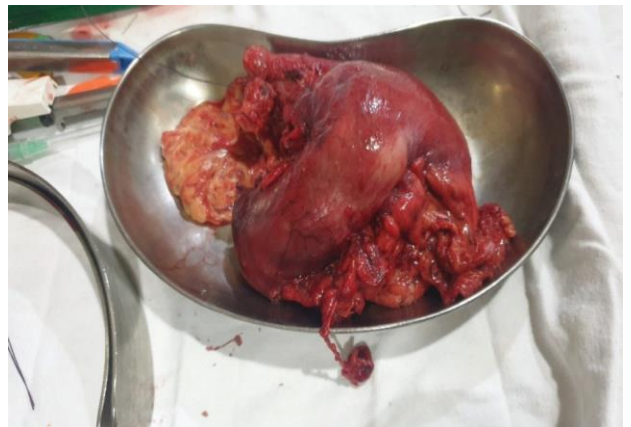
The duodenal stump was further reinforced with horizontal mattress suture with vicryl. The upper one-third of the stomach was divided from the tumor by two green cartridge linear cutter stapler which has been shown consequently in Fig-2 followed by 3 and 4.



**Fig-2:** Application of linear stapler with green cartridge between the body of the stomach and the tumor with adequate healthy margin.

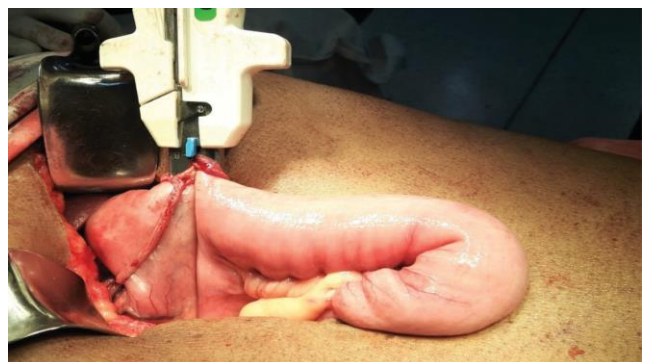


**Fig-3:** Partial division between the healthy gastric remnants and the tumor, another stapler was used to complete the division (Not shown in the picture).



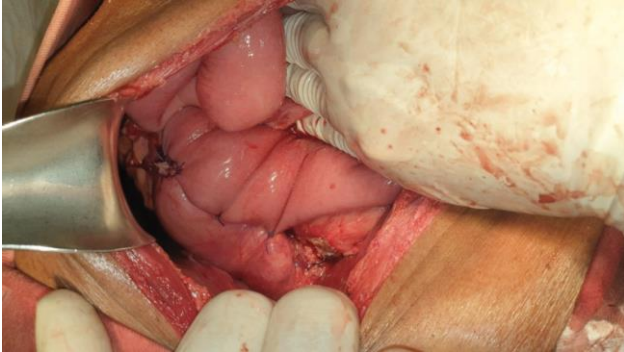
**Fig-4:** Resected stomach with the tumor

The jejunum was divided 30 cm distal to the Dusteno-Jejunal flexure. The Proximal Roux loop was anastomosed with the stomach segment with a blue cartridge linear cutter stapler demonstrated in Fig-5.

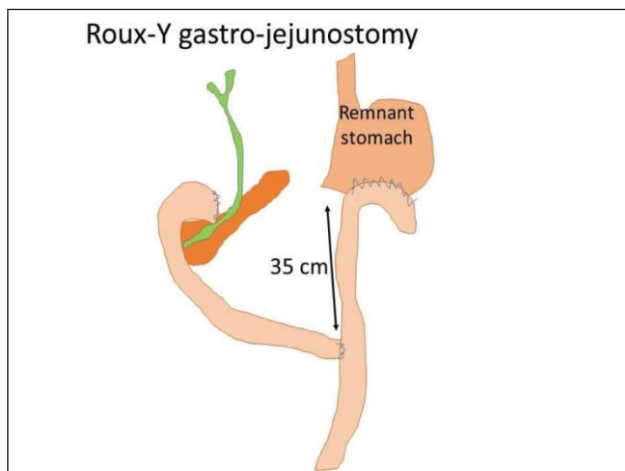


**Fig-5:** Anastomosis between the gastric remnant and a Roux-loop of the Jejunum with a blue cartridge

The window was closed with a single layer interrupted vicryl suture, (Fig-6). The proximal jejunum was joined to the Roux-loop by end-to-side jejuno-jejunal anastomosis to restore intestinal continuity, (Fig-7).



**Fig-6:** Gastro-Jejunosomy suture line



**Fig-7:** Diagrammatic picture of Roux-Y Gastro-jejunosomy after distal radical gastrectomy.

#### Post-operative management and timeline

The patient stayed in ICU for 5 days with the support of total parenteral nutrition. Oral feeding was resumed on 7th post-operative day. He was discharged from the hospital on 9<sup>th</sup> post-operative day.

Histopathology confirmed well differentiated adenocarcinoma with tumor free resection margin; with lymph nodes involvement. He was referred to oncologist for further adjuvant therapy. The patient was discharge with the advice of follow up visit after 2 weeks to reveal his condition fine.

#### Discussion

Several studies revealed that stapled anastomosis is superior to the manual hand-sewn anastomosis in terms

of operating time and hospital stay.<sup>4-5</sup> So, stapled anastomosis is a preferable than hand-sewn anastomosis for distal radical gastrectomy and Roux-Y reconstruction.

Currently, Bilroth-II and Roux-en-Y (R-Y) reconstructions are commonly performed after distal gastrectomy for gastric cancer. Traditionally R-Y reconstruction has been the method of choice in total gastrectomy<sup>6</sup> and is being increasingly used to prevent duodeno-gastric and gastro-esophageal reflux in distal radical gastrectomy (DG) also.<sup>7-8</sup> The potential advantages of improved post-operative quality of life (QOL) take precedence over the possible increased risk of post-operative complications due to multiple anastomoses and increased operating time in Roux -Y reconstruction.

The operating time was significantly shorter in Bilroth-II gastrojejunostomy than Roux-Y gastrojejunostomy, which can be explained by the additional anastomosis in R-Y reconstruction. However, no difference was reported in the rate of anastomotic leak within the two types of gastro-jejunosomy after the DG surgery. It may be largely due to the use of gastrointestinal stapling devices and the refinement of technique.<sup>9</sup> The Roux-Y reconstruction following the DG surgery is superior to Bill Roth-II reconstruction. This prevents bile reflux, segment gastritis and reflux esophagitis too, as it reduces duodena-gastric and gastro esophageal reflux.<sup>10-11</sup>

#### Conclusion

Currently, Bilroth-II and Roux-en-Y (R-Y) reconstructive surgeries are more commonly performed after distal gastrectomy for gastric cancer but which of these reconstruction procedures is superior remains controversial. However, most of the study favors Roux-en-Y reconstruction for prevention of bile reflux and gastro esophageal reflux, thus save a revision surgery.

#### References

1. Sung H, Ferlay J, Siegel RL, Laversanne M, Soerjomataram I, Jemal A, et al. Global cancer statistics 2020: GLOBOCAN estimates of incidence and mortality worldwide for 36 cancers in 185 countries. *CA Cancer J Clin.* (2021) 71(3):209–49. doi: 10.3322/caac.21660
2. Smyth EC, Nilsson M, Grabsch HI, van Grieken NC, Lordick F. Gastric cancer. *The Lancet.* (2020) 396(10251):635–48. doi: 10.1007/s10120-020-01042-y

3. Japanese Gastric Cancer Association. Japanese Gastric cancer treatment guidelines 2018 (5th edition). *Gastric Cancer*. (2021) 24(1):1–21. doi: 10.1007/s10120-020-01042-y
4. Seo SH, Kim KH, Kim MC, Choi HJ, Jung GJ. Comparative Study of Hand Sutured versus Circular Stapled Anastomosis for Gastrojejunostomy in Laparoscopy Assisted Distal Gastrectomy. *J Gastric Cancer*. 2012Jun;12(2):120–125
5. Anwar S, Hughes S, Eadie AJ, Scott NA. Anastomotic technique and survival after right hemicolectomy for colorectal cancer. *Surg J R Coll Surg Edinb Irel.*, 2004; 277-280
6. Kumagai K, Shimizu K, Yokoyama N, Aida S, Arima S, Aikou T. Questionnaire survey regarding the current status and controversial issues concerning reconstruction after gastrectomy in Japan. *Surg Today*. 2012;42:411–418.
7. Shinoto K, Ochiai T, Suzuki T, Okazumi S, Ozaki M. Effectiveness of Roux-en-Y reconstruction after distal gastrectomy based on an assessment of biliary kinetics. *Surg Today*. 2003;33:169–177.
8. Fukuhara K, Osugi H, Takada N, Takemura M, Higashino M, Kinoshita H. Reconstructive procedure after distal gastrectomy for gastric cancer that best prevents duodenogastroesophageal reflux. *World J Surg*. 2002;26:1452–1457.
9. Namikawa T, Kitagawa H, Okabayashi T, Sugimoto T, Kobayashi M, Hanazaki K. Double tract reconstruction after distal gastrectomy for gastric cancer is effective in reducing reflux esophagitis and remnant gastritis with duodenal passage preservation. *Langenbecks Arch Surg*. 2011; 396:769–776.
10. Shinoto K, Ochiai T, Suzuki T, Okazumi S, Ozaki M. Effectiveness of Roux-en-Y reconstruction after distal gastrectomy based on an assessment of biliary kinetics. *Surg Today*. 2003;33:169–177.
11. Namikawa T, Kitagawa H, Okabayashi T, Sugimoto T, Kobayashi M, Hanazaki K. Roux-en-Y reconstruction is superior to billroth I reconstruction in reducing reflux esophagitis after distal gastrectomy: special relationship with the angle of his. *World J Surg*. 2010;34:1022–1027.