

## Review Article

# Trailing Nocardiosis- A Non-healing Wound Infection: Where does Bangladesh stand? An Updated Review!

Sadah Hasan<sup>1</sup>, Umama Binte Delwar<sup>2</sup>, Khadiza Dilshad,<sup>3</sup> Kazi Selim Anwar<sup>4</sup>, \*Afzalunnessa Binte Lutfor<sup>5</sup>

### Introduction

Organisms of the genus *Nocardia* are associated with the microorganisms known as the actinomycetes<sup>1</sup> and belong to the family Mycobacteriaceae. *Nocardia* causes a variety of illnesses in humans and other mammals. It normally enters the body via the airways, but may also be directly inoculated into the skin, causing primary cutaneous disease. Nocardiosis is thought to be an uncommon bacterial infection with a wide variety of clinical manifestations in immunocompromised patients.<sup>5,6</sup> The number of cases is not reported frequently but is increasing, yet the literature for nocardiosis still remains limited in Bangladesh. Thus, this updated review with open up a new horizon for nocardiosis with its detailed clinico-epidemiological characteristics-that may help our clinician and medical researchers expand their horizons too.

### Background

To identify any pathogen associated with long term non-healing wound infections, it can often be a great decision to keep a high index of suspicion directed towards 'Nocardia', a weakly acid-fast bacilli that is typically found among immune-compromised patients.<sup>1, 2</sup>

1. Lecturer, Dept. of Pathology, AWMCH, Moghbazar, Dhaka
2. Lecturer, Dept. of Anatomy, AWMCH, Moghbazar, Dhaka
3. Medical Officer (ICU), AWMCH, Moghbazar, Dhaka,
4. Head, Medical Research Unit, AWMCH, Moghbazar, Dhaka,
5. \*Professor & Head, Dept. of Microbiology, AWMCH, Moghbazar, Dhaka

\*Correspondence: Prof. Afzalunnessa Binte Lutfor, Professor & Head, Dept. of Microbiology, AWMCH, Moghbazar, Dhaka

Received Date : 15 November, 2021

Accepted Date : 20 February, 2022

*Nocardia* has more than a 100 identified species, of which 54 species remain pathogenic to humans.<sup>3,4,2</sup> This ubiquitous pathogen *Nocardiae* is commonly found in the environment of tropical and subtropical countries, making exposure to this acid fast bacilli unavoidable.

And yet, it has been scarcely reported from Bangladesh where we studied this infection in patients first in 2017, and again in 2021, was revealed in immune-competent patient's too.<sup>5,6</sup>

*Nocardia* is overlooked owing to the existence of more well-known acid-fast bacilli of the same family, the infamous 'Mycobacterium tuberculosis' in a high TB-burdened country like Bangladesh, and this situation is similar to other developing countries.

So, this review is aimed at describing and updating information on both the *Nocardia* & the infection caused by it- 'Nocardiosis'. The following has been addressed in this updated review:

- i) Latest clinico-epidemiological aspects of Nocardiosis.
- ii) Laboratory aspects
- iii) Updated diagnostic approach
- iv) Latest attempt to enrich/upgrade the issues of Prevalence of *Nocardia* spp. causing non-healing-wound infections, and, finally-
- v) Focused brief activities on Nocardiosis in randomly selected districts in Bangladesh (including a short project submitted at the Ministry of Health & Family Welfare for funding, last year)

### Methodology of this Updated Review:

We followed the standard format of writing up a systematic review, with slight modifications and/or short cuts that does not hamper neither in the quality of this updated review nor leaving out any crucial or relevant information required to write this updated review on nocardiosis caused by an ubiquitous filamentous pathogen/bacteria 'Nocardia'

This systematic review critically synthesizes literature on many details on Nocardia.

### Strategy of Literature Search and Selection Criteria of Published Articles

#### I. Search Engines Utilized:

The following 9 (nine) **search engines** were utilized in preparing this updated review, as practicable:

- 1) **Google/ Scholar**
- 2) **PubMed**
- 3) **Elsevier:** Introduced in 2000 **it remains the 1<sup>st</sup> academic search engine** that mixed up authoritative sources such as publisher platforms & open access repositories with a deep crawl of academic web pages
- 4) **EM-BASE** Embase.com are two search engines that are commonly used for searching the Medline and Embase databases which remains a standard of practice to conduct a search for a systematic literature review
- 5) **Cochrane** (accessed through HINARI)
- 6) **CINAHL** (accessed through HINARI)
- 7) **Scopus** (accessed through HINARI)
- 8) **MEDLINE** (accessed through EM-Base, Scopus, Cochrane and HINARI)
- 9) **HINARI** (Capacity Building Resource): launched in 2002, provides access to key databases viz., PubMed (full text), Cochrane, CINAHL, and Scopus. HINAR remains now one of the primary portals accessed by researchers and clinicians particularly in developing countries.

#### II. Year specific published literature was searched over the last 10 years:

Starting from **as early as 2013** through the **latest period of 2023** (updated)

### III. Key words used to find out pertinent published literature

Nocardia subject headings were used in the execution of PubMed and MEDLINE searches. Search terms related to nocardiosis included "global scenario", "Prevalence of Bangladesh", "clinico-epidemiological aspect", "laboratory aspect". "diagnosis". Google Scholar was used to obtain additional articles identified by journal hand searching.

#### IV. Data basing:

All database search results were imported into EndNote. Duplicate entries were removed before screening. Data were extracted by using a table developed by the research team. Data extracted included author, year, country, aim, research design, sample, participants, and relevant findings. Relevant findings were those that related to the inclusion criteria, including nocardiosis, global scenario, Prevalence of Bangladesh, clinico-epidemiological aspect, laboratory aspect, diagnosis. To ensure accuracy, another investigator cross-checked the extracted data of all included studies using the full-text study.

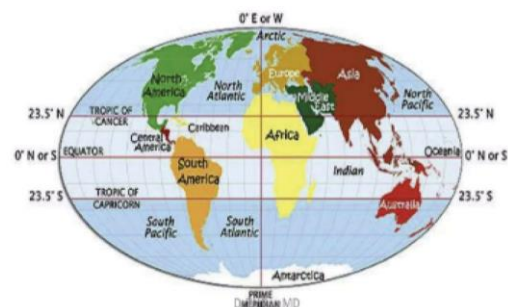### Results and Findings:

#### Global Prevalence of Nocardia and its Existence in the Environment

### *Nocardia* : ECOLOGY & EPIDEMIOLOGY

- Ubiquitous environmental saprophyte
- Soil, organic matter, water
- Tropical and subtropical regions

:Mexico, Central and South America, Africa and India



Studies from different countries have demonstrated that *Nocardia* infection among non-immune-compromised people is usually seen in agricultural workers, or patients with history of surgery, trauma and poor hygienic practices etc.<sup>7,8,9</sup>

One such retrospective study was conducted in a tertiary care hospital in Saudi Arabia and is given in brief as follows:

**Nocardiosis in a Tertiary Care Hospital in Saudi Arabia** (Dept. Med, Pulmonary Div, King Saud Univ for Health Sc, King Abdullah Intern'l Res Center, Dept. Intensive Care, King Saud Univ. for Health Science, King Abdullah Intern'l Research Center, 2Dept. of Med, Div of Med, & 3Dept. of Infect Control, King Saud bin Abdulaziz University for Health Sciences, King Abdulaziz Medical City, Riyadh, Saudi Arabia )

The prevalence of Nocardia infection in Saudi Arabia is not known. Sporadic cases of Nocardia infection causing mycetoma have been reported from the northwest region. Recently, the Kingdom of Saudi Arabia has become a leading center for solid organ and bone marrow transplantations in the Middle East. Infection with this opportunistic pathogen is expected to become more prevalent. Hamdan Al-Jahdali et. al. performed a 10-year retrospective review of all cases of nocardiosis identified at the King Fahad National Guard Hospital in Riyadh. Clinical presentation, risk factors, site of disease involvement, radiological features, and outcomes of 30 patients with pulmonary and disseminated nocardiosis are presented.

**Materials and Methods:** A retrospective chart review of all cases of nocardiosis over the last ten years.

**Results:** Thirty cases of nocardiosis were identified. The disease was more common in males. Fever and cough

was the most common presentation. Most of the patients had an underlying pulmonary disease.

**Conclusion:** Nocardiosis is not uncommon in Saudi Arabia. Cases are not restricted to the classical immunocompromised host. A database is urgently needed to better evaluate the prevalence of the illness among the Saudi population.

#### **Geographical areas and countries covered (from published literature)**

Which included computerized searches, ancestry searching, and journal hand searching to ensure the inclusion of all eligible studies. The studies included quantitative studies and qualitative studies from (India, Pakistan, Malaysia, Ghana, Lithuania, Iran, Albania but in rich countries (UAE, Saudi Arabia) including in western ones (Canada, USA, etc.).

#### **Prevalence in Bangladesh**

The actual prevalence of Nocardiosis in Bangladesh may be underreported due to grossly limited lab facilities to diagnose this pathogen, clinicians' low index of suspicion of Nocardiosis in a Tuberculosis-prone country, and the extended time to yield this bacilli's growth leading to contamination which obscures its presence.<sup>6</sup>


However, researchers from other countries have reported similar findings in Bangladesh (29%) or higher occurrence of Nocardiosis (up to 40%) among immunocompetent in other countries.<sup>5,10,9</sup>

In healthy people, Nocardiosis is commonly found primarily in skin/ muco-cutaneous or lung infections showed from Bangladesh.<sup>5,6</sup> For immune deficient people, it can invade any organ of the body which may eventually lead to fatal conditions such as sepsis, bone and brain infection; mortality ranging from 20 to 30% in disseminated infection and 50% in CNS involvement, as found in other countries.<sup>13</sup>

#### **Existing Dilemma: How is Nocardia missed?**

Histopathological findings of Nocardia infections mimic the granulomatous lesion of Tuberculosis (TB) and therefore, often treated with antitubercular drugs which ultimately fails to cure Nocardia spp.<sup>14, 15</sup> The patient with non-healing wound infection due to Nocardiosis suffers from waning health for years which heals and again re-emerges as discharging sinuses in and around the site of the inoculation of the organism if misdiagnosed and empirically treated with broad spectrum antibiotics.<sup>5</sup>

In a TB-burdened country like Bangladesh, majority of Nocardial infections go unsuspected by clinicians owing



to its nonspecific clinical picture. Furthermore, if clinicians do not suspect and request for *Nocardia/Actinomyces* identification or if it is not mentioned on the requisition form, microbiologists may miss the organism due to several reasons. viz.

- The *Nocardiae* often becomes **Gram negative** and **non-acid fast** depending on the **cell wall components, old culture, staining procedure** etc.,
- Its culture needs extended incubation from minimum 3 days to weeks which may dry the media or yield the growth of other flora before *Nocardiae* is able to grow, and considered as no growth/contaminant.
- Their colonies are usually very small in size initially, dry with aerials, and show chalky white color turning gradually to orange which often may be considered as **contaminant**.<sup>16, 2, 12</sup>
- Moreover, ***Nocardiae* diagnosis in the microbiology laboratory is hampered and therefore underreported due to extended time demand for satisfactory growth.**<sup>17</sup> In absence of selective media, growth recovery requires multiple subcultures and repeated observation of many slides to clinch the diagnosis.

Lutfor et. al., 2021 illustrates the case of a 32-year-old man who presented with a chronic discharging sinus in the neck and had a history of excisional biopsy at this site a few years earlier. Based on the histopathological findings, he had been on an anti-TB regimen for more than a year, followed by multiple antibiotic courses with no improvement. The culture from the sinus revealed *Nocardia*, and treatment with Doxycycline was started, after which the lesion healed after a year.

Another case is of a 30 year old who underwent lower uterine caesarean section (LUCS) half a year ago, had a five-month-old discharging sinus, with a pocket under the skin, situated above the caesarean wound. A complete regimen of anti-TB drugs did not heal the sinus. *Nocardia* spp. was isolated from the sinus, and a regimen of amoxicillin-clavulanic acid for 6 months healed the wound.<sup>6</sup>

It is to be noted that *Nocardia* spp. can cause an acute primary infection which later on may become chronic where the organism remains hidden in a pocket behind the afflicted tissue. This is not easily discernible and leads to unsatisfactory collection of specimens if the collector is not aware or not adequately trained.

Specimen requires meticulous microscopy by experts to exclude *Actinomyces* spp. and fungi by Gram stain and confirm *Nocardia* spp. by modified Ziehl-Neelsen (MZN) stain, from their slow growth on artificial culture media.<sup>2,5,6</sup>

### Diagnosis of *Nocardiae*

In the light of currently available methodologies that can provide accurate and rapid results on diagnosis or speciation (gene sequencing and matrix-assisted laser desorption ionization–time of flight mass spectrometry [MALDI-TOF MS]), the use of biochemical testing is neither accurate nor timely. Molecular methodologies, specifically, gene sequencing, have become the most accurate technique to definitively identify *Nocardia* to the species level.<sup>12</sup>

Diagnosis can be done from a quality specimen by diligent microscopy of traditional Gram stain and modified Ziehl-Neelsen (MZN) staining as well as from growth in extended incubation.<sup>6</sup> Genus level identification for drug susceptibility testing is thought to be sufficient for appropriate treatment.<sup>7, 2</sup>

### Studies on Nocardiosis in Bangladesh: Another step ahead!

Despite its ubiquity, reported data and/or published articles remain very scarce in Bangladesh, so far only **three** studies on Nocardiosis have been reported from **Bangladesh**: notably two by Prof. **Afzalunnessa Binte Lutfor, which was published in 2017, and in an internationally reputed journal in 2021, and earlier in 2012 when** a group of icddr, b scientists published a study in BJCH. This reveals that neither earlier nor in recent days had *Nocardia* been studied well in this country.

However, we, at the Microbiology laboratory of Ad-din Women's Medical College Hospital (AWMCH) confirmed the presence of *Nocardia* in patients who suffered from festering infections having non-healing discharging sinuses, for a period of months to years.

Study at AWMCH also found that *Nocardiosis* patients had taken courses of antibiotics, specially anti-tubercular and/or antifungal drugs prior to diagnosis, with no improvement. But after a proper diagnosis they were cured with a single appropriate antimicrobial regimen.<sup>6</sup>

### Treatment of *Nocardia*

*Nocardia* needs a course of appropriate antibiotics (minimum 6 months to 2 years)<sup>14</sup> making it an important pathogen which should not be missed out by the

microbiologists or clinicians in order to reduce the suffering of patients.<sup>18,19</sup>

We also have to keep in mind that antimicrobial susceptibility is changing: a rising trend of resistance to commonly used drugs especially cephalosporins has been reported by different authors<sup>20, 21, 22</sup> including us.<sup>5,6</sup> The variations in susceptibility patterns among different species of *Nocardia* have also been documented in earlier studies.

Not much is known about the genetic basis of resistance in *Nocardia*, but alarming findings suggest that *Nocardia* isolates are capable of and already have acquired mobile elements carrying resistance conferring alleles.<sup>20</sup> Therefore, it is imperative to exercise caution by using dedicated equipment in laboratories while conducting *Nocardia* diagnosis.

### **Impact of conducting research on *Nocardia* in tier specific localities in Bangladesh (upazilla, district, divisional and country level)**

\*Properly identified *Nocardia* spp. will encourage microbiologists in lab diagnosis

\*Updated data will motivate clinicians to confidently suspect Nocardiosis more, where applicable.

\*Accurate findings, early diagnosis and optimum treatment of Nocardiosis will assist in reducing patients' sufferings.

\*Capacity building of more microbiologists to be oriented in identifying *Nocardia*

\*Capacity building to assist conducting epidemiological research to create a prudent database both at the local, district & national level.

\*Utilizing the aforementioned database to optimize rational treatment leading to proper antibiotic use and prevention of MDR from antibiotic misuse.

Thus, timely and enhanced research on Nocardiosis, for microbiologists, clinicians and patients, needs to be conducted.

### **In Conclusion**

In non healing surg-wounds infection with noncardia spp. should be considered. If *Nocardia* remains undiagnosed and improperly treated, empirical use of antimicrobials will contribute to increased resistance and further subject the patient to more cycles of treatment failure. Thus, proper case diagnosis and treatment with prudently selected antibiotics according to susceptibility

pattern will bring an end to the physical sufferings, psychological miseries and financial burdens of the patient. Therefore, the determination of the prevalence of Nocardiosis in Bangladesh will highlight the neglected yet clinically challenging problem.

### **References**

1. Sharma N, Mahajan V, Agarwal S, Katoch V, Das R, Kashyap M, et al. Nocardial mycetoma: Diverse clinical presentations. *Indian J Dermatol Venereol Leprol* 2008;74:635–40.
2. Murray PR, Rosenthal KS, Pfaller MA et al. *Nocardia* and related bacteria. *Medical Microbiology*, 7th Edition, Chapter 28. Philadelphia PA, Elsevier Saunders Press, 2013:228–232.
3. Baio PVP, Ramos JN, Santos LS dos, Soriano MF, Ladeira EM, Souza MC, et al. Molecular Identification of *Nocardia* Isolates from Clinical Samples and an Overview of Human Nocardiosis in Brazil. *PLoS Negl Trop Dis* 2013;7.
4. Conville PS, Brown-Elliott BA, Smith T, Zelazny AM. The complexities of nocardia taxonomy and identification. *J Clin Microbiol* 2018;5
5. Lutfor AB, Saha R, Deb A, Mujtaba Mahmud A, Ahmed A, Ali A, et al. Detection of *Nocardia* from Chronic Skin and Lung Infections in Bangladeshi Patients. *Am J Infect Dis Microbiol* 2017;5:80
6. Lutfor, Afzalunnessa & Afroz, Samira & Mahmud, Asif & Selim, Tasmiah & Akhter, Taskina & Sultana, Tamanna & Taskeen, Sadia. (2021). *Nocardia* infection causing non-healing surgical wounds: A case series from Bangladesh. *International Journal of Infectious Diseases*. 110. 10.1016/j.ijid.2021.07.028.
7. Ambrosioni J, Lew D, Garbino J. Nocardiosis: Updated clinical review and experience at a tertiary center. *Infection* 2010;38:89–97.
8. Minero MV, Marín M, Cercenado E, Rabadán PM, Bouza E, Muñoz P. Nocardiosis at the turn of the century. *Medicine (Baltimore)* 2009;88:250–61.
9. Steinbrink J, Leavens J, Kauffman CA, Miceli MH. Manifestations and outcomes of nocardia infections: Comparison of immunocompromised and non-immunocompromised adult patients. *Med (United States)* 2018;97.
10. Dawar R, Girotra R, Quadri S, Firdaus I, Mendiratta L, Rani H et al. Epidemiology of Nocardiosis - A six years study from Northern India. *J Microbiol and Infect Diss*. 2016; 6(2): 60–64.

11. Tan CK, Lai CC, Lin SH, Liao CH, Chou CH, Hsu HL, et al. Clinical and microbiological characteristics of Nocardiosis including those caused by emerging Nocardia species in Taiwan, 1998-2008. *Clin Microbiol Infect* 2010;16:966–72. Conville PS, Witebsky FG. Nocardia, Rhodococcus, Gordonia, Actinomadura, Streptomyces, and Other Aerobic Actinomycetes. *Man. Clin. Microbiol.*, ASM Press; 2015, p. 504–35. <https://doi.org/10.1128/978155-5817381.ch29>.
12. Rouzaud C, Rodriguez-Nava V, Catherinot E, Méchaï F, Bergeron E, Farfour E, Scemla A, Poirée S, Delavaud C, Mathieu D, Durupt S, Larosa F, Lengelé JP, Christophe JL, Suarez F, Lortholary O, Lebeaux D. Clinical Assessment of a Nocardia PCR-Based Assay for Diagnosis of Nocardiosis. *J Clin Microbiol*. 2018 May 25;56(6):e00002-18.
13. Chen N, Qin Q, Sun KD, Luo D, Cheng QH. An unusual successful treatment with non-sulfonamides: Primary cutaneous nocardiosis caused by Nocardia brasiliensis. *Ther Clin Risk Manag* 2018;14:1661–4.
14. Tang R, Yang J, Liu H, Zhou K, Fei J. Metacarpal tuberculosis with Nocardia infection: A case report. *Medicine (Baltimore)* 2020;99:e18804.
15. Saubolle MA, Sussland D. Nocardiosis: Review of clinical and laboratory experience. *J Clin Microbiol* 2003;41:4497–501.
16. Kandi V. Human Nocardia Infections: A Review of Pulmonary Nocardiosis. *Cureus* 2015;7. <https://doi.org/10.7759/cureus.304>.
17. Ash MM, Hamad J, Ziemer CM, Googe PB. Prompt identification of primary cutaneous nocardiosis with immunohistochemical staining. *JAAD Case Reports* 2020;6:848–51.
18. Muñoz J, Mirelis B, Aragón LM, Gutiérrez N, Sánchez F, Español M, et al. Clinical and microbiological features of nocardiosis 1997-2003. *J Med Microbiol* 2007;56:545–50.
19. Mehta HH, Shamooy Y (2020) Pathogenic Nocardia: A diverse genus of emerging pathogens or just poorly recognized? *PLoS Pathog* 16(3): e1008280.
20. Duggal SD, Chugh T Das. Nocardiosis: A Neglected Disease. *Med Princ Pract* 2020;29:514–23.
21. Rahman ME, Rahman AM, Rahman M, Ali MR, Chowdhury AS, Shams N, et al. Disseminated Nocardiosis in a Patient with Chronic Granulomatous Disease: A Case Report. *Bangladesh J Child Heal* 2012;35:68–70.