

## Original Article

# Morphometry of Dry Ossified Left Human Clavicle

Nazia Binte Islam<sup>1</sup>, Segupta Kishwara<sup>2</sup>, Sharmin Rahman<sup>3</sup>, Afsara Tasnim<sup>4</sup>, Fatema Ershad<sup>5</sup>

### Abstract

**Background:** The clavicle is a modified long bone placed horizontally and subcutaneously at the root of the neck. This bone shows high variability in its shape and size; more frequently than other long bones of the human skeleton. It has its peculiarities with ossification; it is the first bone to start ossification. It is one of the bones of the shoulder girdle in humans and in those mammals, who use their hands for pretensions. It plays an important role in sex determination in humans; length, midclavicular circumference, and rhomboid fossa are principal indicators for sex determination.

**Objective:** To provide osteometric data on clavicles in the Bangladeshi population.

**Materials and Methods:** The present study was a cross-sectional analytical type of study, carried out in the Department of Anatomy, Dhaka Medical College, Dhaka, Bangladesh from January 2022 to December 2022. A total of 120 dry ossified left human clavicles were collected from Dhaka Medical College, Dhaka. Most of the variables were measured with the help of a digital Venire caliper.

**Results:** Out of 120 clavicles 70 were males and 50 were females. The straight length of the clavicle, mid-shaft circumferences, and straight length of the rhomboid fossa were greater in males than females.

**Conclusion:** The clavicle is crucial for determining sex, length, circumference, and rhomboid fossa size which differed significantly between males and females, with males having larger measurements.

**Keywords:** Length of the clavicle, Midclavicular circumference, straight length of Rhomboid fossa

### Introduction

The clavicle is named after the Latin *clavicula* ("little key") because, during abduction of the shoulder, the bone rotates along its axis like a key<sup>1</sup>.

The clavicle shows high variability in its shape and size; more frequently than other long bones of the human skeleton. Clinicians and forensic anthropologists have widely examined the anatomical variability of this important bone of the thoracic skeleton<sup>2</sup>.

The clavicle is a modified long bone placed horizontally and subcutaneously at the root of the neck<sup>3</sup>. The clavicle is the only bony connection between the trunk and the

upper limb. It is palpable along its entire length and has a slight S-shaped contour, with the forward-facing convex part medially and the forward-facing concave part laterally<sup>4</sup>. The clavicle is one of the bones of the shoulder girdle in humans and in those mammals who use their hands for prehension. Morphologically it is a distinct bone. It is the first bone to start ossification in the 5<sup>th</sup> or 6<sup>th</sup> week of intrauterine life and the last bone to complete ossification usually after 21 years<sup>5</sup>. It begins its ossification in the membrane with two primary centers<sup>6</sup>. The clavicle transmits the weight of the upper limb to the axial skeleton<sup>3</sup>. It has a cylindrical shaft and two ends that are sternal and acromial end. The shaft is divided into lateral one-third and medial two-thirds<sup>7</sup>.

The superior surface is subcutaneous and the inferior surface bears an elevation called the conoid tubercle and a ridge called the trapezoid ridge<sup>8</sup>. The lateral third of the inferior surface has the subclavian groove<sup>9</sup>.

A clavicle fracture is more common in children and adults. Fracture clavicle is more common and occurs more frequently at the junction of the medial two-thirds and lateral one-third. In case of neurovascular injury or significant fracture displacement, surgical intervention may be required<sup>3</sup>.

The Journal of Ad-din Women's Medical College; Vol. 12 (2), July 2024; p 11-14  
<https://doi.org/10.3329/jawmc.v12i2.79231>

1. Assistant Professor, Department of Anatomy, Asgar Ali Medical College, Dhaka.
2. Professor and Head, Department of Anatomy, Dhaka Medical College, Dhaka.
3. Associate Professor, Dept. of Anatomy, Ad-din Women's Medical College, Dhaka
4. Assistant Professor, Dept. of Community Medicine, Ad-din Women's Medical College, Dhaka.
5. Assistant Professor, Dept. of Pharmacology, Ad-din Women's Medical College, Dhaka.

**Correspondence:** Nazia Binte Islam, Assistant Professor, Department of Anatomy, Asgar Ali Medical College, Dhaka. Phone Number: 01717566197, E-mail Address: tisha27awmc@gmail.com

**Received Date :** 23 March, 2024

**Accepted Date :** 10 April, 2024

## Materials and Methods

The study was conducted in the Department of Anatomy, Dhaka Medical College, Dhaka, Bangladesh. The samples were collected from the Department of Anatomy, Dhaka Medical College and the students of Dhaka Medical College.

### Inclusion criteria:

- Adult left human clavicles that were fully dried and ossified.
- Clavicles that were intact and free from any signs of damage or deformity.

### Exclusion criteria:

- Clavicles showing any signs of fractures, abnormalities, or pathological conditions.
- Incomplete or poorly preserved specimens.

Most of the variables were measured with the help of a digital Vernier caliper. The maximum straight length of each Clavicle was measured from the sternal end to the acromial end. Each bone was taken and held in a horizontal position and length was measured by using a Digital Vernier Caliper and recorded in millimeters. Mid-shaft circumference of the clavicle was taken at the midpoint of the straight length of the clavicle. Then a point was marked on the superior surface of the clavicle. Perpendicularly the metallic soft wire was used to encircle the marked point around the shaft. Then the circumference was measured. The wire was straightened and measured by a digital Vernier caliper and recorded in millimeters. The straight length of the rhomboid fossa was measured by using a digital Vernier caliper and the reading was recorded in millimeters.

## Results

The present study was conducted on 120 dry ossified left human clavicles. Out of 120 (one hundred and twenty) dry clavicles, 70 (seventy) were male and 50 (fifty) were female. After the collection of data, statistical analysis was done by the software, SPSS (Statistical Package for Social Sciences) for Windows, Version 25.0. The results and observations of this study are described with suitable tables and graphs.

### Length of left clavicle

In the male, the mean  $\pm$  SD length of the clavicle was  $136.83 \pm 6.79$  mm and ranged from 121.42 mm to 154 mm. In females, the mean  $\pm$  SD length of the clavicle was  $128.36 \pm 4.43$  and ranged from 118.48 mm to 138.34 mm. The mean length of the clavicle was found to be greater

in males than in females and the difference was statistically significant ( $p < 0.001$ )

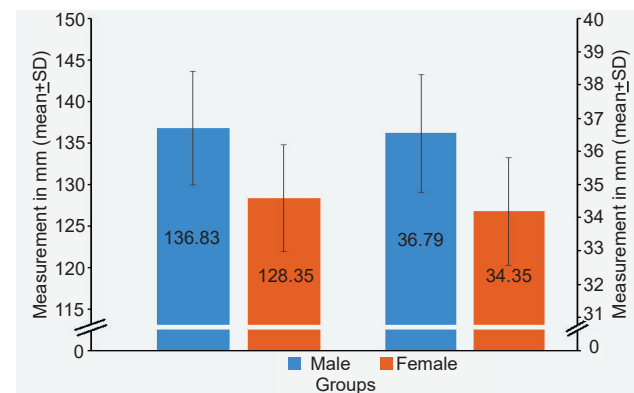
### Midclavicular circumference of left clavicle

The mean  $\pm$  SD midclavicular circumference of the clavicle was  $36.80 \pm 1.60$  mm in males and  $34.35 \pm 1.89$  mm in females respectively. The range of midclavicular circumference of the clavicle was 34 mm to 40.12 mm in males and 31.11 mm to 37.40 mm in females respectively. A significant difference ( $p < 0.001$ ) was observed in the midclavicular circumference of the clavicle between both sexes and the difference was greater in males than in females.

**Table 1: Length, midclavicular circumference of left clavicle in male and female (N = 120)**

Variables	Male n=70 Mean $\pm$ SD	Female n=50 Mean $\pm$ SD	p-value
Length of clavicle (mm)	$136.83 \pm 6.79$ (121.42-154)	$128.36 \pm 4.43$ (118.48 - 138.34)	0.000*
Midclavicular circumference (mm)	$36.80 \pm 1.60$ (34-40.12)	$34.35 \pm 1.89$ (31.11-37.40)	0.000*

Independent Sample t Test



**Figure- 1: Length and Midclavicular circumference of the left clavicle in male and female**

### Straight length of Rhomboid fossa

The mean  $\pm$  SD straight length of the Rhomboid fossa was  $21.77 \pm 5.29$  mm in males and  $19.59 \pm 5.32$  mm in females respectively. The range of straight length of the Rhomboid fossa is 13.43- 30.79 mm in males and 10.70 - 29.97 mm in females respectively. A significant difference was observed between both sexes and the difference was greater in males than in females.

**Table 2: Length of Rhomboid fossa of left clavicle in male and female (N=120)**

Variables in mm	Male n=70 Mean $\pm$ SD	Female n=50 Mean $\pm$ SD	p value
Length of Rhomboid fossa	21.77 $\pm$ 5.29 (13.43- 30.79)	19.59 $\pm$ 5.32 (10.70-29.97)	0.029*

Independent Sample t Test

**Discussion****Length of the left clavicle**

The finding of this study showed that clavicles had an average of 136.83 mm in length in males and 128.36 mm in length in females. In males, the maximum length was 154 mm, and in females, it was 118.48 mm. In the present study, the mean length of the left clavicle was significantly higher in males than in females ( $p < 0.001$ ). Similar finding was found for the population of India, Thailand, and South Africa <sup>2,10,11</sup>. In male clavicles, the difference in length is more marked rather than the females'. In this study, as sex could not be known during the collection of samples therefore it was not possible to determine the sex based on the length of the clavicle.

**Midclavicular circumference of left clavicle**

For the determination of the sex of the clavicle, among various parameters, midclavicular circumference is the most reliable indicator. From this study, I found that the average range of midclavicular circumference of the clavicle was 34 mm to 40.12 mm in males and 31.11 mm to 37.40 mm in females respectively. The mean midclavicular circumference of the left clavicle was significantly higher in males than in females. The same finding was found for the population of Thailand and India at  $p < 0.001$  level <sup>2,10</sup>. Another study also showed a similar sexual difference for the South African population <sup>11</sup>.

**Straight length of Rhomboid fossa**

In the present study, the mean straight length and breadth of the rhomboid fossa are higher in males than in females and this was statistically significant. Compared to the present study showed similarities for the Indian population <sup>12</sup>. Many factors associated with sex like genetic factors, physical activity patterns, hormonal levels, and age are likely to cause different morphological changes in the rhomboid area. Determination of the sex of the clavicle and the straight length of the rhomboid fossa as a single parameter cannot establish the sex of each clavicle.

**Conclusion**

This study provides valuable insights into morphometric features of the dry ossified left human clavicle, which can be useful in clinical and forensic applications. These findings contribute to a better understanding of clavicular anatomy and its variations, aiding in both anatomical education and medical practice.

**References**

1. Sonawane K, Dixit H, Balavenkatasubramanian J, Gurumoorthi P, Balavenkatasubramanian J. Uncovering secrets of the beauty bone: a comprehensive review of anatomy and regional anesthesia techniques of clavicle surgeries. *Open Journal of Orthopedics and Rheumatology*. 2021 Apr 10;6(1):019-029.
2. Sehrawat JS, Pathak RK. Variability in Anatomical Features of Human Clavicle: Its Forensic Anthropological and Clinical Significance. *Translational Research in Anatomy*. 2016 Jun 1; 3:5-14.
3. Sinha P, Mishra SR, Kumar P, Singh S, Sushobhana K, Passey J, Singh R. Morphometric & Topographic Study of Nutrient Foramen in Human Clavicle In India. *International Journal of Biological Medical Research*. 2015;6(3):5118-5121.
4. Ray B, Saxena A, Nayak S, Pugazhendhi B, Gayathri BM. Morphometry and Anatomical Variations of Flexor Digitorum Superficialis. *Journal of Morphological Sciences*. 2015 Jan; 32(01):008-011.
5. Sen J, Kanchan T, Ghosh A, Mondal N, Krishan K. Estimation of Sex From Index And Ring Finger Lengths In An Indigenous Population Of Eastern India. *Journal of Clinical Diagnosis Research*. 2015;9 (11): HC01-05.
6. Bilodi AK, Sinha BN, Kumaran S. Some Observation on Human Clavicle. *Journal of Nepal Medical Association*. 2002; 41:441-445.
7. Bagal G, Takale S. Sex Determination from The Clavicle. *Journal of Medical Science Clinical Research*. 2016; 4(6):11162-11165.
8. Summerhill VI, Moschetta D, Orekhov AN, Poggio P, Myasoedova VA. Sex-Specific Features of Calcific Aortic Valve Disease. *International Journal of Molecular Sciences*. 2020 Aug 6;21(16):5620.
9. Sinha SK, Dhan MR, Hayat SM, Kumar V. Morphometric Study in The Variations of Number,

- Position and Direction of Nutrient Foramen in The Clavicle. *International Journal of Anatomy Research*. 2020;8(2.1):7454.
10. Kaewma, A.; Sampanang, A; Tuamsuk, P. and Iamsaard., Morphometry of Isan-Thai Clavicles as a Guide for Sex Determination. *International Journal of Morphology*, 2017; 35(1), pp.172-177.
  11. Ishwarkumar S, Pillay P, Haffajee MR, Rennie C. Sex Determination Using Morphometric and Morphological Dimensions of The Clavicle Within the Kwazulu-Natal Population. *International Journal of Morphology*. 2016; 34(1):244-251
  12. Tragandia, M.M. and Gupta, B.D. Sex Determination Based on Morphological Study of Clavicular Rhomboid Fossa in Saurashtra Region, Gujrat., *Journal of Indian Academic Forensic Medicine*, 2020; 42(2), 93-98.