

Isolation and identification of *Aeromonas hydrophila* from silver carp and its culture environment from Mymensingh region

M. Mamnur Rashid^{1*}, M. S. Hossain² and M. F. Ali³

¹Department of Aquaculture, Bangladesh Agricultural University, Mymensingh-2202, Bangladesh, ²Fisheries Unit-1, Sherpur, C.P. Bangladesh Co. Ltd. Uttara, Dhaka and ³Department of Aquaculture, Sheikh Fajilatunnesa Mujib Fisheries College, Melandah, Jamalpur, *E-mail: mamun_aqua@yahoo.com

Abstract

The pathogenic bacteria, *Aeromonas hydrophila* from naturally infected silver carp, *Hypophthalmichthys molitrix* were isolated and identified from a fish farm in Mymensingh. Fish showed motile *Aeromonas* septicemia (MAS) like reddish head and anal region, pale body colour and external haemorrhages. Intestine, liver, kidney and environmental samples such as sediment, feed and water were inoculated onto the *Aeromonas* isolation medium (AIM) and TSA plates. The AIM colonies were undergone specific characterization for *Aeromonas hydrophila*. Quantitative studies of bacterial flora of fish on TSA plates showed that the total bacterial load in intestine, liver and kidney of the sampled fish, sediment, feed and water of the environment were 1.00×10^5 to 1.50×10^5 CFU/g, 2.7×10^2 to 4.46×10^4 CFU/g, 1.00×10^3 to 2.17×10^3 CFU/g, 1.90×10^4 CFU/g, 4.10×10^3 CFU/g and 2.50×10^3 CFU/ml, respectively. After isolation, *A. hydrophila* was finally identified by their specific morphological, physiological and biochemical characteristics. They were gram negative, rod shaped, motile bacteria that showed positive reaction for oxidase and catalase, fermented glucose and were resistant to vibriostatic agent O/129. They showed positive result in esculin hydrolysis test.

Keywords: *Aeromonas hydrophila*, Silver carp, *Hypophthalmichthys molitrix*, MAS

Introduction

With intensive aquaculture practices, the exotic silver carp, *Hypophthalmichthys molitrix*, has become a main culture species of Bangladeshi farmers. A specific disease condition, clinically presented by fin rot, redness on head, enlargement of lower lip and swollen abdomen resulted in high mortality of fish which has frequently been encountered in many farms of Mymensingh region (unpublished data). *Aeromonas* and *Pseudomonas* are the important bacterial pathogens frequently isolated from the diseased fishes throughout the world as well as Bangladesh. Bacterial fish diseases, especially bacterial hemorrhagic septicemia (Roberts *et al.*, 1989) and motile *Aeromonas* septicemia in freshwater fish caused great losses (Lio-po *et al.*, 1992). In Bangladesh, aeromonads were frequently observed in farmed fishes as well as in the natural waterbodies (Iqbal *et al.*, 1996). Sabur (2006) isolated the pathogenic bacteria *Aeromonas hydrophila* in indigenous and exotic carps under their polyculture conditions. Mamnur Rashid *et al.* (2008) isolated *A. hydrophila* from the suspected EUS-affected shing fish, *Heteropneustes fossilis*. Hasan *et al.* (2008) observed histopathological changes in intestine, liver and kidney of the affected fish. Ahmed (2009) isolated and identified *A. hydrophila* from carps, catfishes, perches and eel and found that they were highly pathogenic. Saeed (2010) isolated and identified bacteria from naturally infected eight fish species: rui (*Labeo rohita*), catla (*Catla catla*), mrigal (*Cirrhinas cirrhosus*), tilapia (*Tilapia mossambicus*), tarabaim (*Macrornathus aculeatus*), koi (*Anabas testudineus*), shing (*Heteropneustes fossilis*), and magur (*Clarias batracus*) from different area of Mymensingh District. Recently, a silver carp fish farm in Mymensingh was reported to have diseased condition under culture. So, the present work was undertaken to identify the disease condition and the associated pathogen.

Materials and Methods

Diseased as well as apparently healthy fish were sampled. Environmental water, sediment and feed were also collected from the farm. Trypton soya agar (TSA, Oxoid) plates were used for total bacterial count and AIM, for isolation of *Aeromonas* like bacteria. TSA slants were used for stocking *Aeromonas* bacteria for further studies.

Bacteriological investigation

The external lesions were plated onto the TSA and AIM plates. Decimal dilutions of intestine, liver and kidney samples were inoculated onto duplicate TSA plates for total bacterial count and onto AIM plates for specific *Aeromonas* isolation. All the plates were incubated at 25°C for 48 hrs for colony appearances.

Identification of *Aeromonas* bacteria

All the grown colonies of *Aeromonas* like bacteria from the streaked and spreaded plates of AIM were sub cultured onto TSA plates to obtain fresh 24 hrs culture and then undergone morphological characterization such as shape, size, Gram character, flagellation and motility test. Biochemical characters such as oxidase, catalase, oxidative-fermentative (OF), acid and gas production from sugars (glucose, lactose, maltose, sucrose and manitol), methyl-red, H₂S production, Voges-proskauer (VP), arginine hydrolysis, esculin hydrolysis and O/129 test were done to confirm their generic and specific natures. Physiological characters were studied by observing the growth of each isolate at temperatures of 4, 37 and 40°C in different concentrations of NaCl as 0, 1, 2, 3.5 and 4% to confirm the identification of the *A. hydrophila* bacteria.

Results

Clinical pathology

Naturally infected silver carp fish lost their normal appearance. Fish showed reddish head and anal region, pale body colour, external ulcerative lesions with haemorrhage and reddened fin bases (Fig. 1). Moribund fish were found to swim abnormally at water surface.

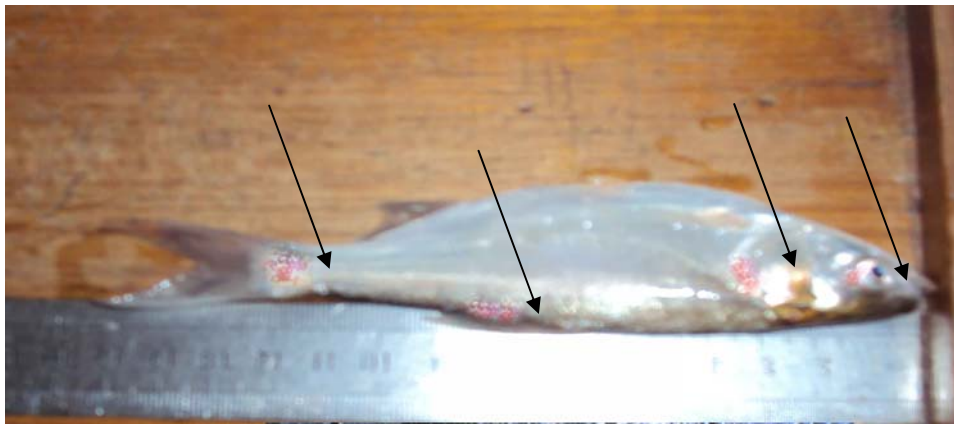


Fig. 1. External haemorrhagic lesions in sampled silver carp

Characteristics of isolated *Aeromonas* bacteria

Spreaded and streaked plates with AIM showed growth of *Aeromonas* bacteria which primarily conferred that the bacteria associated with the ulcerative lesions on silver carp. The isolates gave rise to yellowish opaque colonies on TSA agar. The colonies were smooth, raised and round in shape. The results of their comparative morphological, biochemical and physiological tests with those of Popoff (1984) are shown in Table 1. On the basis of their growth in Vibriostatic agent O/129 the present isolates were confirmed to be *Aeromonas* sp., and on the basis of their esculin hydrolysis characters they were confirmed to be *A. hydrophila*.

Total bacterial load

Total bacterial load found in intestine, liver and kidney of the sampled fish, water, sediment and feed are shown in Table 2.

Table 1. Characteristics of *Aeromonas hydrophila* isolates in comparison to those shown by Popoff (1984)

Characters	Popoff (1984)	Present Isolates
Gram stain	-	-
Motility	+	+
Shape	Rod	Rod
Oxidase	+	+
Catalase	+	+
OF test	Fermentative	Fermentative
Acid and gas production from sugar	Dextrose	+
	Sucrose	+
	Maltose	+
Acid production	Lactose	+
	Manitol	+
Voges-proskauer	+	+
H ₂ S production	+	+
Methyl red test	-	-
Growth in Vibriostatic agent 0/129	+	+
Esculin hydrolysis	+	+
Growth at	4°C	-
	37°C	+
	40°C	-
Growth in NaCl solution	0%	+
	1%	+
	2%	+
	3.5%	-
	4%	-

Table 2. Total bacterial load in different samples of silver carp and its environment

Organ/ sample	Total bacterial load
Intestine	1.0 ~ 1.5 × 10 ⁵ CFU/g
Liver	2.7 × 10 ² ~ 4.5 × 10 ⁴ CFU/g
Kidney	1.0 ~ 2.2 × 10 ³ CFU/g
Water	2.5 × 10 ³ CFU/ml
Sediment	1.9 × 10 ⁴ CFU/g
Feed	4.1 × 10 ³ CFU/g

Discussion

In the present study, reddish head and anal region, pale body colour, external ulcerative lesions on body surface with haemorrhage, skin erosion and reddened fin bases were found from motile *Aeromonas* septicemia (MAS) like diseased silver carp *H. molitrix* in Mymensingh. This was a pioneer work in Bangladesh to isolate *A. hydrophila* from infected silver carp showing MAS like ulcerative and haemorrhagic lesions. Infected silver carp lost their normal appearance, formed pale body colour and showed abnormal swimming behavior. Mamnur Rashid *et al.* (2008) found similar clinical symptoms in EUS like diseased stinging catfish, *Heteropneustes fossilis* infected by *Aeromonas hydrophila*. The present isolates were Gram negative, produced acid and gas from glucose, resistant to vibriostatic agent 0/129 and hydrolyzed esculin. Ahmed (2009) confirmed *A. hydrophila* on the basis of the above characters. Total bacterial load found in intestine, liver and kidney of the sampled fish were 1.0 × 10⁵ to 1.5 × 10⁵ CFU/g, 2.7 × 10² to 4.5 × 10⁴ CFU/g and 1.0 × 10³ to 2.2 × 10³ CFU/g, respectively. In water,

sediment and feed of the environment, the loads were 2.5×10^3 CFU/ml, 1.9×10^4 CFU/g and 4.1×10^3 CFU/g, respectively. Alam (2009) isolated *Aeromonas hydrophila* from Thai pangus. He found the bacterial load to be 4.8×10^6 to 7.2×10^7 CFU/g in intestine, 2.6×10^6 CFU/g in liver and 2.4×10^3 to 3.70×10^6 CFU/g in kidney. Mamnur Rashid *et al.* (2008) found 1.47×10^4 to 3.70×10^8 CFU/g, 1.67×10^4 to 6.4×10^8 CFU/g and 1.71×10^3 to 1.18×10^9 CFU/g of bacteria in intestine, liver and kidney of naturally infected Thai pangus, respectively. Mostofa *et al.* (2008) isolated *Aeromonas hydrophila* from *Heteropneustes fossilis*. They found highest bacterial load to be 2.4×10^7 CFU/g from liver and the lowest, 2.1×10^2 CFU/g from kidney. Hasan (2007) isolated and identified *Aeromonas* isolates from five apparently healthy indigenous and exotic carps: rui (*Labeo rohita*), catla (*Catla catla*), mrigal (*Cirrhinus cirrhosus*), and common carp (*Cyprinus carpio*). Iqbal *et al.* (1996) found total bacterial load to be 5.4×10^3 to 4.7×10^7 CFU/g in slime and undetectable to 1.7×10^4 CFU/g in kidney of *Cirrhinus mirgala*.

Conclusion

As *Aeromonas hydrophila* is an ubiquitous bacterial pathogen it might cause serious losses to the intensive culture system of Bangladesh. So, the higher loads of *A. hydrophila* in different organs of MAS affected silver carp fish, sediment, feed and water of the environment strongly supported the ubiquitousness of the bacteria in Mymensingh region of Bangladesh. So, it may be concluded that culturists should take proper management practices to avoid such disease of culture fishes especially silver carp and to get rid of the infection by such serious bacterial pathogen like *Aeromonas hydrophila* by improving their culture strategy and culture ecosystem.

References

- Ahmed, M.B. 2009. Isolation and identification of *Aeromonas hydrophila* from carps, perch and catfishes. M.S. Thesis, Department of Aquaculture, Bangladesh Agricultural University, Mymensingh.
- Alam, K. 2009. Isolation of *Aeromonas hydrophila* from naturally diseased Thai-pangas *Pangasius hypophthalmus*. M.S. Thesis, Department of Aquaculture, Bangladesh Agricultural University, Mymensingh.
- Hasan, M.A. 2007. Pathogenicity of *Aeromonas hydrophila* in EUS like disease affected *Heteropneustes fossilis*. M. S. Thesis, Department of Aquaculture, BAU, Mymensingh.
- Hasan, M.A., Mamnur Rashid, M., Islam, M.A., Mostafa K. and Islam, M.T. 2008. Histopathological studies of EUS affected shing *Heteropneustes fossilis* from a fish farm of Mymensingh. *Bangladesh J. Fish. Res.*, 12(1): 21-26.
- Iqbal, M.M., Chowdhury, M.B.R., Uddin, M.N. and Rahman, M.M. 1996. Studies on the bacterial flora in the slime and kidney of a farmed fish, *Cirrhinus mirgala*. *Bangladesh J. Fish.*, 19(1-2): 87-93.
- Lio-Po, G. D., Albright, L. J. and Alapide-Tendencia, E.V. 1992. *Aeromonas hydrophila* in the Epizootic Ulcerative Syndrome EUS of Snakehead (*Ophiocephalus striatus*) and catfish (*Clarias batrachus*): Quantitative estimation in Natural Infection and Experimental Induction of Dermomuscular Necrotic Lesion. In: Woo, P.T.K., Bruno, D.W. and Lim, L.H.S. 2002. Disease and disorders of finfish in cage culture. pp.354.
- Mamnur Rashid, M., Hasan, M.A., Mostafa, K. and Islam, M.A. 2008. Isolation of *Aeromonas hydrophila* from EUS affected shing *Heteropneustes fossilis* from a fish farm of Mymensingh. *Progress. Agric.*, 19 (1): 117-124.
- Mostafa, K., Islam, T., Sabur, M. A. and Mamnur Rashid, M. 2008. Experimental pathogenesis of *Aeromonas hydrophila* bacteria in shing *Heteropneustes fossilis* (Bloch). *Bangladesh J. Fish. Res.*, 12 (1): 27 - 33.
- Popoff, M. 1984. Genus III. *Aeromonas* Kluyver and Van Niel 1936, 398^{AL}. In: Bergey's manual of systematic bacteriology, vol. 1, (eds.) Krieg, N. R. and J. G. Holt. Williams and Wilkins, Baltimore, MD. pp. 545-548.
- Roberts, R.J., Wotten, R., Macrae, I., Millar, S.D. and Struthers, W. 1989. Ulcerative disease survey, Bangladesh. Final to government of Bangladesh and the Overseas Development Administration. Institute of Aquaculture, Starling University, Scotland. pp. 136.
- Sabur, M.A. 2006. Studies on the ecology of the pathogenic bacteria *Aeromonas hydrophila* in indigenous and exotic carps under polyculture condition. Ph. D. Dissertation, Department of Aquaculture, Bangladesh Agricultural University, Mymensingh.
- Saeed, M.A. 2010. Isolation and identification of *Aeromonas hydrophila* bacteria from indigenous koi (*Anabus testudineus*). M.S. Thesis, Department of Aquaculture, Bangladesh Agricultural University, Mymensingh.