



ISSN 1810-3030 (Print) 2408-8684 (Online)

Journal of Bangladesh Agricultural University

Journal home page: <http://baures.bau.edu.bd/jbau>, www.banglajol.info/index.php/JBAU

Therapeutic potentialities of green tea (*Camellia sinensis*) and aloe vera (*Aloe barbadensis*) on *Staphylococcus aureus* induced septic wound in goats

Sumaia Jahan Tamanna¹, Moktadin Md. Shihab², Mst. Antora Akter³, Marzia Rahman⁴,
Md. Mahmudul Alam³✉

¹Department of Microbiology, Kyungpook National University School of Medicine, Daegu, South Korea

²Department of Biochemistry and Cell Biology, Kyungpook National University School of Medicine, Daegu, South Korea

³Department of Surgery and Obstetrics, Bangladesh Agricultural University, Mymensingh 2202, Bangladesh

⁴Department of Microbiology and Hygiene, Bangladesh Agricultural University, Mymensingh 2202, Bangladesh

ARTICLE INFO

Article history:

Received: 14 December 2019

Accepted: 01 January 2020

Published: 31 March 2020

Keywords:

Green tea,
Aloe vera,
Staphylococcus aureus,
Wound

Correspondence:

Md. Mahmudul Alam

✉: mahmuddso2004@gmail.com



ABSTRACT

The research has been conducted in Black Bengal goats to determine the therapeutic efficacy of aloe vera and green tea extract on the healing of *Staphylococcus aureus* induced septic wound. A total 18 surgical wounds were made in goats under three groups; aqueous paste of aloe vera (Group-A), alcoholic extract of green tea (Group-B) and normal saline (as control, Group-C). Each wound was 20 mm length and 5 mm depth. Wound was remained open and 0.5 ml medium (10^7 /ml) containing *Staphylococcus aureus* was inoculated in each wound. After 72 hours of bacterial inoculation treatment was started. Freshly prepared aloe vera paste and alcoholic extract of green tea was applied once daily onto the wound in group A and B respectively. Similar action was taken in Group-C with normal saline only. Follow up information was recorded from day 0 to day 21 postoperatively. Some morphological characters such as swelling, wound gap and length of wound were observed. Highest wound gap (5.18 ± 0.32 mm) was observed in wounds of control animals where it was lowest (4.63 ± 0.14 mm) in those treated with extract of green tea. Length of wound was also highest (13.74 ± 0.38 mm) in control group and lowest (12.62 ± 0.17 mm) in green tea treated group. All wounds were regularly monitored to observe the complications like swelling, edema, wound dehiscence, wound abscess, local infection and exudation surrounding the wounds. Mean days to heal completely were 15 days for aloe vera, 13 days for green tea and in control group it took 20 days to achieve similar results. Bacteriological studies revealed presence of higher bacterial load in the control group than the other two groups which is responsible for delayed healing. Our results showed that *Staphylococcus aureus* induced wound healing was prompted by the topical use of both green tea and aloe vera but green tea extract was more effective than aloe vera. Therefore, it can be suggested that alcoholic extract of green tea and aqueous extract of aloe vera could be good alternative to antibiotic for the treatment of *Staphylococcal* wound in goat.

Copyright ©2020 by authors and BAURES. This work is licensed under the Creative Commons Attribution International License (CC By 4.0).

Introduction

In livestock sector, goat population plays an important role in the economy of Bangladesh. Veterinary practitioners and farmers mostly concentrated in goat as they are appreciated as one of the major sources of foods of animal origin including milk, meat and milk products and high quality skin (Mantle *et al.*, 2001). In spite of advances in controlling the infection of surgical wounds, bacterial wound contamination is still remains the most common post-operative complication (Emami *et al.*, 2012). Various bacterial species isolated from wounds, but *Staphylococcus aureus* is the most frequent organism responsible for wound infection. Due to resistance against common antibiotics and its high prevalence, it seems that this bacterium is the best indicator for evaluation of the prevention and treatment infection in wounds. In the developing countries people mostly depend on herbal medical cure. Traditional medicine has been virtually used in preventing and curing diseases,

thereby playing an important role in the health service in the region especially among the low social-economic class. These herbs are mostly administered topically as ointment on wounds and abrasion. Extracts of roots, stem bark and leaves of some medicinal plants have been known to have effects against the most dreaded pathogenic organisms like bacteria, fungi, viruses (Russel *et al.*, 1997) and also some others still serve as liver tonic (Crescent, 2009). Based on the usage of natural products in traditional medicine, a large number of modern medicines have been extracted from natural sources. There are lots of synthetic and natural drugs which come forward to mitigate the wound healing. Green tea (*Camellia sinensis*) which is a product of dried leaves has been consumed by East Asian people for health promotion since 3000 B.C. (Kim *et al.*, 2008a). Abundantly found in Asia, green tea is also one of the most prevalent drinks worldwide (Park *et al.*, 2008). Extracts of leaves from the green tea plant (*Camellia sinensis*) contain polyphenolic components with activity against a wide spectrum of microbes. Studies conducted

Cite this article

Tamanna, S.J., Shihab, M.M., Akter, M.A., Rahman, M., Alam, M.M. 2020. Therapeutic potentialities of green tea (*Camellia sinensis*) and aloe vera (*Aloe barbadensis*) on *Staphylococcus aureus* induced septic wound in goats. *Journal of Bangladesh Agricultural University*, 18(1): 105–110. <https://doi.org/10.5455/JBAU.94746>

over the last 20 years have shown that the green tea polyphenolic catechins, in particular epigallocatechin gallate (EGCg) and epicatechin gallate (ECg), can inhibit the growth of a wide range of Gram-positive and Gram-negative bacterial species with moderate potency (McKay and Blumberg, 2002). Aloe vera plants are available in our country and extract preparation is easy. Aloe vera (*Aloe vera* L, *Aloe barbadensis*) is a well-known medical plant with historical records for its unique properties such as anti-inflammatory, anti-oxidant, wound healing promoting, immunomodulatory (Cuttle *et al.*, 2008). Aloe vera gel also has an antibacterial effect against a broad range of bacteria including *S. aureus*, (Cock *et al.*, 2000). It is also reported that aloe vera gel not only speeds up healing but also prevents injured surface from getting infected (Chithra *et al.*, 1998). Aloe vera also minimizes demand of other drugs and their side effects (Ahmada *et al.*, 2016). A lot of works have been reported on use of plant extract for the treatment of aseptic surgical wound (Alam *et al.*, 2005; Mia *et al.*, 2017) but to the best of our knowledge no work has been reported on the use of herbs extract for the treatment of septic wounds. Therefore, the present research work has been implemented to evaluate the therapeutic efficacy of green tea and aloe vera on *Staphylococcus aureus* induced septic wounds in goats and to study the morphological and bacteriological changes of wound during healing process after topical application of green tea and aloe vera.

Materials and Methods

Animals

The animal experimentation has been performed with the approval and following the guidelines and recommendations of Animal Experimental Ethics Committee (AEEC), Department of Surgery and Obstetrics, Faculty of Veterinary Science, Bangladesh Agricultural University, Six apparently healthy goats having body weight of 8 to 10 kg were used for this experiment. The experimental animals were purchased from the local market. The animals were kept under standard conditions and veterinary supervision at the Veterinary Teaching Hospital (VTH) with no restrictions on water and food. Before the study the goats were kept in quarantine for two weeks. The animals were vaccinated with PPR (P.P.R vaccine@ LRI, Bangladesh) and dewormed with anthelmintics (Endex®, Novartis pharmaceuticals, Bangladesh, Ltd).

Preparation of extract

Aloe vera leaves were collected from Ganginar Par market, Mymensingh town and the rinds were removed. To make the gel thicker, the plant's leaves were allowed to dry up in room temperature without exposure to direct sunlight. The leaves were then grinded in a blender and centrifuged at 10,000 rpm to remove the fibers and filtered through filter papers. The filtered extract was stored at +4°C. The paste was allowed to warm up to room temperature before applying to the wounds. Green

Tea was collected from Kamal-Ronjit (KR) market, Bangladesh Agricultural University, Mymensingh. Twenty gram Green Tea was measured with precise electric balance and it was taken in a thimble of soxhlet apparatus. Then 200 ml absolute ethanol was poured in a boiling flask of soxhlet apparatus. Within 30 minutes the green tea extract was prepared and collected into petridishes and kept overnight for evaporation of remaining alcohol. The next day green Tea extract was found in paste form. Green tea extract was always used as freshly prepared paste.

Experimental design

A total of 18 full thickness (FT) open surgical wounds were made on the either side of vertebral column of goats. Goats were divided into three groups.

Group-A: Fresh Aloe vera extract was applied locally once daily to six surgical wounds made in two animals. The animals were maintained carefully so as to avoid contamination and interference with healing.

Group-B: Fresh Green Tea extract was applied locally once daily to six surgical wounds made in two animals. The treatment schedule was same as in Group-A.

Group-C: This group was kept as control. In this group normal saline was applied in six surgical wounds in two animals (Table 1).

Table 1. Therapeutic strategy in the current study

Groups	Therapeutic agent	Form of agents	No. of animals	No. of wounds
A	Aloe vera	Aqueous Extract	2	6
B	Green Tea	Alcoholic Extract	2	6
C	Control (Normal Saline)	0.85%Nacl in H ₂ O	2	6

All wounds were remained uncovered. Similarly, antibiotic, antihistaminic or anti-inflammatory drugs were avoided to mitigate their effects on healing process. Follow-up information was obtained since day of surgical operation up to day 21 after surgery. Some morphological characters such as swelling of wound area, width of wound, length of wound area were recorded to determine the healing of wounds. Width of suture area was measured on day 1 (D1), day 3 (D3), day 7 (D7), day 14 (D14), day 21 (D21). For bacteriological study, swab samples were collected from all groups at day 3 (D3), day 6 (D6), day 10 (D10).

Wound creation

Clinical examination was performed to ensure that the animal was good enough physically and apparently free from infections or infestation. The operation sites (either side of vertebral column) were clipped, shaved and painted with Povidone Iodine (Povisep®, Beximco Pharmaceuticals, Bangladesh). The goats were positioned on lateral recumbency. Infiltration of anesthesia was performed at the site of incision using 2% Lidocaine Hydrochloride (Jasocaine®, Jayson Pharmaceuticals, Bangladesh). Surgical wound was made by giving a vertical incision on either side of

vertebral column wound, each was 20 mm length and 5 mm depth. Blood was cleaned with clean dry gauze and cotton. Skin was separated from underlying tissues by blunt dissection. Distance between needle placement and border of cutting edge was 5 mm. Wound was remained open and 0.5 ml fluid (10^7 /ml) containing *Staphylococcus aureus* was spread in each wound. Then the wounds were covered with sterile vaseline gauze.

Post-operative care

After wounds creation, the wounded area was kept intact until 72 hours except dressing of wound with sterile vaseline gauze. After 72 hours aloe vera and green tea was applied once daily onto the wounded area of the animals of A and B group. Insect repellent spray was also used. Feed was not withheld following dressing. These animals were maintained carefully so as to prevent contamination.

Treatment of wounds, observation and data collection

Slide Calipers was used to measure the swelling area (mm), width of wound and length of (mm) of wound. All wounds were closely monitored daily to observe any complication such as swelling (mm), wound dehiscence and local infection exudation. The progress of healing in animals of each group was monitored daily. Healing score was categorized as:

Excellent- No inflammation, no exudation, no infection, no dehiscence, gradual decreasing of width of wound area.

Good- minimum inflammation with minimum exudation, no dehiscence, gradual decreasing of width of wound area.

Fair- marked inflammation, presence of infection and exudation.

Bacteriological Study

Collection of samples

All of the samples were collected aseptically from the wound of goat by using sterile cotton buds. Before using, it was soaked with saline solution and swab sample was collected by circling the cotton bud onto the wound. Then the cotton buds were quickly transferred into screwed capped test tubes containing nutrient broth. In this way 3rd, 6th and 10th day samples were collected.

Culture of bacteriological samples

The collected samples were inoculated in nutrient agar and ten-fold serial dilution was performed. A ten-fold dilution reduces the concentration of a solution or a suspension of virus by a factor of ten that is to one-tenth the original concentration. They were carried out in small sterile test tubes. Finally, the diluted solution was spreaded into Mannitol Salt Agar (MSA, HiMedia, India) and Plate Count Agar (PCA, HiMedia, India).

Plates were then incubated at 37°C overnight to promote growth of bacteria. Colony Forming Units (CFU) were calculated the next day.

Bacterial load count

A preliminary count of each dish was performed once the bacteria incubates. Only individual colonies were counted, which were distinct, isolated dots, not a whole blob of different colonies grown together. The plate which has more than 30 of these colonies but less than 300 was chosen. The number of individual colonies was counted. This was the CFU number of dilution, then a simple calculation was performed to determine the CFU of the original sample.

Statistical analysis

All the data were expressed as Mean \pm SEM (Standard Error of Mean). To compare data among groups one way ANOVA (Analysis of variance) factor analysis was performed and subjected to statistical analysis using Statistical Package for the Social Sciences (SPSS) version 20.0. Probability $P < 0.05$ was considered statistically significant.

Results

Eighteen incised full thickness skin wounds were made and treated with aqueous extract of aloe vera (group A), alcoholic extract of green tea (group B) and Normal saline (control, group C) to evaluate their healing efficacy on *Staphylococcus aureus* effect in goats. Morphological changes such as swelling, wound gap and length of wounds, bacterial loading count and the period of healing were studied.

Morphological changes

Swelling area, wound gap, length of wounds were evaluated postoperatively to compare effects of three treatments on wound healing (Fig. 1-3). Swelling of the wound edges was observed up to 3 days after operation as swelling decreased gradually. Table 2 shows that there is no significant difference among the groups in case of swelling of wound edges because treatment is given from the 3rd day. Wound gap varied significantly ($p < 0.05$) with treatment. Among three groups group- B presented the lowest (4.63 ± 0.14) measurement which indicated fast healing. Post operatively the length of the wound decreases gradually depending on the treatment. In this study group-B which was treated with Green Tea extract showed the lowest length (12.62 ± 0.17) of wound that is significantly different from the control group (13.74 ± 0.38). Among three groups higher wound gap and length of wound area were observed in wounds of control group where wounds treated with 0.85% Normal Saline in comparison to those treated with green tea and aloe vera extract (Table 2).

Potentialities of green tea and aloe vera against septic wound in goats

Days to healing

In this study, there were significant differences on the healing time among the groups. The mean days to complete healing for the treatment groups ranged from 15 days for Aloe vera extract (Group A), 13 days for Green tea extract (Group-B) and 20 days for control group (Group-C).

Bacteriological findings

Wound swab samples were spreaded on the Plate Count Agar (PCA) plates after dilution and incubated overnight at 37°C temperature. The next day cultural characteristics and growth of bacteria were observed. Determination of viable bacteria was performed by counting of *Staphylococcus aureus* colonies after 24 hours of incubation period in plates with colonies among 30 to 300 (Table 3). The CFU of bacteria significantly decreased after use of aloe vera in induced experimentally septic wound. In our study, bacterial colonies and load count (8×10^8 CFU/ml) were more or less similar at day 3 (Fig. 4). After being treated bacterial load counts were reduced in both group A

(7×10^3 CFU/ml) and group C (3.7×10^7 CFU/ml) at day 6 ((Fig. 4) whereas on that day the culture media of green tea treated wound sample showed only less than 30 bacteria which was avoided. Because, determination of viable bacteria was performed by counting of bacterial colonies after 24 hours of incubation period in plates with colonies among 30 to 300. Finally, at day 10 only control animals treated with 0.9% Normal Saline showed bacterial existence (1.25×10^5 CFU/ml), meanwhile aloe vera extract and green tea extract made the wounds bacteria free and fasten the wound healing process. (Table 4, Fig. 5, Fig. 6).

Table 2. The effects of Aloe vera extract, Green tea extract and Normal Saline on wound healing in goats

Groups	Swelling of wounds (mm)	Wound gap (mm)	Wound length (mm)	Healing time (days)
Group A	7.73 ± 0.20 ^a	5.03 ± 0.21 ^a	12.80 ± 0.23 ^a	15.17 ± 0.31 ^a
Group B	7.55 ± 0.06 ^a	4.63 ± 0.14 ^a	12.62 ± 0.17 ^a	13.83 ± 0.48 ^b
Group C	8.02 ± 0.20 ^a	5.18 ± 0.32 ^a	13.74 ± 0.38 ^b	20.50 ± 0.43 ^c

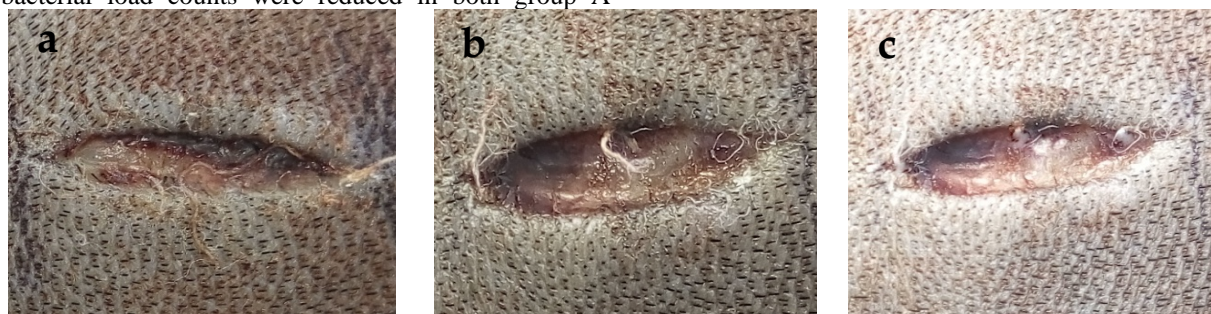


Fig. 1. Wound at day 1 after inoculation of *Staphylococcus aureus* in all three groups.

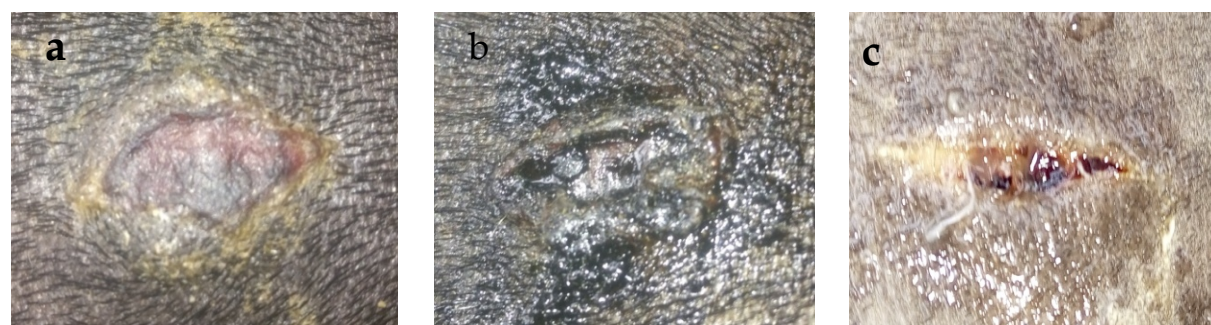


Fig. 2. Gross observation of wound healing at day 7 in aloe vera (a), green tea (b) and normal saline (c)

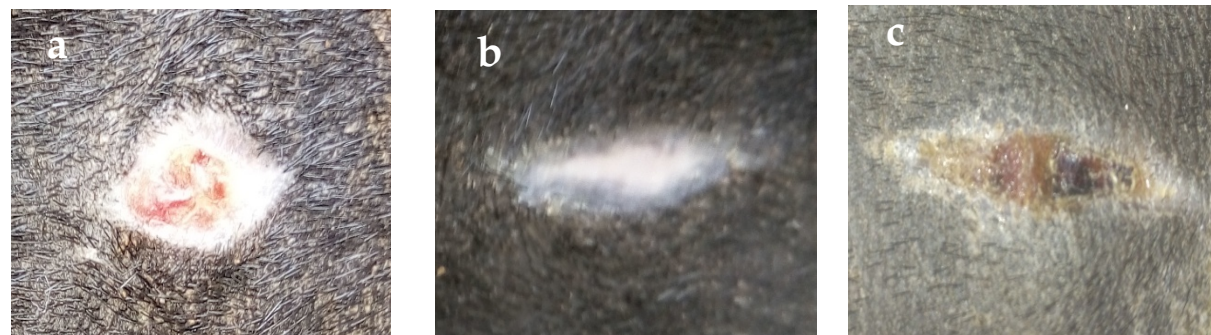


Fig. 3. Gross observation of wound healing at day 14 in (a) aloe vera, (b) green tea, and (c) normal saline

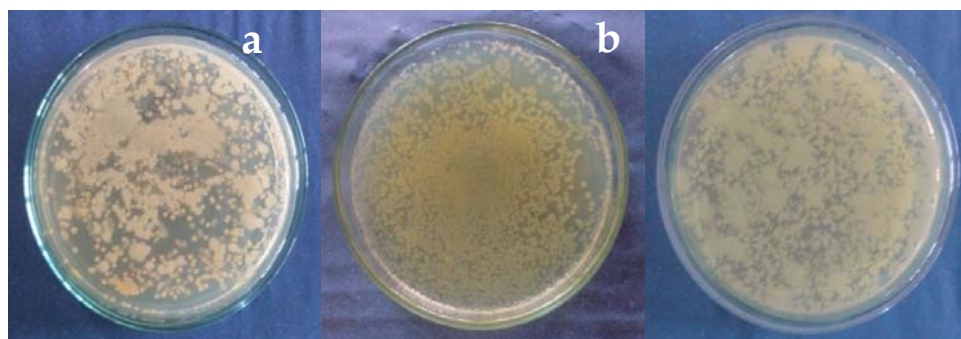


Fig. 4. Determination of bacterial load in Plate Count Agar media at day 3 after commencement of treatment in Plate Count Agar media. (a) aloe vera, (b) green tea, (c) saline treated control.

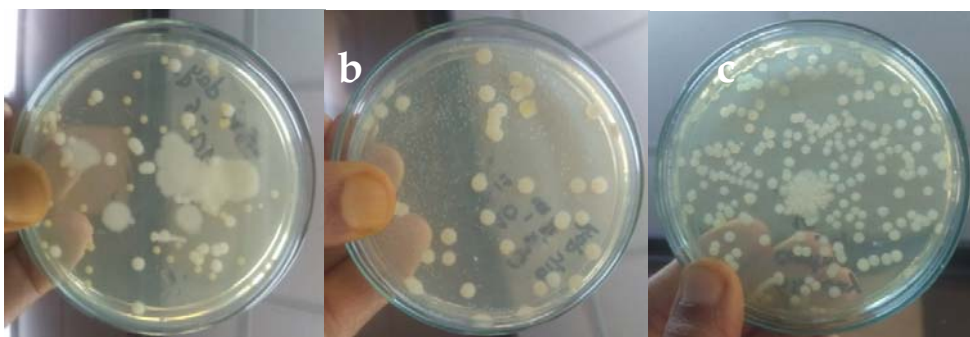


Fig. 5. Determination of bacterial load in Plate Count Agar media after 6 days of treatment in (a) aloe vera, (b) green tea, (c) saline treated control

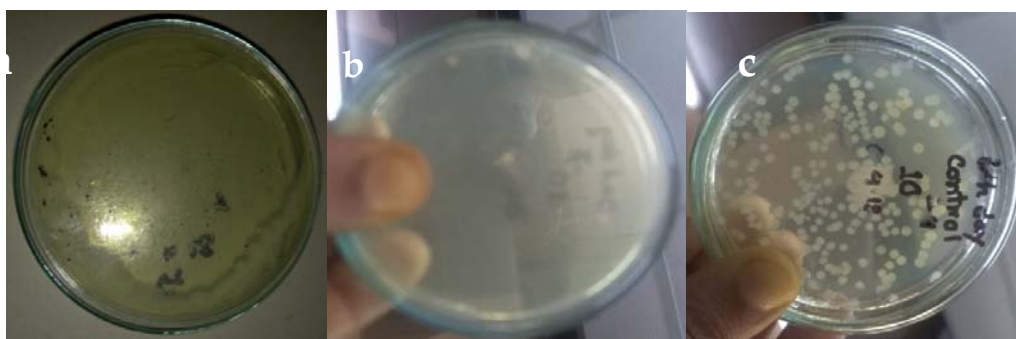

Fig. 6. Determination of bacterial load in Plate Count Agar media after 10 days of treatment in Plate Count Agar media (a) aloe vera, (b) green tea, (c) saline treated control

Table 3. Results of bacterial loads on Mannitol Salt Agar (MSA)

Days	Group A	Group B	Group C
3rd day	+ ve	+ ve	+ ve
6th day	+ ve	-ve	+ ve
10th day	- ve	- ve	+ ve

Table 4. Results of total viable count (TVC) of bacteria in wounds of goat treated with Aloe vera (group A), Green Tea (group B), Control (group C) at different days of interval.

Days	Group A (CFU/ml)	Group B (CFU/ml)	Group C (CFU/ml)
3 rd	8×10^8	8×10^8	8×10^8
6 th	7×10^3	0 (No growth)	3.7×10^7
10 th	0 (No growth)	0 (No growth)	1.25×10^5

Discussion

The major bioactive components of green tea, the catechins, possess antibacterial activity and find utility in the treatment of topical and oral infections. There is unanimity that extracts of green tea possess modest antibacterial activity and staphylococci including the important nosocomial pathogen, methicillin-resistant *Staphylococcus aureus* (MRSA) (Hara, 2001). There is good evidence that the catechin components of green tea are responsible for the observed antibacterial activity, and that EGC, EGCg and ECg constitute the most important antibacterial agents (Hara, 2001). For example, Stapleton *et al.* (2004) examined the anti-MRSA properties of a range of naturally occurring and semi-synthetic catechins and catechin gallates. On the

other hand, Mannose-6-Phosphate has been introduced as the active part of aloe vera responsible in wound healing (Davis *et al.*, 1994). This substance also contains enzymes, glycoproteins, growth factors, vitamins and minerals that have been shown to improve healing with enhanced epithelialization and rapid formation and maturation of granulation tissue in burn wounds. In this study, on the basis of bacteriological changes green tea extract performs better than aloe vera extract.

There are many risk factors for the development of postoperative wound complications in veterinary medicine. Proper aseptic technique, hypothermia, duration of anesthesia and the degree of postoperative care affect healing and local and general factors must be considered during postoperative treatment. In this study, no negative effect from either aloe vera extract or green tea extract was observed. It is believed that, either the aloe vera extract or green tea extract can be used clinically in any situation of wound healing. In another study, it was found that application of green tea (*Camellia sinensis*) extract shortens the inflammation period, in order to shorten the healing time (Fatemeh *et al.*, 2013). Average healing time of our study was 13 days, 15 days and 20 days in aloe vera, green tea and control respectively. So can say that, application of green tea extract for wound healing is comparatively better than other group. There was early subsidence of inflammation, better control of infection and quicker wound healing in green tea extract treated wound compared to the other two groups. Based on the findings of morphology and bacterial analysis, it can be recommended that green tea extract may be a practical choice for septic wound care and makes the wound sterile. There were some limitations in this study. For vertical research, histopathology, immunohistochemistry for inflammatory cellular infiltration should be done.

Conclusion

Based on morphological and bacteriological evaluation it can be concluded that herbal extract like green tea and aloe vera is highly effective against *Staphylococcus aureus* induced septic wound. Among these two herbs green tea proved better in healing and reducing bacterial load from infected wound. Therapeutic application of green tea and aloe vera may be good alternatives to systemic antibiotic for the treatment of infected wound.

References

Alam MM, Islam SA, Mohammad Y, Juyena NS, Hashim MA 2005. Comparative Efficacy of Two Medicinal Plant Extracts and an Antibiotic on Wound Healing.

Chithra P, Sajithlal GB, Chandrakasan G 1998. Influence of Aloe vera on the healing of dermal wounds in diabetic rats. *Journal of Ethnopharmacology*, 59: 195-201.
[https://doi.org/10.1016/S0378-8741\(97\)00124-4](https://doi.org/10.1016/S0378-8741(97)00124-4)

Crescent Bloo 2009. Medicinal action of common plants.

Cuttle L, Kempf M, Kravchuk O 2008. The Efficacy of Aloe vera, Tea tree Oil and saliva as first aid treatment for partial thickness burn injuries. *Burns*, 34 (8):1176-1182.
<https://doi.org/10.1016/j.burns.2008.03.012>

Davis RH, Donato JJ, Hartman GM and Haas RC 1994. Anti-inflammatory and wound healing activity of a growth substance in Aloe vera. *Journal of American Podiatric Medical Association*, 84: 77-81.nce 14: 11011-11023
<https://doi.org/10.7547/87507315-84-2-77>

Fatemeh H, Kanthimathi MS, Abdullah, Sanusi J 2013. The Effect of *Camellia sinensis* on Wound Healing Potential in an Animal Model. *Evidence based Complementary and Alternative Medicine* ,387-734.
<https://doi.org/10.1155/2013/386734>

Mantle D, Gok MA, and Lennard 2001. Adverse and beneficial effects of plant extracts on skin and skin disorders. *Adverse Drug Reactions and Toxicological Reviews* , 20(2): 89-103.

McKay DL and Blumberg JB 2002. The role of tea in human health. *Journal of the American College of Nutrition*, 21:1-13.
<https://doi.org/10.1080/07315724.2002.10719187>

Hara Y 2001. Green tea: health benefits and applications. New York, USA: Marcel Dekker.
<https://doi.org/10.1201/9780203907993>

Ahmada M, Khana Z, Mukhtara A, Zafara M, Sultana S, Jahanb S 2016. Ethnopharmacological survey on medicinal plants used in herbal drinks among the traditional communities of Pakistan. *Journal of Ethnopharmacology*, 184: 154-186.
<https://doi.org/10.1016/j.jep.2016.02.039>

Cock IE 2008. Antimicrobial activity of Aloe barbadensis Miller leaf gel componets. *The International Journal of Microbiology*, 4(2). <https://doi.org/10.5580/15bc>

Emami MR, Rivandi M, Mehrnaz, Mehrjerdi HK, Azizzadeh M, Ghasemi S 2012. Bacteriological evaluation of Aloe vera L. fresh gel on experimental infected full-thickness open wounds induced with *Staphylococcus aureus* in dogs. *Iranian Journal of Veterinary Surgery*, 7(1-2).

Kim H, Kawazoe T, Han DW, Matsumara K, Suzuki S, Tsutsumi S 2008a. Enhanced wound healing by an epigallocatechingallate-incorporated. *Wound Repair and Regeneration*, 16(5): 714e20.
<https://doi.org/10.1111/j.1524-475X.2008.00422.x>

Kim HR, Rajaiiah R, Wu QL, Satpute SR, Tan MT, Simon JE. 2008b. Green tea protects rats against autoimmune arthritis by modulating disease-related immune events. *Journal of Nutrition*, 138(11): 2111e6.
<https://doi.org/10.3945/jn.108.089912>

Miah MAH, Hasan M, Sarker YA, Alam MM, Juyena NS 2017. Clinical evaluation of ethanolic extract of curcumin (*Curcuma longa*) on wound healing in Black Bengal goats. *Journal of Advanced Veterinary and Animal Research*, 4(2).
<https://doi.org/10.5455/javar.2017.d209>

Park G, Yoon BS, Moon JH, Kim B, Jun EK, Oh S 2008. Green tea polyphenol epigallocatechin -3-gallate suppresses collagen production and proliferation in keloid fibroblasts via inhibition of the STAT3-signaling pathway. *Journal of Investigative Dermatology*, 128(10): 2429e41.
<https://doi.org/10.1038/jid.2008.103>

Russel BA, Hardin JN, Grand L, Traser A 1997. Poisonous plants of north Carolina, caesalpinaspp (pride of Barbados). Department of Horticulture science. North Caroline state University.

Stapleton PD, Shah S, Anderson JC, Hara Y, Hamilton-Miller JMT, Taylor PW 2004. Modulation of α -lactam resistance in *Staphylococcus aureus* by catechins and gallates. *International Journal of Antimicrobial Agents*, 23: 462-467
<https://doi.org/10.1016/j.ijantimicag.2003.09.027>