

Correction of Skeletal Discrepancy and Facial Aesthetics by Combination of Orthodontic Management and Orthognathic Surgery

MN HASAN^a, MB ALAM^b, MSR KHAN^c

Summary:

Clinical management of non-growing adult patients with dentofacial deformity could be provided with better outcome when approach in-combined with orthodontic and orthognathic surgery than that of single approach

Introduction:

A bimaxillary protrusion is a condition in which the maxillary and the mandibular incisor teeth protrude severely so that the lips cannot be closed together. The condition is usually considered as an Angle Class I malocclusion,¹ and the anterior teeth are well aligned. However, it sometimes shows either mild crowding or spacing or mild vertical discrepancies ranging from an open bite to a deep bite.² The majority of patients who suffer from this condition seek treatment more for the enhancement of facial esthetics than for dental esthetics and function.³ Facial esthetic problems related to bimaxillary protrusion include extreme protrusion of the anterior teeth, lip incompetence, and strain with hypermentalis action on closure, thick looking lips with an everted vermilion border, and a toothy appearance due to an apparent chin deficiency.² This convex profile is found predominantly in Africans and Asian adults including the Chinese, the Japanese and in Caucasians.⁴

alone. This study describes a case of a 26years old Bangladeshi female presented with bimaxillary protrusion treated with the combination of orthodontic and orthognathic surgery.

(J Banagladesh Coll Phys Surg 2014; 32: 235-240)

Orthodontic management of bimaxillary protrusion cases usually involving additional anchorage control using trans-palatal bar, reverse pull headgear, and more recently mini-implant.^{5,6} However treatment time duration of more than years requires depending upon the severity of malocclusion.⁷ So in present case it was planned for a combination of orthodontic and orthognathic surgery to get a more predictable outcome within a short time duration. Pre-surgical orthodontics and postsurgical orthodontic management and orthognathic surgery with extraction of all permanent first premolar, a maxillary anterior segmental osteotomy and a mandibular anterior subapical osteotomy was planned for. Individual orthodontic management or orthognathic surgical management to correct skeletal discrepancy and to improve facial aesthetic has been reported in the literature.⁸ However combination of multidisciplinary involvement to manage such case in Bangladesh previously was not revealed in literature review. Therefore the aim of this case study is to reveal the treatment outcome of a combined orthodontic and surgical management of a Bangladeshi female with skeletal discrepancy.

Report of the Case:

A 26 years old unmarried female from Narsingdi reported to a private dental practice office in Dhaka with complain of ill-facial appearance due to unattractive smile by over exposure of gum and teeth while laughing (Figure 1 A,B). Her parents were also seeking short duration treatment as they need to settle their daughter's marriage as she already became over age for settlement (according to their opinion). Her past medical, dental and developmental history did not revealed any trauma or temporo-mandibular joint

- Dr. Md. Nazmul Hasan, Assistant Professor & Head, Department of Orthodontics & Dentofacial Orthopedics, Update Dental College & Hospital, Dhaka 1711, Bangladesh.
- Dr. Md. Badiul Alam, Assistant Professor & Head, Department of Oral & Maxillofacial Surgery, Shaheed Suhrawardy Medical College & Hospital, Dhaka 1207, Bangladesh.
- Dr. Mohammad Sayedur Rahman Khan, Honorary Medical Officer, Department of Oral & Maxillofacial Surgery, Shaheed Suhrawardy Medical College Hospital, Dhaka 1207, Bangladesh.

Address of Corresponding: Dr. Md. Nazmul Hasan, Assistant Professor & Head, Department of Orthodontics & Dentofacial Orthopedics, Update Dental College & Hospital, Turag, Dhaka 1711, Bangladesh, Phone : +8801817097748, e-mail: nazmul2246@yahoo.com mn.hasan@update dentalcollege.edu.bd

Received: 30 November, 2013

Accepted: 20 June, 2014

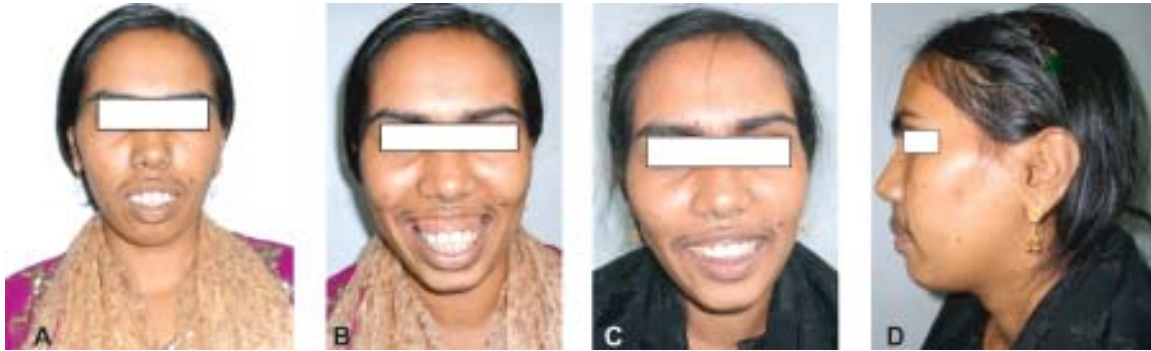

Fig-1: Extra oral photograph demonstrate patients pretreatment anterior lip seal in resting conditions (A), lip, teeth and gingival position during smile (B); post treatment lip & teeth position (C) and post-treatment improved facial profile(D).

disorder, no evidence of abnormal development due to hormonal influence, no protruding tongue thrusting, no abnormal swallowing pattern, no remarkable history of improper oral habits like thumb sucking, nail or pencil biting. However, her enlarge palatine tonsil, with relevant a mouth breathing pattern were noted which could be a contributory factor for developing protruded maxillary and mandibular anterior alveolar process.

On extra-oral facial form and lateral face profile examination, convex facial profile with protruding lips,

exposure of upper teeth and gingiva noticed in resting condition. Smile analysis shows excessive exposure of upper and lower gingiva and teeth, beyond the lower border of upper lip and upper border of the lower lip causing the distortion of smile arc which ultimately resulting ill facial appearance during smiling and laughing (Figure 1 A,B). Intra-oral examinations reveal carious both upper second molar teeth, badly broken lower left second molar(37), third molar(38) and right second molar(47) teeth (Figure 2 A,C,F,G,I) with

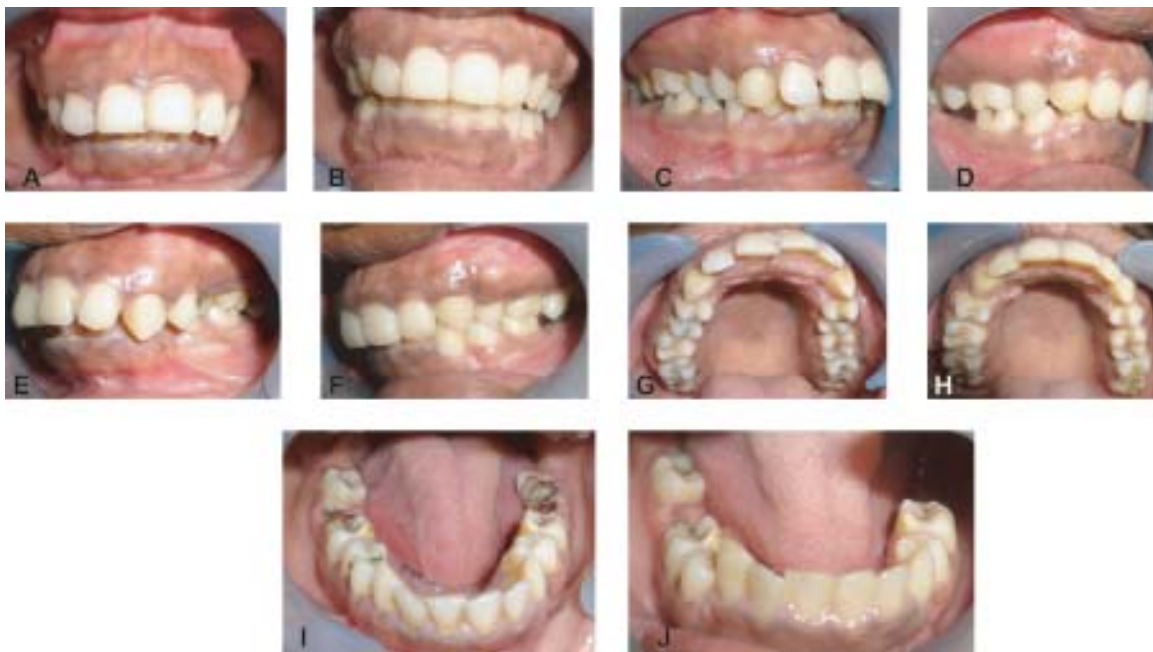

Fig-2: Patients intra oral photograph shows pre treatment front view (A), right lateral view(C), left lateral view(E), upper occlusal view(G),lower occlusal view (I) and post treatment front view (B), right lateral view(D), left lateral view(F), upper occlusal view(H),lower occlusal view (J).

moderate gingivitis despite of patients reporting regular teeth brushing. This significantly explains the possible consequence of oral breathing habits resulting dry mouth with increasing carious tendency. Routine radiographic examinations with panoramic radiograph did not shows any periapical lesions on broken teeth (37, 38, 47) or caries extended to pulp chamber (17, 27) requiring endodontic treatment (Figure 5 A). On dental cast analysis it reveals that patient having a class I molar and canine relationship with increasing overjet 5.5 mm and overbite 3.0mm. Lateral cephalometric radiograph analysis shows increase SNA and SNB resulting from increase ANB which concluded a bimaxillary proclination case (Table 1). Orthodontic treatment planning with extracting all first premolar teeth and using orthodontic mini-implant (to prevent anchorage loss) were prescribed. However patient's parents were seeking alternate method of management as this conventional treatment might require almost two years to manage this case and as they were in a hurry to arrange a marriage settlement of their daughter.

Finally a combination of orthodontic treatment and orthognathic surgery were prescribed and accepted by the patient and her parents. Initial pre-surgical

orthodontic treatment was done to correct the rotated teeth, crown root angulations of the teeth, space closure, and reduce the overjet and deep overbite. A standard edgewise technique bracket of 0.022×0.025 slot sized was used, where the final finishing wire was 0.021×0.025 stainless steel with proper torque control on upper anterior teeth. Extraction of all four first premolar with a segmental osteotomy cut on upper and lower anterior segment to retrocline the anterior segment and then fixed with the remaining jaw bone with miniplate and screw were planed. Therefore after completing the initial pre-surgical orthodontic treatment patient's dental cast was recorded and articulated on a dental articulator to evaluate the present pre-surgical jaw relationship. Then a mock surgery was performed on the articulated model and a bight wafer made of auto cured acrylic resign was constructed on that mock surgery model that will guide the maxillofacial surgeon to evaluate the post surgical jaw relationship during surgical procedure (Figure 3 A,B).

Patient's orthognathic surgery was performed in the department of oral and maxillofacial surgery of Shaheed Suhrawardy Medical College Hospital, Dhaka. With proper aseptic caution, under general anesthesia a

Table-I

Cephalometric Parameter changes by treatment approach.

Cephalometric Parameter	Pre treatment	Post treatment
SNA	85°	82°
SNB	80°	78°
ANB	5°	3°
FMA	27°	27°
Interincisal Angle	118°	124°
U1 to S-N plane	94°	102°
L1 to mandibular plane	5°	2°

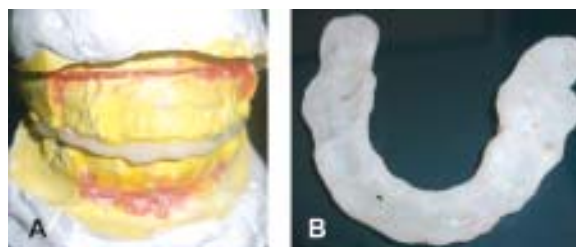


Fig.-3: Construction of acrylic made interocclusal wafer splint on the articulated model with mock surgery (A), which is ready to use (B).

vertical incision on the long axis of the distal margin of upper first premolar (14 & 24) was made on the right and left vestibule of the mouth extending from the gingival papilla to the functional depth of the vestibule. Then both premolars were extracted and vertical cut on the bone were given using tungsten carbide drill bits then bone segment were removed by using drill bits in a vertical area of the extraction site (Figure 4 A). With an aid of muco-peri-osteal elevator, retracting the mucoperiosteum from the overlying bone, a through and through tunneling were made connecting the both incision line. Then a horizontal osteotomy cut were made through the tunnel, protecting the root apex of all anterior teeth. Then the upper anterior segment were made immobilized with an aid of osteotom placed transpalatally from the vertical cuts going through downwards and forwards and with placing finger on the palatal mucosa to prevent laceration. Then reposition of anterior maxillary segment was done and the occlusal relationship was checked with the acrylic made interocclusal wafer splint (Figure 4 B). After extracting both lower first premolar, circumvestibular incision was made on the lower anterior vestibule of the mouth extending horizontally from the root apex of both lower canines. Care was taken to locate and protect the both mental nerve. On both side of the mandible a vertical

cut was made from the alveolar crest to the level of canine root apex through and through the both cortices. Then both the vertical cuts were connected by the horizontal subapical osteotomy made about 5 mm below the teeth apices (Figure 4 C). The segment was mobilized by using an osteotome and bony interferences were removed to place the teeth into the prefabricated occlusal splint. Both the maxillary and mandibular anterior segments were stabilized by using miniplate fixation (Figure 4 D).

Post surgical intermaxillary fixation to maintain the vertical position of the teeth and increase intercuspal interdigitation elastic with bracket hook and arch wire were used. After 6 weeks of post surgery arch wire were changed and final finishing tooth movement were done with a 0.018×0.22 NiTi wire and 0.021×0.22 NiTi wire successively. Patient was advised to use light elastic full time, including while eating for the first 4 weeks after surgery; full time except for eating for another 4 weeks; and just at night for a three week period. After 3 months of post surgical treatment patient braces were removed and removable hawleys retainer on both jaws was given to use. An improved occlusion relation (Figure 1D,C and 2 B,D,F,H,J) was achieved with a favorable skeletal change as mentioned in Table 1.

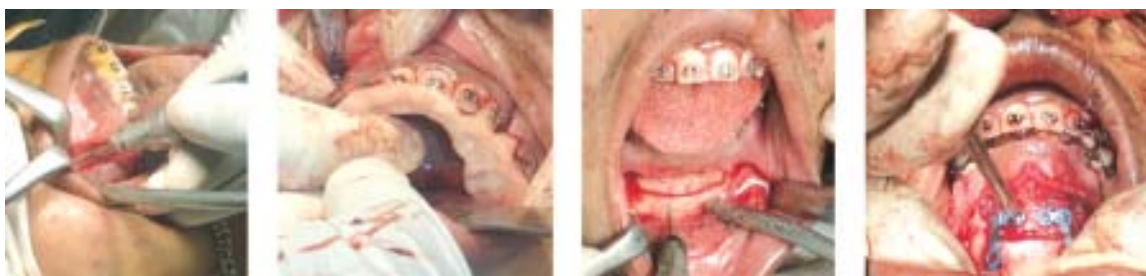

Fig.-4: Intra oral photograph shows steps of orthognathic surgical technique vertical cut on right maxillary vestibule (A), occlusal relation checking with acrylic wafer after finishing of segmental osteotomy on maxilla(B), subapical anterior mandibular cut on mandible (C), and fixation of mobile segment with miniplate screw (D).

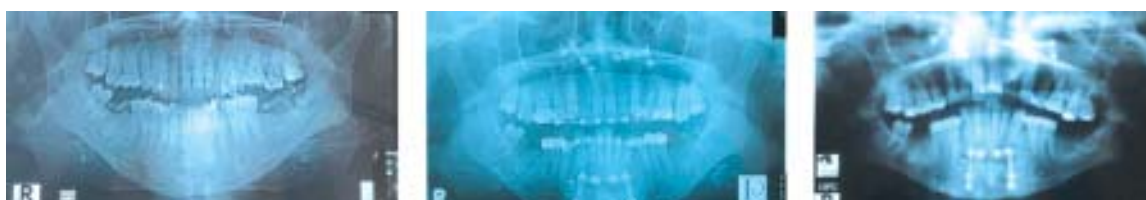

Fig.-5: Photograph of oral panoramic radiograph(OPG) shows pre treatment occlusion (A), post surgical occlusion (B) when there is braces to continue post orthodontic treatment, and final finishing occlusion (C) after removal of orthodontic braces.

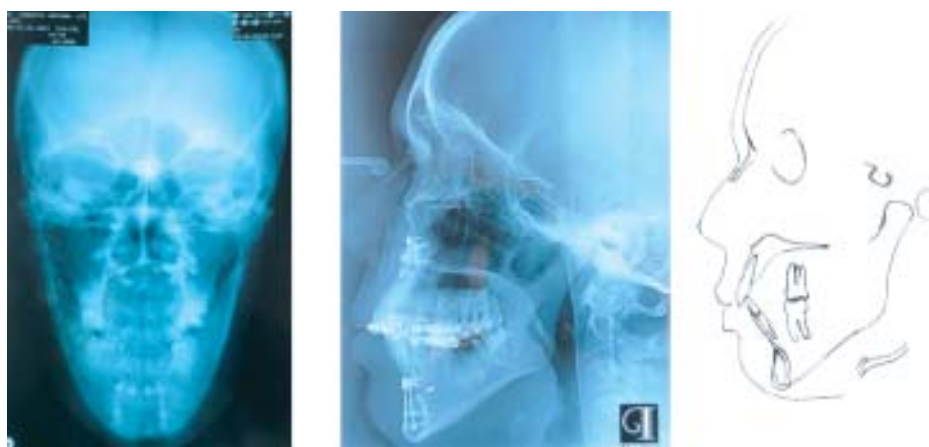

Fig.-6: Cephalometric evaluation of post treatment occlusion and skeletal relationship by frontal cephalometric radiograph (A), lateral cephalometric radiograph (B), and tracing of lateral cephalometric post treatment radiograph (C).

After removal of the dental braces patient's was also advised for prosthesis teeth replacement on lower posterior edentulous space. Threading of her facial hair over her upper lip and removal of mole on her left cheek with leaser therapy was also advised to improve external facial appearances. Repeated phone contact was made with patient and her parents, to ensure them the prosthetic teeth replacement and beautification of her facial skin to improve outlook, however she and her parents were too satisfied with their existing treatment outcome to make any further delay for her marriage settlement. So, no further collection of photographic records with occlusion having proper teeth prosthesis and a photogenic face with exotic look women appearances were not possible to present. Though patient reported to be healthy and having a happily married life till date.

Discussion:

Achieving an acceptable pleasant full smile and proportionate facial structure depends on the combination of underlying hard tissue skeleton, overlying soft tissue outline and proper presentation of the existing tooth tissue.⁹ Achievement of the optimal esthetics of this case depends on several favorable factors of the conditions of the patient, they include: (i) Neutral skeletal base relationship with only anterior maxillary and mandibular prognathism. (ii) Adult with limited potential of growth. (iii) Convex facial profile. If there would severe skeletal discrepancy, with potential

growth that would hamper the post treatment stability.⁷ To obtain the long-term stability of the corrected occlusion and skeletal relationship, patients have to resolve the respiratory problems and avoiding thrusting their tongue anteriorly (if they have) all the time.⁹

Individual orthodontic treatment with longtime duration or only orthognathic surgery cannot manage such case. Age of the patients could not be a decelerating factor to manage a complicated cases by orthodontic treatment approach.¹⁰ However only surgical correction cannot achieve good post surgical occlusion without aid of orthodontic treatment.⁸ Multidisciplinary management approach have already been reported to achieve a good post-treatment outcome.¹¹ In our reported case pre and post treatment cephalometric evaluations show that both reduction of SNA and SNB angle improves the facial aesthetics (Table 1). The clinician should carefully differentiate between maxillary anterior posterior excess and mandibular anterior posterior deficiency, as maxillary anterior posterior deficiency or excess can occur in combinations of mandibular deficiency or excess. McNamara reported only 10% of a group of 277 patients with class I malocclusions had true maxillary anteroposterior excess.¹² Therefore careful diagnosis is required before formulating a treatment plan. The surgical techniques for repositioning the anterior maxilla have been introduced by Wassmund.¹³ Later on most practical approach was introduced by Wunderer.¹⁴ In our present case, post treatment

reduction of SNA, SNB, ANB with the increase inter-incisal angle and static FMA angle clearly explain the improvement of skeletal change in the anterior maxillary and mandibular region of the bimaxillary proclination cases without altering the deep cranial base. Moreover angular change of lower incisor (L1) and upper incisor (U1) position in relation to the cranial base and mandibular plane improve the smile largely. Another reason to chive favorable outcome as this was a case with non growing patients. Care must be taken to handle the case with any remnant growth or where late mandibular growth might occur.

Conclusion:

Combine effort with a multidisciplinary approach to manage cases of dentofacial deformity could be provide better treatment outcome. However care should be taken with cautious diagnosis and treatment planning.

References:

- Dale JG, Dale HC. Interceptive guidance of occlusion with emphasis on diagnosis. In: Graber LW, Vanarsdall RL, Vig KWL (eds). *Orthodontics current principles and techniques*. 5th ed. Philadelphia: Mosby. 2012, 429-430.
- Proffit WR. The etiology of orthodontic problems. In: Proffit WR, Field HW, Sarver DM (eds). *Contemporary Orthodontics*. 5th ed. St Louis: Mosby. 2013, 114-145.
- Rafique T, Hassan GS, Hasan MN, Khan SH. Prevailing Status and Treatment Seeking Awareness Among Patients Attending in The Orthodontics Department of Bangabandhu Sheikh Mujib Medical University. *Bangabandhu Sheikh Mujib Medical University Journal*, 2011; 4(2): 94-98.
- Farrow AL, Zarrinnia K, Azizi K. Bimaxillary protrusion in black Americans -An esthetic evaluation and the treatment considerations. *Am J Orthod Dentofac Orthop* 1993;104: 240-250.
- Shroff B, Lindauer SJ. Temporary anchorage devices: Biomechanical opportunities and Challenges. In: Nanda R, Kapila S. *Current therapy in orthodontics*. 1st ed. St Louis: Mosby. 2010, 278-288.
- Sugawara J, Nagasaka H, Kawamura H, Nanda R. Distalization of Molars in Nongrowing Patients with Skeletal Anchorage. In: Nanda R, Kapila S. *Current therapy in orthodontics*. 1st ed. St Louis: Mosby. 2010, 301-319.
- Kharbada OP, Darendeliev MA. Ortho-surgical management of skeletal malocclusions. In: Kharbada OP. *Orthodontics: Diagnosis and Management of Malocclusion and Dentofacial Deformities*. 2nd ed. New Delhi: Reed Elsevier India ltd, 2013, 645-664.
- Rahman QB, Hassan GS, Akther M, Rubby MG, Hasan MN. Correction of Anterior Open Bite and Facial Profile by Orthognathic Surgery- A Case Report. *Bangabandhu Sheikh Mujib Medical University Journal*, 2010; 3(1): 31-34.
- Proffit WR, Sarver DM, Ackerman JL. Orthodontic Diagnosis: the problem-oriented approach. In: Proffit WR, Field HW, Sarver DM (eds). *Contemporary Orthodontics*. 5th ed. St Louis: Mosby. 2013, 150-219.
- Hasan MN, Quader SMS, Khan MAA, Hossain MM. Could 'Age' be a potential decelerating factor in clinical orthodontics. *Update Dental College Journal*, 2012; 2(2):51-55.
- Begum A, Sajedeem M, Hasan MN. Orthodontic Movement of Tooth for the Correction of Occlusion Prior to Prosthetic Treatment- A Case Report. *Dinajpur Medical College Journal*, 2012; 5 (1):67-71.
- McNamara JA Jr. Components of class II malocclusions in children 8-10 years of age. *Angle Orthodontics*, 1981;51(3):177-202.
- Wassmund M, *Lehrbuch der probleschen Chirurgie des Mundes und der kiefer*, vol 1. Leipzig: Meuser, 1935.
- Wunderer S. Erfahrungen mit der operativen Behandlung hockgradiger Prognathien. *Dtsch Zahn Mund Kieferheilkd*. 1963; 39:451-52.