

# Successful Pregnancy Outcome in Antiphospholipid Antibody Syndrome with Several Comorbidities

L CHOWDHURY<sup>a</sup>, ARAZZAK<sup>b</sup>, R KHAN<sup>c</sup>, H SULTANA<sup>d</sup>

### Summary:

*The presence of antiphospholipid antibody (aPL) has been clearly shown to have an adverse effect on pregnancy outcome. These effects may be apparent in the first trimester, presenting as recurrent pregnancy loss, or may be associated with the later development of pre-eclampsia (PE), IUGR, placental abruption, pre-term delivery, and intrauterine death. Antiphospholipid antibodies accounts for 3-5% of patients with second trimester repetitive pregnancy losses. The frequency of foetal death & recurrent abortion in untreated patient is greater than 90%. We will discuss here a 26 years old pregnant lady who was diagnosed 06 months prior to this pregnancy during pre conceptional counseling as antiphospholipid syndrome (APLS), autoimmune hypothyroidism and hypertension. She was on aspirin,*

*heparin & thyroxine and ovulation inducing drugs before conception. After conception she was on close monitoring by the Obstetrician and Medicine specialist and ultimately on 36<sup>th</sup> week pregnancy was terminated by LSCS & a female baby was delivered. However, although the live birth rate is increased sevenfold, it should be acknowledged that these births are associated with an increased rate of prematurity and possible neonatal complications. The increased incidence of pregnancy-related complications necessitates the need for careful antenatal surveillance, and for delivery to be conducted in a unit with facilities for operative delivery and neonatal intensive care.*

**Key Words:** Pregnancy, APS, recurrent foetal loss.

(J Bangladesh Coll Phys Surg 2016; 34: 160-163)

### Introduction:

Antiphospholipid syndrome or antiphospholipid antibody syndrome (APS or APLS), often also Hughes syndrome, is an autoimmune hypercoagulable state caused by antibody against cell membrane phospholipid that provokes blood clots in both arteries and veins as well as pregnancy related complications. The disease is characterised by recurrent venous or arterial thrombosis, recurrent foetal loss, thrombocytopenia and presence of antibody to antiphospholipid such as anticardiolipin antibody. The antiphospholipid antibody

syndrome may be primary or secondary. For all the patients with APS Female: male=2:1. Among patients with SLE the prevalence of APLS is much higher. HLA-DR7 is the risk factor for Primary APS and HLA-B8, HLA-DR2, HLA-DR3 for secondary APS. SLE or other autoimmune disorders and races like Blacks, Hispanics, Asians and Native Americans are at risk of developing secondary APS. Obstetrics manifestations of APS includes recurrent foetal loss, IUGR, pre eclampsia, postpartum syndrome. Other systemic manifestations includes-Neurologic (CVD, TIA, severe migraine, ischemic encephalopathy, seizures, peripheral neuropathy), Cardiovascular (MI, mitral or aortic valvular lesion, pseudo infective endocarditis), Dermatologic (livedo reticularis, leg ulcer, necrotizing purpura, widespread cutaneous necrosis), Haematologic (thrombocytopenia, leukopenia, Coombs' positive haemolytic anaemia) and others such as avascular necrosis, non thrombo embolic pulmonary HTN etc.

### Case Report:

Mrs. Reshma 26 years, para:2-2, housewife of lower middle class family admitted in Combined Military Hospital (CMH) Dhaka on 19<sup>th</sup> March 2012 at her 22 weeks pregnancy. She was married for 11 years &

- Prof. Dr. Brig. Gen. Liza Chowdhury, Advisor specialist, Head of the Department of Obs and Gynae, AFMC.
- Prof. Dr. Brig. Gen. Abddur Razzak, Advisor Specialist, Head of the Department of Medicine, Chittagong CMH.
- Prof. Dr. Col. Rokeya Khan, Classified Specialist, Department of Obs and Gynae, Dhaka CMH.
- Prof. Dr. Brig. (Rtd) Gen. Hasina Sultana, Head of the Department of Obs and Gynae, MHS Shomorita Medical College and Hospital.

**Address of Correspondence:** Prof. Dr. Brig. Gen. Liza Chowdhury, Advisor Specialist, Head of the Department of Obs and Gynae, AFMC, Cell-01819220507 e-mail- dr.lizachy@gmail.com

**Received:** 5 March, 2014

**Accepted:** 30 January, 2016

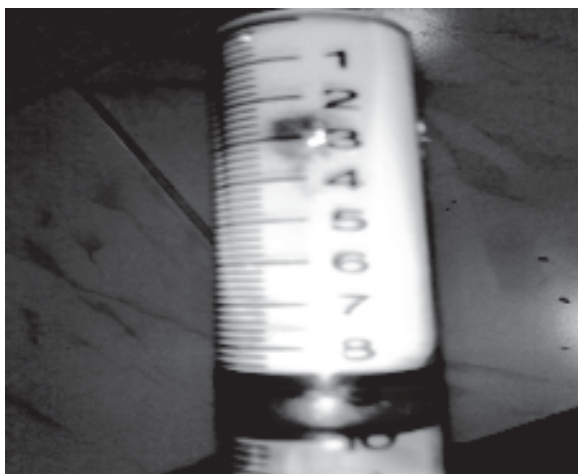
conceived after 4 years of marriage in 2005. Her pregnancy was terminated by C/S at 36 weeks gestation due to severe PE & oligohydramnios, baby died 05 days after birth due to IUGR related complications.

Second pregnancy in 2008 was also complicated by severe PE & baby was born vaginally at 28 weeks died immediately after birth due to severe birth asphyxia & low birth weight (LBW). After that she reported to GOPD with complaints of progressive weight gain, cold intolerance and irregular menstruation for 02 years. At that time she was thoroughly investigated & diagnosed as a case of Primary APS, autoimmune hypothyroidism & HTN.

With above diagnosis she was treated accordingly with joint consultation of Obstetrician & Medicine specialist. She was advised levo-thyroxine, aspirin, folic acid and ovulation inducing drug. With these advice after 02 month she conceived and report to hospital immediately after conception. At 06 weeks of gestation she reported to OPD and Inj Heparin (5000 unit S/C 8 hourly) and alpha methyl dopa was added. She was under regular follow up of Obstetric & Gynae and Medicine OPD.

At 19 weeks of gestation she was admitted with severe epigastric pain and vomiting. She was nursed in ICU, examined and investigated & diagnosed to be a case of acute pancreatitis due to dyslipidaemia and hyperglycaemia. Patient was discharged from hospital with inj heparin, diet control for diabetes and follow up investigation of lipid profile & GTT after 2 weeks.

At 22 weeks she again got admitted with same complaints & treated conservatively as a case of acute pancreatitis. S. Triglyceride as 1226 mg/dl.



**Fig.-1:** Blood sample of the patient.

In ICU she was under close supervision of Intensivist, rheumatologist, gastroenterologist, Obstetrician. She remained admitted upto 34 weeks of gestation in hospital under close monitoring of Medicine specialist and regular follow up by obstetrician. Pregnancy was terminated by LSCS at 36 weeks of gestation. Before hand anticoagulant & aspirin was stopped and inj Dexamethasone was given 03 days prior to LSCS.

A female baby of 2.8 kg weight was delivered who had respiratory distress at birth, later on upper GI bleeding which was managed with Fresh Frozen Plasma transfusion & vit K. Subsequently the baby diagnosed as a case of congenital hypothyroidism.

Immediately after delivery Inj LMWH (Enoxaperin) followed by tab Warfarin was started accordingly. Patient was discharged on 16<sup>th</sup> postoperative day on tab aspirin, tab thyroxine, tab fenofibrate, tab atorvastatin, tab calcium & folic acid with advice for regular follow up in OPD. On post natal check up after 06 weeks mother & baby was found alright and barrier contraceptive was advised. She was given assurance to be pregnant again after 2-3 years.

#### **Discussion:**

The persistent presence of medium to high levels of IgG and/or IgM class anticardiolipin antibodies (aCL) and/or the lupus anticoagulant (LAC) in plasma is associated with both “recurrent pregnancy loss” and venous and arterial thrombosis. This clinicoserological entity, when diagnosed in patients with underlying autoimmune disease (usually Systemic Lupus Erythematosus, or SLE), APS is termed secondary antiphospholipid syndrome (APS).<sup>1</sup> APS also occurs in otherwise healthy people led to the term primary antiphospholipid syndrome.<sup>2</sup>

Clinical studies indicate that aPL are related to both early pregnancy losses and fetal demise in advanced pregnancy. Placental thrombosis and infarction are common findings in aPL related intrauterine fetal deaths.<sup>3</sup> Apart from being risk factors for fetal demise, aPL associate with high frequencies of pre-eclampsia, intrauterine growth restriction, fetal distress, and premature delivery.<sup>4</sup>

The presence of more than one class of antiphospholipid antibodies increases thrombotic risk<sup>5</sup>. Patients who are test positive for all three of the major assays - positive LAC, elevated anticardiolipin

antibodies and elevated anti-2GPI antibodies (referred to as “triple positivity”), are at markedly increased risk for thrombosis and for pregnancy complications<sup>6</sup>.

About 10-15% of women with recurrent miscarriage are diagnosed with antiphospholipid syndrome<sup>7</sup>. Fetal loss ( $\geq 10$  weeks of gestation) is more strongly associated with aPL than are earlier pregnancy losses. Lupus anticoagulant has been strongly associated with recurrent miscarriage before the 24th week of gestation<sup>8</sup>. Current APS criteria include early delivery, oligohydramnios, neonatal complications such as prematurity—estimated at 30-60% and more common in SLE patients, intrauterine growth restriction (IUGR), fetal distress and rarely fetal or neonatal thrombosis<sup>9</sup>, associated maternal obstetric complications like pre-eclampsia or eclampsia and HELLP syndrome, arterial or venous thrombosis and other aPL-related complications like placental insufficiency<sup>10</sup>. The association between antiphospholipid antibodies and the risk of premature birth due to eclampsia or preeclampsia and intrauterine growth restriction remains controversial; studies contributing data to this area tend to be small, retrospective, and have conflicting results<sup>11</sup>.

A randomized controlled study of prednisone and aspirin as compared with heparin and aspirin showed low-dose subcutaneous heparin with low-dose aspirin to be equally efficacious with less morbidity<sup>12</sup>. A 2005 Cochrane systematic review concluded that women with recurrent miscarriage and antiphospholipid syndrome should be given a combination of heparin 5000 IU subcutaneously twice daily and low-dose aspirin<sup>13</sup>.

Evidence-Based Clinical Practice Guidelines of American College of Chest Physicians<sup>14</sup> suggest that women with antiphospholipid antibodies and a history of 2 or more early pregnancy losses or 1 or more late pregnancy losses who have no prior history of thrombosis receive treatment with combination aspirin and heparin (unfractionated or lowmolecular-weight) during pregnancy. Aspirin (81 mg/d) should be started with attempted conception; most investigators recommend, in fact, preconceptional aspirin because of its possible beneficial effect on early stages of implantation<sup>15</sup>.

Most of these possible future therapies (clopidogrel, rivaroxaban, statins, rituximab, and other new anticoagulant drugs) are for non-pregnant patients. The only new drugs for APS that pregnant women can use

are dipyridamole and hydroxychloroquine. Observational studies have suggested an antithrombotic effect of hydroxychloroquine in patients with antiphospholipid antibodies, most of whom have systemic lupus erythematosus<sup>16</sup>.

### Conclusion:

APS is an uncommon disease with diverse clinical manifestations. A high clinical suspicion is required to diagnose it. With treatment and close monitoring the prognosis improves dramatically. Successful pregnancy outcome in a patient with APS require a multidisciplinary approach.

### Reference:

- Petri M. Pathogenesis and treatment of the antiphospholipid antibody syndrome. *Med Clin North Am* 1997;81:151–77
- Asherson RA, Khamashta MA, Ordi-Ros J, Derksen RH, Machin SJ, Barquinero J, et al. The ‘primary’ antiphospholipid syndrome: major clinical and serological features. *Medicine (Baltimore)* 1989;68:366–74.
- Out HJ, Kooijman CD, Bruinse HW, Derksen RHWM. Histopathological findings in placentae from patients with intra-uterine fetal death and anti-phospholipid antibodies. *Eur J Obstet Gynecol* 1991;41:179–86.
- Branch DW, Silver RM, Blackwell JL, Reading JC, Scott JR. Outcome of treated pregnancies in women with antiphospholipid syndrome: an update of the Utah experience. *Obstet Gynecol* 1992;80:614–20.
- Forastiero R, Martinuzzo M, Pombo G, et al. A prospective study of antibodies to beta2-glycoprotein I and prothrombin, and risk of thrombosis. *J Thromb Haemost.* 2005;3:1231–38.
- Pengo V, Biasiolo A, Pegoraro C, Cucchini U, Noventa F, Iliceto S. Antibody profiles for the diagnosis of antiphospholipid syndrome. *Thromb Haemost.* 2005; 93: 1147–52.
- Rai RS, Regan L, Clifford K, et al. Antiphospholipid antibodies and s2-glycoprotein-I in 500 women with recurrent miscarriage: results of a comprehensive screening approach. *Hum Reprod.* 1995;10:2001–05.
- Opatny L, David M, Kahn SR, Shrier I, Rey E. Association between antiphospholipid antibodies and recurrent fetal loss in women without autoimmune disease: a metaanalysis. *J Rheumatol.* 2006;33:2214–21.
- Avcin T, Cimaz R, Meroni PL. Recent advances in antiphospholipid antibodies and antiphospholipid syndromes in pediatric populations. *Lupus.* 2002;11:4–10.
- Branch DW, Khamashta MA. Antiphospholipid syndrome: obstetric diagnosis, management, and controversies. *Obstet Gynecol.* 2003;101:1333–44.

11. Branch DW, Silver RM, Blackwell JL, Reading JC, Scott JR. Outcome of treated pregnancies in women with antiphospholipid syndrome: an update of the Utah experience. *Obstet Gynecol.* 1992;80:614–20.
12. Cowchock FS, Reece EA, Baldan D, et al. Repeated fetal losses associated with antiphospholipid antibodies: a collaborative randomized trial comparing prednisone with low dose heparin treatment. *Am J Obstet Gynecol.* 1992;166:1318–1327.
13. Empson M, Lassere M, Craig J, Scott J. Prevention of recurrent miscarriage for women with antiphospholipid antibody or lupus anticoagulant. *Cochrane Database Syst Rev.* 2005;CD002859 .
14. Bates SM, Greer IA, Pabinger I, Sofaer S, Hirsh J. Venous thromboembolism, thrombophilia, antithrombotic therapy, and pregnancy: American College of Chest Physicians Evidence-Based Clinical Practice Guidelines (8th edn) *Chest.* 2008;133:844S–86S.
15. Carmona F, Font J, Azulay M, et al. Risk factors associated with fetal losses in treated antiphospholipid syndrome pregnancies: a multivariate analysis. *Am J Reprod Immunol.* 2001;46:274–79.
16. Tektonidou MG, Laskari K, Panagiotakos DB, Moutsopoulos HM. Risk factors for thrombosis and primary thrombosis prevention in patients with systemic lupus erythematosus with or without antiphospholipid antibodies. *Arthritis Rheum.* 2009;61:29–36.