

Poland Syndrome- A Rare Congenital Condition

HT HOSSAIN^a, MAK KHANDAKER^b, QT ISLAM^c,
HAMN AHASAN^d, MMBMS ADNAN^e, N ISLAM^f

Summary:

Named after Sir Alfred Poland, Poland syndrome is a rare congenital anomaly classically characterized by the absence of unilateral chest wall muscles and sometimes ipsilateral symbrachydactyly (abnormally short and webbed fingers). The aetiology is probably a vascular disruption sequence of the subclavian arteries. In most cases, Poland Syndrome is sporadic. We report a 26 year old male patient with typical features of Poland Syndrome associated with

bronchiectasis and mitral valve prolapse- a very rare association. To the best of our knowledge, this is the first documented case of a Poland Syndrome with rare association reported from Bangladesh.

Key words: Poland Syndrome, symbrachydactyly.

(*J Bangladesh Coll Phys Surg 2018; 36: 166-169*)

DOI: <http://dx.doi.org/10.3329/jbcps.v36i4.38186>

Introduction:

Poland's Syndrome is a rare congenital condition. It was first described in 1841 by Sir Alfred Poland as a syndrome presenting with absence or under development of pectoralis major muscle, associated in some cases with a hypoplasia of the breast, an agenesis of 2,3, 4 and 5 ipsilateral costal cartilage, an athelia, and an ipsilateral webbing of the fingers (cutaneous syndactyly) ^{1,2}

Because Poland syndrome is underreported and infrequently diagnosed, the exact incidence is difficult to determine. The current incident estimates range between 1:7,000 and 1: 100,000 births, with higher frequency among males (ratio, 2:1 – 3:1). In 75% of the cases, it is located on the right hemithorax in the unilateral form. ^{3,4,5,6}

Although several theories have been advanced to explain the etiology of Poland syndrome, most evidence indicates that it results from a vascular developmental anomaly during the critical sixth week of gestation, with hypoplasia of the subclavian artery causing musculoskeletal malformations. ⁷

Predominant clinical feature of Poland syndrome⁸ :

- Absent sternocostal head of pectoralis major
- Absent pectoralis minor
- Hypoplasia of latissimus dorsi, serratus anterior, external oblique & intercostal muscles, infra and supraspinatus, deltoid
- Hypoplasia or absence of nipple & breast
- Bony dysostoses affecting hand (brachymesophalagy with syndactyly, biphalangy, ectrodactyly), wrist, forearm, upper arm, scapula
- Axillary webs & absence of axillary hair; minimal subcutaneous fat, if any
- Soft tissue syndactyly
- Scoliosis
- Hypoplasia of hemithorax or ribs

In most cases, the abnormalities in the chest area do not cause health problems or affect movement.

We are reporting a 26 year old male patient with typical skeletal deformities of Poland syndrome, associated with bronchiectasis & mitral valve prolapse- a very rare association. This paper is aimed at bringing awareness

-
- a. Dr. Homayra Tahseen Hossain, Associate Professor, Medicine, Popular Medical College Hospital, Dhaka
- b. Prof. Md. Abul Kashem Khandaker, Professor & Head of Medicine, Popular Medical College Hospital, Dhaka
- c. Prof. Quazi Tarikul Islam, Professor of Medicine, Popular Medical College Hospital, Dhaka
- d. Prof. HAM Nazmul Ahasan, Professor of Medicine, Popular Medical College Hospital, Dhaka
- e. Dr. Munshi MB Md. Shoaib Adnan, Registrar, Medicine, Popular Medical College Hospital, Dhaka
- f. Dr. Nazmul Islam, Intern Doctor, Popular Medical College Hospital, Dhaka

Address of Correspondence: Dr. Homayra Tahseen Hossain, Associate Professor, Medicine, Popular Medical College Hospital, Dhaka. Email: homayra.tahseen@gmail.com

Received: 28 July, 2016

Accepted: 21 May, 2018

to health professional of Bangladesh of this rare congenital condition.

Case report:

A 26 year old young unmarried male presented to us with the complaints of high grade fever, productive cough with purulent foul smelling sputum and exertional respiratory distress for last 10 days. He gave history of frequent attacks of similar problem for last 7-8 years. On query, he admitted that, he had been suffering from some skeletal deformity since his childhood. As this deformity did not cause any health problem, he never consulted any physician for this. There was no family history of similar disorder. No history of consanguinity of marriage between his parents.

Examination revealed, his chest was asymmetric with flattening of anterior chest wall of right side. The pectoralis major muscle was absent. (Fig- 01) The movements of right shoulder were possible. The fingers of right hand were short and webbed (sybrachydactyly) .He had deformed right foot also with only 3 fused fingers (Fig-02). The left side of his body had normal configuration.

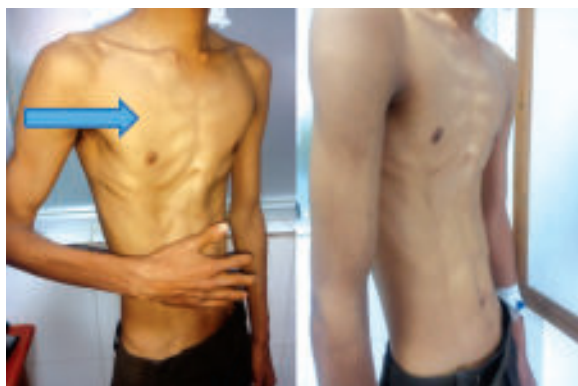

Fig-1: Flattening of anterior chest wall of right side.

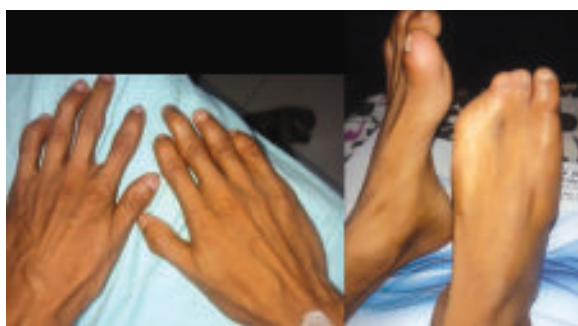

Fig.-2: Photographs of patient's deformed right hand & foot.

Examination of respiratory system revealed presence of bilateral coarse crepitations. Cardiovascular system examination revealed forceful apex beat in left 5th intercostal space, loud pulmonary component of second heart sound & presence of faint systolic murmur in tricuspid and mitral area. Alimentary system & nervous system examination revealed normal findings including normal intelligence.

ence of faint c murmur in tricuspid and mitral area. Alimentary system & nervous system examination revealed normal findings including Examination of respiratory system revealed presence of bilateral coarse crepitations. Cardiovascular system examination revealed forceful apex beat in left 5th intercostal space, loud pulmonary component of second heart sound & presence of faint systolic murmur in tricuspid and mitral area. Alimentary system & nervous system examination revealed normal findings including normal intelligence.

Important Investigations revealed,

- CBC- Neutrophilic leucocytosis, normal haemoglobin & platelet count
- Renal function test, liver function test, blood sugar-normal
- CXR P/A view- bilateral extensive cystic bronchiectasis with minimal pleural effusion (Fig-03)
- X-ray right hand- Distal & middle phalanges of index, middle, ring & little finger and distal phalanx of thumb is hypoplastic. Joint spaces are reduced with bony ankylosis between distal & middle phalanges of index, ring & little finger- ? congenital defect (Fig- 04)
- X-ray right foot – Foot is deformed. Hypoplastic 1st metatarsal & aplasia of phalanges of great & 2nd toe is noted. Hypoplasia of distal phalanx of 2nd & 3rd toe is noted.(Fig-05)
- USG of whole abdomen- Normal study
- Colour Doppler Echocardiography- Mitral valve prolapse with Tricuspid regurgitation & moderate pulmonary hypertension. Left ventricular function –normal.

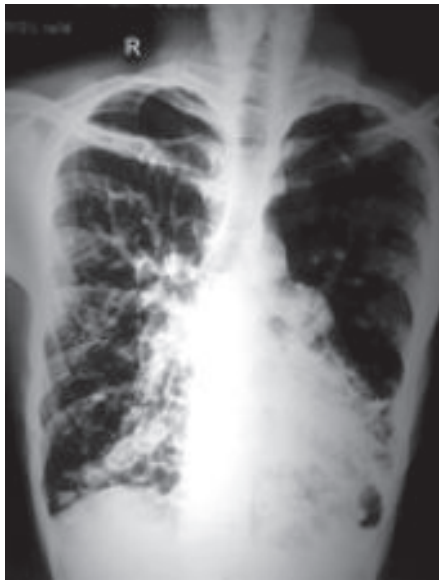

Fig-3: CXR P/A view- bilateral extensive cystic bronchiectasis.

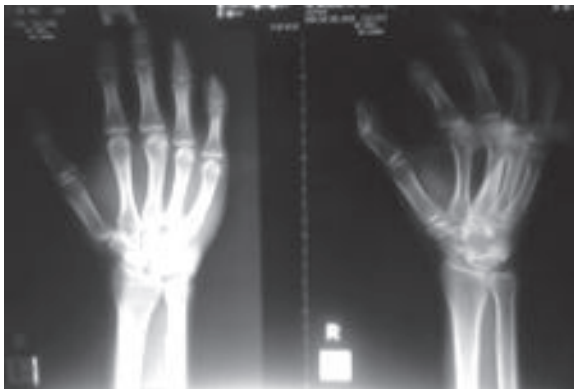


Fig-04: X-ray right hand

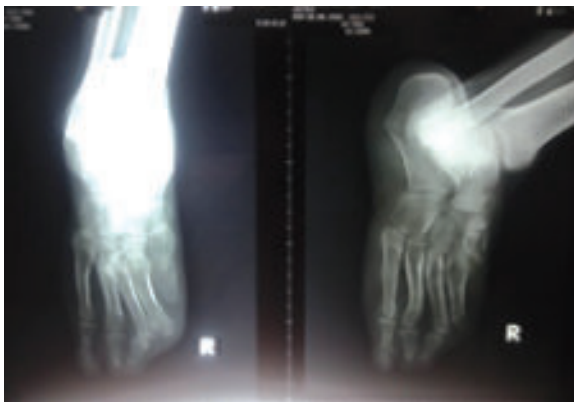

Fig-05: X-ray right foot

On the basis of physical findings & radiological evidence- a diagnosis of Poland syndrome was made. Along with this congenital anomaly, the patient had bilateral bronchiectasis with secondary infection with mitral valve prolapse & pulmonary hypertension. He was treated conservatively & his respiratory symptoms were improved. No surgical treatment was offered.

Discussion:

Our patient presented to us with the features of lower respiratory tract infection on the background of longstanding bronchiectasis & some skeletal deformity since childhood which was undiagnosed upto this 26 years of age. It proves that, as there was no functional impairment, this patient from poor socio-economic background did not bother about the cosmetic disfigurement. Presence of typical clinical features of Poland syndrome involving the right side of his chest & right upper & lower limb lead us to the diagnosis of Poland syndrome which was associated with bilateral bronchiectasis & mitral valve prolapse. Literature review did not show any known association among these three diagnoses. So, probably, to the best of our knowledge, this is the first such case with rare association.

The exact etiology of the Poland syndrome is unknown. It is assumed that the aplasia of the pectoralis muscles and associated chest defects, are consequences of an interruption of early embryonic blood supply of subclavicular artery branches^{5,6}. A combination of the blockage of various branches could lead to different manifestations of the Poland syndrome.

Geneticists currently hold the view that Poland syndrome is rarely inherited and generally is a sporadic event. There are rare instances where more than one individual has been identified with Poland syndrome either in the immediate^{6,9,10} or extended family¹¹. Therefore, some authors believe that an inherited abnormal vasculature formation may be the central underlying mechanism for this condition.

Several reconstructive procedures are available to correct the functional and structural deformities associated with this syndrome. As for the chest deformity, customized silicone prosthesis is simply and safely used. Transposition of the latissimus dorsi muscle for soft-tissue reconstruction has been used by many authors with satisfactory esthetic and functional results¹².

References:

1. Fokin AA, Robicsek F: Poland syndrome revisited. *Ann Thorac Surg* 2002; 74: 903-918.
2. Lagbo JN: Poland syndrome: report of a variant. *J Natl Med Assoc* 2006; 98: 97-99.
3. Ferraro GA, Perrotta A, Rossano F, D'Andrea F. Poland syndrome: description of atypical variant. *AesthPlastSurg* 2005; 29: 32-33.
4. Urschell HC. Poland syndrome. *Chest SurgClin North Am* 2000; 10: 393-403.
5. Bavinch JNB, Weaver DD: Subclavian artery disruption sequence: hypothesis of vascular etiology for Poland, Klippel-Feil and Mobius anomalies. *Am J Med Genet* 1986; 23: 903-918.
6. Cobben JM, Robinson PH, van Essen AJ, van der Wiel HL, ten Kate LP: Poland anomaly in mother and daughter. *Am J Med Genet* 1989; 33: 519-521.
7. Azner JMP, Urbano J, Laborda EG, Moreno PQ, Vergara LF. Breast and pectoralis muscle hypoplasia: a middle degree of Poland syndrome. *ActaRadiologica* 1996; 37: 759-762.
8. Mentzel HJ, Seidel J, Sauner D, Vogt S, Fitzek C et al: Radiological aspects of the Poland syndrome and implications for treatment: a case study and review. *European Journal of Paediatrics* 2002;161:455-459
9. Czeizel A, Vitéz M, Lenz W: Birth prevalence of Poland sequence and proportion of its familial cases. *Am J Med Genet* 1990; 36: 524
10. Hoyme HE, Der Kaloustian VM, Hogg H, Entin MA, Guttmacher AE: Possible common pathogenetic mechanisms for Poland sequence and Adams-Oliver syndrome: an additional clinical observation. *Am J Med Genet* 1992; 42: 398-399.
11. David TJ: Familial Poland anomaly. *J Med Genet* 1982; 19: 293-296.
12. Freitas RS, Tolazzi ARD, Martins VDM, Knop BA, Graf RM, e Cruz GAO. Poland syndrome: different clinical presentations and surgical reconstructions in 18 cases. *AesthPlastSurg* 2007; 31: 140-146.