

# Tuberculous Abscess of the Chest Wall

NK SARKAR<sup>a</sup>, MMR MIA<sup>b</sup>

### Abstract:

*Chest wall tuberculosis (TB) is a rare form of extrapulmonary TB, especially in an immunocompetent patient. The disease may resemble a pyogenic abscess or tumor. We present a young*

*lady who developed a slowly growing chest wall swelling, proven as tuberculous etiology.*

**Key words:** Abscess, chest wall, tuberculosis

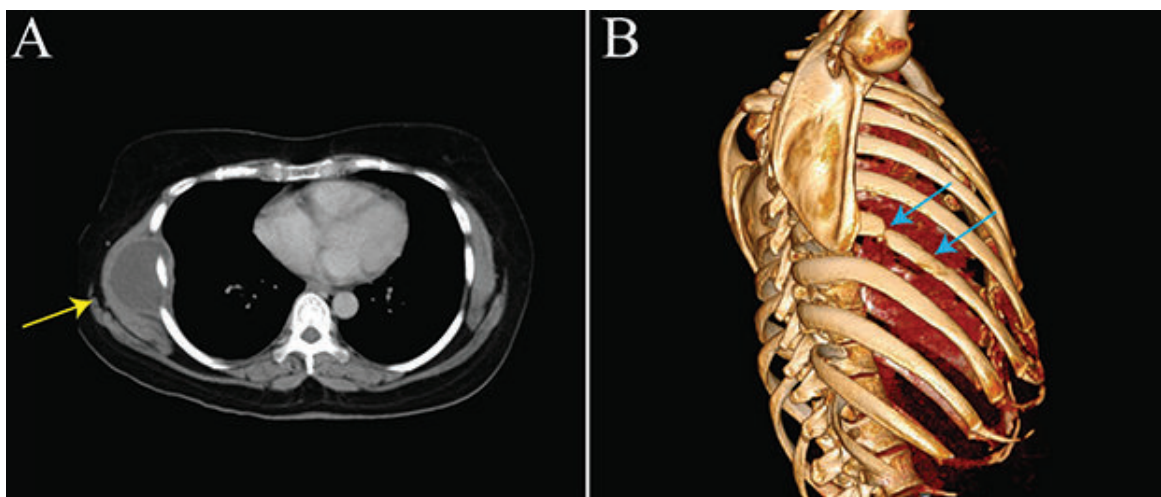
*(J Bangladesh Coll Phys Surg 2022; 40: 136-137)*

DOI: <https://doi.org/10.3329/jbcps.v40i2.58698>

### Case Report:

A 30-year-old lady presented at the outpatient department with a gradually enlarged swelling on the right chest wall which she had noticed 3 months back. She also had low-grade fever and occasional dull-aching pain in the lesion. Examination showed a soft, fluctuating, tender swelling, with raised local temperature over the right lower chest wall in the mid-axillary line. There was no regional lymphadenopathy. She had a diagnosis of right sided tuberculous pleural effusion 6 years back. A

computed tomography scan of the chest revealed a fluid-density lesion measuring about 7.6 X 3.8 cm with peripheral enhancement in the right lateral chest wall (Fig. 1A, yellow arrow), and destruction of the adjacent 7<sup>th</sup> rib (Fig. 1B, blue arrows). Calcified left hilar and few mediastinal lymph nodes were also noted, without any parenchymal or pleural lesion. Debridement of the abscess cavity was performed. Bacterial culture of pus yielded no growth. *Mycobacterium tuberculosis* was detected in the GeneXpert (Cepheid, Inc., USA) of the aspirated material which was rifampicin sensitive. No



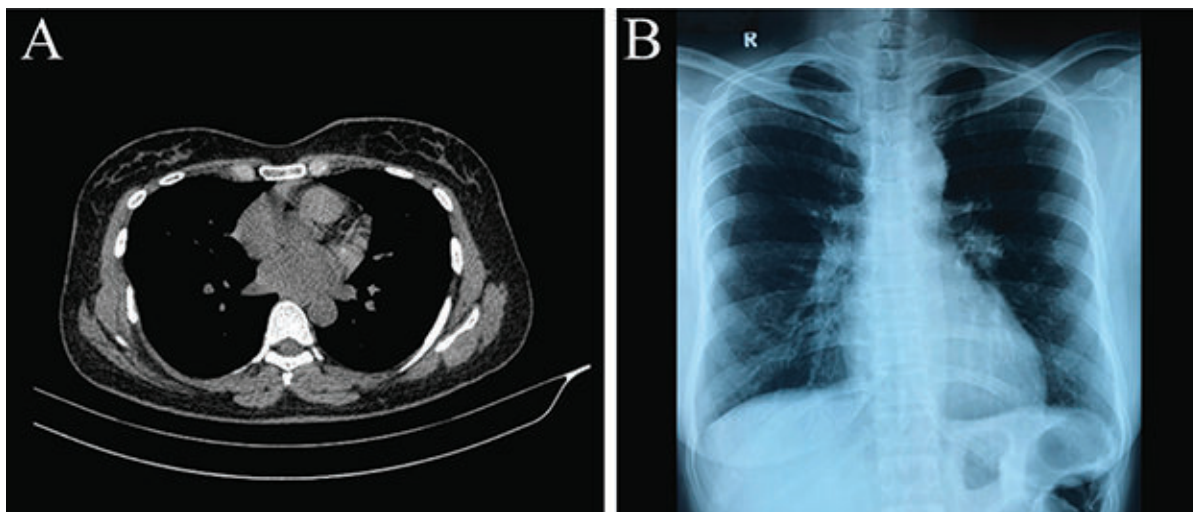
**Fig.-1:** Computed tomography scan of the chest shows a fluid density area about 7.6 X 3.8 cm with peripheral enhancement (yellow arrow) (A), a bony reconstruction shows destruction of the right 7th rib (blue arrows) (B).

- Dr. Nirmal Kanti Sarkar, Assistant Professor, Department of Respiratory Medicine, Mugda Medical College, Mugda, Dhaka - 1214.
- Dr. Md. Mofizur Rahman Mia, Associate Professor, Department of Thoracic Surgery, National Institute of Diseases of the Chest and Hospital, Mohakhali, Dhaka - 1212.

**Address of Correspondence:** Dr. Nirmal Kanti Sarkar, Assistant Professor, Department of Respiratory Medicine, Mugda Medical College, Mugda, Dhaka – 1214, Bangladesh. Phone: +8801711461925, E-mail: [nirmalsarker@gmail.com](mailto:nirmalsarker@gmail.com)

**Received:** 18 Sept., 2021

**Accepted:** 29 Dec., 2021



**Fig.-2:** Follow-up computed tomography scan of the chest (non contrast) (A), and X-ray (B), 7 months later.

granuloma or malignant cell was seen in the histopathology of the bony scraping. HIV serology was negative. The patient was started with rifampicin, isoniazid, ethambutol, pyrazinamide, and levofloxacin. Following 6 months chemotherapy, there was complete resolution of the lesion (Fig. 2A, B).

Chest wall tuberculosis accounts for 1-5% of all musculoskeletal TB. The disease may result from direct inoculation, hematogenous/lymphatic spread, or as an extension of underlying pleuropulmonary and bone TB [1, 2]. Primary involvement of the chest wall is very rare, which in this particular case may be due to reactivation and dissemination of dormant bacilli from the previous disease.

**Conflict of interest:**

There is no potential conflict of interest to declare.

**Disclosure:**

Appropriate written informed consent was obtained for publication of this case report.

**References:**

1. Mathlouthi A, Ben M'Rad S, Merai S, Friaa T, Mestiri I, Ben Miled K, et al. Tuberculosis of the thoracic wall. Presentation of 4 personal cases and review of the literature. *Rev Pneumol Clin.* 1988 Sep; 54:182-6. French. PMID: 9805747
2. Teo THP, Ho GH, Chaturverdi A, Khoo BK. Tuberculosis of the chest wall: unusual presentation as a breast lump. *Singapore Med J.* 2009 Mar; 50:e97-9. PMID: 19352561