

### Pneumopericardium

A DAS<sup>a</sup>, MT MIAH<sup>b</sup>, MA ISLAM<sup>c</sup>, MB ALAM<sup>d</sup>

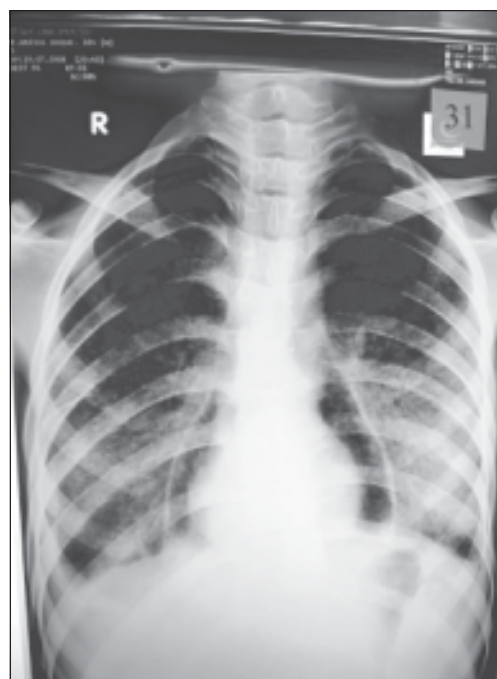
(*J Bangladesh Coll Phys Surg 2012; 30: 112-113*)

Imagings play an important role in diagnosing disease. In spite of sophisticated radiological investigations importance of chest X-ray is unlimited till now. Varsity of radiological findings in chest x-ray has been observed in tuberculosis patient worldwide. Bangladesh is one of the most prevalent country of tuberculosis. This x-ray shows the findings of disease itself as well as complication of treatment.

A 25-year-old man presented with millitary tuberculosis and massive pericardial effusion. After pericardiocentesis patient developed respiratory distress. X-ray chest posteroanterior (P/A) view shows millitary mottlings, left sided mild pleural effusion and a radiolucent shadow surrounding the cardiac border outlined by a fine line representing the pericardial sac. Radiological observation is pneumopericardium after therapeutic pericardiocentesis. It is a rare complication of pericardiocentesis and this type of X-ray chest P/A is found rarely.

Pneumopericardium is defined as the presence of air in the pericardial sac and has been reported to result from a spontaneous or iatrogenic cause of underlying disease.<sup>1,2</sup> There are multiple causes include surgery, penetrating trauma, blunt trauma (rare), infectious pericarditis with gas-producing organisms and fistula formation between the pericardium and an adjacent air-containing organ (i.e. stomach or esophagus). Pneumopericardium has a well-recognized clinical and radiologic entity. Hamman's sign (rarely, Hammond's

sign or Hammond's crunch) is a crunching, rasping sound, synchronous with the heartbeat, heard over the precordium in pneumopericardium and spontaneous pneumomediastinum, produced by the heart beating against air-filled tissues. It is named after Johns Hopkins clinician Louis Hamman. This sound is heard best over the left lateral position. It has been described as a series of precordial crackles that correlate with the heart beat and not with the respirations. It is also heard together with spontaneous small pneumothorax on the left side. Sounds like bubbles hitting inside of the chest can be felt or seen.<sup>3,4</sup> In chest radiographs, a continuous thin radiolucent rim of air follows the cardiac silhouette and is outlined by a fine line representing the pericardial sac.<sup>5,6</sup> The diagnosis of pneumopericardium can be made by conventional chest radiographs only.<sup>7</sup> Pneumopericardium can usually be distinguished from pneumomediastinum, since air in the pericardial sac should not rise above the anatomic limits of the



- Dr. Aparna Das, Assistant Professor, Department of Medicine, Dhaka Medical College,
- Dr. Md. Titu Miah, Assistant Professor, Department of Medicine, Dhaka Medical College,
- Dr. Md. Aminul Islam, IMO, Department of Medicine, Dhaka Medical College, Dhaka
- Prof. Md. Billal Alam, Professor, Department of Medicine, Dhaka Medical College,

**Address of Correspondence:** Dr. AparnaDas, Assistant Professor, Department of Medicine, Dhaka Medical College, M: 01914978719

pericardial reflection on the proximal great vascular pedicle. In our x-ray air shadow doesn't cross the anatomical limit of pericardial reflection. If radiograph is obtained with the patient in the decubitus position, air in the pericardial sac will shift immediately, while air in the mediastinum will not shift in a short interval between films. Occasionally, it may not be possible to distinguish pneumopericardium from pneumomediastinum on plain film, then echocardiography and CT scan of the chest may be needed. This clinical measurement and process is variable, depending on the hemodynamic status of the patient. If the hemodynamic condition is stable, the underlying condition should be treated and the patient should be monitored closely.<sup>1,5</sup> In tension pneumopericardium, rapid fluid resuscitation and emergent echo-guided pericardiocentesis, followed by pericardial drainage, should be performed.<sup>7,8</sup>

The development of a cardiac tamponade is a serious complication, necessitating prompt recognition and treatment. Although severe complications occur in some patients, the iatrogenic pneumopericardium is self-limiting and requires no specific therapy.<sup>5</sup>

#### References:

1. Choi WH, Hwang YM, Park MY, Lee SJ, Lee HY, Kim SW, et al. Pneumopericardium as a complication of pericardiocentesis. *Korean Cir J*. 2011; 41: 280–282.
2. Lee YJ, Jin SW, Jang SH, et al. A case of spontaneous pneumomediastinum and pneumopericardium in a young adult. *Korean J Intern Med*. 2001; 16: 205–209.
3. Ozerkan F, Bilgin M, Oktem MS, Alkan MB. Pneumopericardium after pericardiocentesis: a case report. *Turk Kardiyol Dern Ars*. 2011 Dec; 39(8):697-700.
4. Prasad R, Little M, David S, O'Sullivan M. Acute Pneumopericardium. *J Am Coll Cardiol*, 2011; 57:1399.
5. Brander L, Ramsay D, Dreier D, Peter M, Graeni R. Continuous left hemidiaphragm sign revisited: a case of spontaneous pneumopericardium and literature review. *Heart*. 2002; 88: 85-87.
6. Mayosi BM, Burgess LJ, Doubell AF. Tuberculous pericarditis. *Circulation*. 2005; 112:3608–3616.
7. Buchanan CL, Sullivan VV, Lampman R, Kulkarni MG. Pericardiocentesis with extended catheter drainage: an effective therapy. *Ann Thorac Surg*. 2003; 76:817–820.
8. Naunheim KS, Kesler KA, Fiore AC, et al. Pericardial drainage: subxiphoid vs. transthoracic approach. *Eur J Cardiothorac Surg*. 1991; 5:99–103.