

Isolated Hydatid Cyst of Breast: A Case Report and Review of Literature

S LAL^a, GP SHRIVASTAVA^b

Summary:

Hydatid disease involving the breast is very infrequent. The breast can be a primary site or part of a disseminated hydatidosis. The disease should be considered in the deferential diagnosis of breast lumps especially for those living in endemic areas. Preoperative diagnosis can be made by fine needle aspiration cytology. The breast hydatid disease can be diagnosed by radiologic or serologic means both of which are not definitive. Surgery is the treatment of choice.

Introduction:

Hydatid cyst is a lesion caused by the larval form of *Echinococcus granulosus* and encountered endemically in cattle breeding communities. Humans are occasional intermediate hosts of this organism. The oncospheres, which are ingested, penetrate the intestinal mucosa, enter the blood stream and develop into hydatid cysts in various organ and tissue. The breast is a rare primary site of hydatid cyst that accounts for only 0.27% of all cases.¹ A case of isolated breast involvement that was diagnosed during surgery is presented in this paper and is followed by a discussion on the pertinent clinical aspects.

Case Report:

36-year-old women presented with gradually progressive, painless lump in the left breast since one year. Although, there was pet dog in the family, she also has cattle's in the house. She had no risk factors for breast cancer. On clinical examination her right breast was normal. There was a lump of size 6 x 5x 4 cm present in upper and inner quadrant of left breast. It is firm in consistency, slightly mobile, not fix to underlying structures, margins were well defined, and surface is smooth. Both nipples were normal and she had no

We report a case of isolated hydatid cyst of breast in 36-years-old women, who presented to us with a painless lump in left breast since one year, which was diagnosed incidentally during surgery from its gross appearance which mimics that of a liver hydatid cyst, normally common in this endemic area.

Keywords: Hydatid cyst, Breast lump, *Echinococcus granulosus*

(J Bangladesh Coll Phys Surg 2012; 30: 219-220)

axillary or supraclavicular lymphadenopathy. Her rest of the physical examination was normal. On fine needle aspiration of the lump, 4 ml of clear fluid was obtained. Post-aspiration examination revealed a residual lump, so an excisional biopsy was done. The mass appeared to be a cystic and dense surrounding fibrous tissue. Complete excision was performed. Cut section revealed multilocular cysts measuring 2x1x1cm to 1x0.5x0.5 cm in diameter with a semi translucent, shiny inner surface (Fig. 1) Post operative echinococcal haemagglutination test was positive 1/700, suggesting hydatid disease. Microscopically, the cyst wall was made compressed breast tissue infiltrated by lymphocyte and eosinophils. Laminated membrane was seen within the lumen, made up acellular chitinous material (Fig. 2).

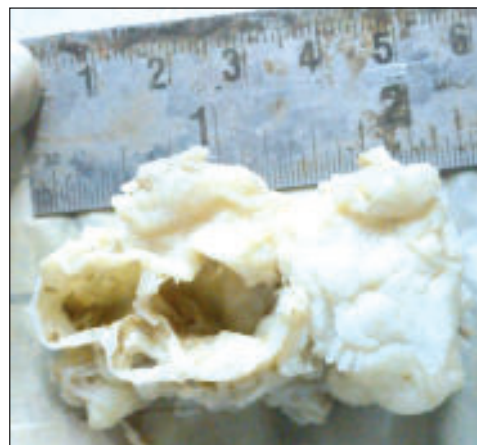


Fig.-1: Cut section of breast tissue, showing multiple cyst with attached fibro fatty tissue.

- Dr. S Lal (MS), Assistant Professor, Department of Surgery, S. S. Medical College, Rewa
- Dr. GP Shrivastava (MS), Professor & Head, Department of Surgery, S. S. Medical College, Rewa

Address of Correspondence: Dr. S Lal, E- 11 Doctor's Colony, Medical college campus Rewa, Madhya Pradesh, Ph; 09301113252, Email; slaldr@gmail.com

Received: 12 July, 2011

Accepted: 10 July, 2012

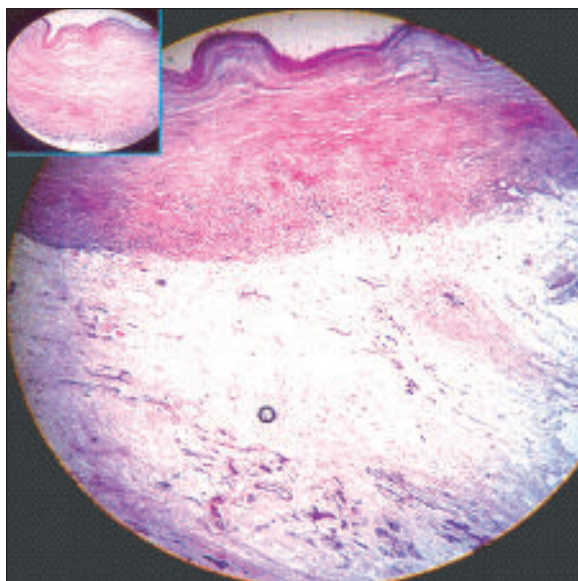


Fig.-2: H & E Section showing normal breast lobule along with cyst wall and peri-cystic mononuclear cell infiltrate .Inset: Cyst wall made up of laminated chitinous material.

Post-operative abdominal ultrasonography, chest radiography, and bilateral mammography did not reveal any other hydatid cyst. She was discharged on the second postoperative day and put on medical treatment in form of Tablet Albendazole 400 mg daily. She remains free of any recurrence 24 months after surgery.

Discussion:

Hydatid disease is a parasitic infection caused by several species of Cestode Echinococcus. The adult E. Granulosus is a worm, when infested it produces eggs that are passed in stool. Eggs infested by intermediate hosts like cows, sheep, and humans, liberate an embryo in the duodenum, which penetrates intestinal mucosa and enters the portal circulation.^{2,3} The liver acts as a first filter and stops about 75%, while lungs, the second filter, stop about 10% and only 15% embryo are free to develop cysts in other organs of the body. According to Barret and Thomas 60% of the cyst are found in the liver, 30% in lungs .25% in kidney, 2.5% in heart and pericardium, 2% in bone, 1.5% in spleen .1% in muscle, and 0.5% in the brain.⁴ The embryo usually develops into a unilocular cyst.⁵ Hydatid disease of breast is rare and account for only 0.27% of all cases. The breast can be a primary site or part of a disseminated hydatidosis.^{1,6} Typically, the patient presents with breast lump which increases slowly in size without regional

lymph node involvement. It generally affects women between 30-50 years of age .It might mimic fibroadenoma, phyllodes tumors, chronic abscesses, or even carcinoma. So breast hydatid cyst should be included in differential diagnosis of breast lump especially in endemic areas^{1,4,6}. Preoperative diagnosis can be made by fine needle aspiration cytology where scolices, hooklets or laminated membrane can be identified.⁷ It is a safe procedure, as no complications were mentioned in the literature^{1,4,8}. The disease can be diagnosed by radiologic or serologic means both of which are not definitive.⁸ Mammography may show a circumscribed mass, the characteristic ring shaped structures inside the mass in over penetrated view strongly suggests breast hydatid cyst.⁹ The ultrasound and Magnetic Resonance Imaging are helpful diagnostic tools.^{4,10} Serology tests such as intradermal and indirect hemagglutination tests may be used to confirm the diagnosis. Surgery is the treatment of choice.

Conclusion:

Hydatid cyst should be considered in the deferential diagnosis of breast lumps especially for those living in endemic areas.

References:

1. Aceptar T, Gomceli I, Güzel K, Yazgan A, Aydın R. Isolated hydatid cyst of the breast. *SMJ* 2003; 48(2):52-53.
2. Garcia G, Shimizu R, Bruckner D. Sinus tract extension of liver hydatid cyst and recovery of diagnostic hooklets in sputum. *Am J Clin Pathol* 1986; 85:519-521.
3. Langer J, Rose D, Keystone J, et al. Diagnosis and management of hydatid disease of the liver. *Ann Surg* 1983; 199(4): 412-417.
4. Das DK, Choudhury U. An unusual breast lump. *JIMA* 2002; 100(5): 327-328.
5. Khatib I, Kharouf T, Kharis M, Khasawneh A. Primary hydatid cyst of breast: Report of two cases. *Jardon Medical Journal* 2003; 37(2): 192- 194.
6. Farrokh D. Hydatid cyst of the breast: A Report of three cases. *Irn J Med Sci* 2000; 25 (1&2): 72-75.
7. Sagin HB, Kiroglu Y, Aksoy F. Hydatid cyst of the breast diagnosis by fine needle aspiration biopsy. A case report. *Acta Cytol* 1994; 36(6):965-9667.
8. Mirdha B, Biswas A. Echinococcosis: presenting as palpable lump of breast. *Indian J Chest Dis Allied Sci* 2001; 43(4): 220-226.
9. Vega A, Ortega E, Cavada A, Garijo F. Hydatid cyst of the breast: mammographic findings. *Am J Roentgenol* 1994; 162:825 -826.
10. Tukul S, Erdan T. Hydatid cyst of the breast: MR imaging findings. *Am J Roent* 1997; 168:1386- 1387.