

Extensive Intra Abdominal Hydatid Cysts

A KUTUB^a, M RAHMAN^b, SN HENA^c

Summary:

Human hydatid cyst is an illness caused by the cystic phase of the small trepanoma, Echinococcus granulosus. It is an endemic disease in some countries of the world. Hydatid disease though known to occur in almost all organs of the body, it is extremely rare in the female reproductive organs. In this report

we present a case of hydatid disease of both ovaries with widespread intraabdominal hydatid cysts. This case was misdiagnosed as an ovarian cyst until the time of operation.

Key words: Hydatid cyst, Echinococcus granulosus, ovaries.

(J Banagladesh Coll Phys Surg 2013; 31: 156-158)

Introduction:

Hydatid disease (also known as *Echinococcosis* or cystic hydatid disease) results from infection with the larvae (a developing phase) of the tapeworm *Echinococcus granulosus*. The tapeworm is found most commonly in dogs that consume organs or meat of infected sheep.¹ Hydatid disease is a zoonotic disease caused by the parasitic tapeworm *Echinococcus granulosus*. Dog is the definitive host harboring the adult worms. The tapeworm grows into adulthood in the intestine of the definitive host & release their eggs in the faeces. These eggs are ingested by the intermediate hosts commonly sheeps, cattle, pigs, horses, camels & human. The eggs hatch in the small bowel, penetrate the gut mucosa & the blood stream from which they are distributed to various sites in the body, where the larva begin to grow & form hydatid cysts. Thus the man acts as an intermediate host. *Echinococcus* cysts are mostly found in the liver (60-90%) followed by the lungs (10-25%), spleen, ovaries, kidneys, brain, bones & heart but rarely elsewhere in the body.² Hydatid disease usually remains asymptomatic unless the cysts grows & produce symptoms due to pressure, rupture to the pleural or peritoneal cavity, secondary infection or an allergic reaction². The involvement of the genital organ

is rare. But can affect ovaries, uterus, & cervix, which can be primary or a secondary site of infection. Plain radiograph & ultrasound scans can reveal thin walled, fluid filled structures.²

Computed tomography may reveal daughter cysts & on magnetic resonance scan magnified images may demonstrate scolices within them. ELISA test, used to detect cyst associated hydatid antibodies are highly sensitive. Surgical excision offers the only hope of cure.³ A common approach is to prepare the patients for operation with albendazole or mebendazole for at least two weeks prior to operation or to give these drugs for nonoperable cases, as in cysts of the brain. Praziquantel is also given preoperatively for two weeks following operation to act against the protoscolices & to reduce the risk of secondary seeding⁴. In cases of cysts in the genital tract surgical excision is the treatment of choice.⁴ Here we report a case of extensive intraabdominal hydatid cysts with involvement of both ovaries. & is one of the extremely rare involved sites.

Case Report:

Mrs. Sharifa 37 years young housewife of lower middle socioeconomic class was admitted with pain in the lower abdomen for two years & progressive enlargement of abdomen for one year. Pain was diffuse, dull aching non radiating. Bowel & bladder habit was normal. She was mildly anaemic, non icteric. Whole abdomen was occupied with multinodular cystic mass. Pelvic examination revealed multiple cystic structures of unusual feelings in the posterior fornix. USG of whole abdomen revealed hepatomegaly with multiple small hepatic cysts, polycystic left kidney with multiple big size cystic structures in both adnexa. CA 125 was 129

- Dr. Afroza Kutubi, Asstt. Prof. Gynae, Dhaka Medical College.
- Dr. Md. Mustafizur Rahman, Asstt. Prof. Surgery Shahid Shuhrawardi Medical College.
- Prof. Shamsunnahar Hena, Prof. & Head Department of Obst. & Gynae Sir Salimullah Medical College.

Address of Correspondance: Afroza Kutubi, Asstt. Professor, Gynae, Dhaka Medical College, Phone-01715016009, Email- dr.afroza74@yahoo.com.

Received: 25 March, 2012

Accepted: 12 April, 2013

mu/ml. Barium follow through was normal. She was diagnosed as a case of ovarian tumour & laparotomy was done. Moderate amount of straw coloured ascitic fluid was found in the peritoneal cavity. Almost whole of the abdominal cavity was filled with multiple cystic structures of varying sizes & shapes. Omentum was studded with multiple cysts. Surface of the liver was also occupied by numerous cysts. Both ovaries were replaced by multiloculated cysts of varying sizes. Peroperatively it was diagnosed as a case of hydatid cyst involving both ovaries, pouch of douglous, liver ,kidneys, omentum & under surface of the diaphragm.

Cyst wall was thick , white & there were three to four daughter cysts present within the mother cyst. Abdominal cavity was packed with hypertonic normal saline to prevent accidental spillage.

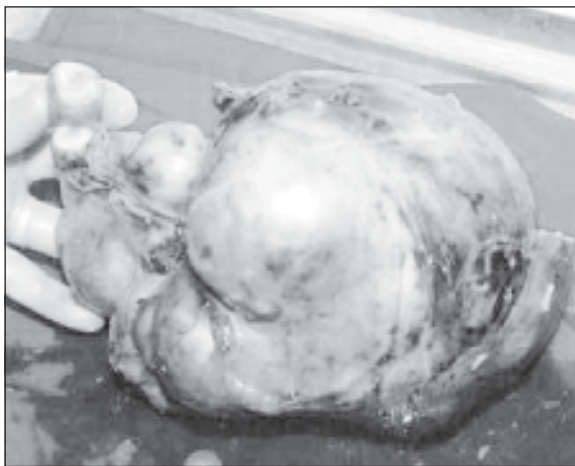


Fig-1: Whole of the ovary was replaced by hydatid cyst

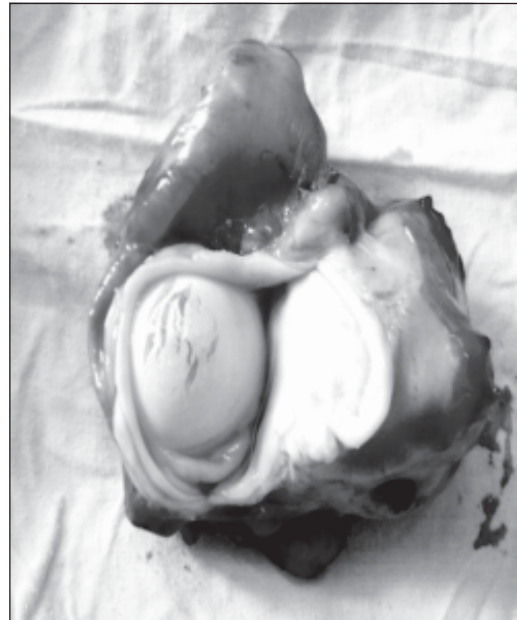

Fig-3: Cut section of a mother cyst showing daughter cyst within it.

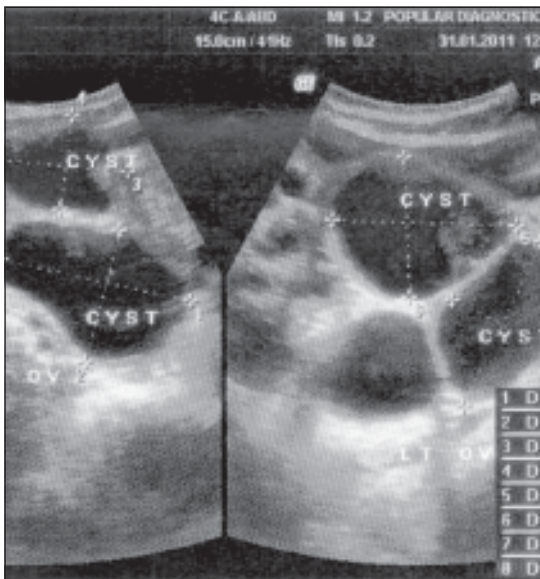


Fig-2 USG findings of ovarian cyst




Fig-4 : Per operative findings of multiple hydatid cysts in omentum

Total abdominal hysterectomy with bilateral salphingoophorectomy & Omentectomy was done, as it was very difficult to remove only the cyst after preserving the uterus and ovaries. Histopathological report revealed hydatid cysts. Postoperatively tablet

Albendazole 400 mg twice daily was started & patient had uneventful recovery. Patient was discharged on 8th postoperative day. She came for follow up after one & six months and there was no evidence of recurrence or persistence of hydatid cyst by clinical examination and ultrasonography.

Discussion:

Hydatid disease is endemic in the Middle-East as well as in some parts of the world, including India, Africa, South America, New Zealand, Australia, Turkey & Southern Europe.⁵ The high prevalence of the disease in these countries are due to close contact of human with the domestic animals from which they make their livings. When eggs are ingested by the intermediate hosts, the embryo escape, penetrate the intestinal mucosa, enter the portal circulation & are then trapped in the liver. Rarely a small number escape the hepatic filter enter the systemic circulation & are scattered to other organs. Primary involvement of genital organ is very rare. The incidence of hydatid cyst formation in the female reproductive organ is much less 0.5% of all hydatid cysts.⁶ Farzaneh Mohammadi & colleagues⁷ reported a case of large hydatid cyst of ovary where laparotomy was performed due to CT scan findings of a large multisepted cystic mass in pelvic cavity.

Total abdominal hysterectomy & bilateral salpingo-oophorectomy & resection of the left ovarian mass was done & histopathological report revealed typical germinated & laminated layers with hexagonal scolices of hydatid cysts. Saeed Abu Eshy & colleagues⁸ reported a case of hydatid cysts in the liver in a 32 weeks pregnant woman & the patient had undergone laparotomy & endocystectomy was accomplished with keeping the pregnancy uninterrupted. She had a smooth postoperative recovery. Ishraq Dhaifalah⁹ reported a case of hydatid cyst in the uterine cervix. It was a very rare case of primary involvement of the uterine cervix & it was diagnosed as an ovarian cyst until the time of operation. The cyst was accidentally ruptured & difficult to excise due to adherence of the right ovary. Nusrat & Colleagues¹⁰ reported a case of hydatid cyst in the uterus of an unmarried girl presented with menorrhagia & lump in the lower abdomen. Uterus was explored by laparotomy & many endocysts were found within the uterine cavity. Endocystectomy performed & pt. had a smooth recovery. A. Basguly & Colleagues¹¹ also reported a case of hydatid cyst of the uterus of a postmenopausal woman who had a history of hydatid cyst of the liver & surgical management was performed twice due to recurrence. She was presented with pain in

the lower abdomen. Transvaginal sonography revealed a cystic mass within the uterus. Subtotal hysterectomy performed & histopathology confirmed the presence of scolices of *Echinococcus granulosus*. This case report is also interesting for extensive nature of hydatid cysts involving almost whole of the abdominal cavity, liver kidney & both the ovaries. Hydatid cysts were not suggested by the imaging studies & it had a clinical impression of malignant ovarian tumour.

Conclusion:

Hydatid cyst in the genital tract is very rare & correct diagnosis is very difficult due to striking resemblance between hydatid cyst & malignant disease of the related organ. To avoid misdiagnosis a careful examination of pelvic masses should be carried out in endemic areas. The mainstay of treatment is surgical excision followed by mebendazole or albendazole for four to five months to prevent its recurrence. Until the physician lacks the high index of suspicion the lesion may be misdiagnosed as a pelvic malignancy. Therefore hydatid cyst should be considered in the differential diagnosis of cystic pelvic masses & gynaecologists should be aware about the possibility of hydatid cyst when a septated mass is found in the pelvis.

References:

1. Hydatid Disease (Echinococcosis). Iechyd Cyhoeddus Cymru Public health wales 2013 <http://www.wales.nhs.uk/sites3/images/4571ogonew.jpg>
2. Tsaroucha AK, Polycronidis AC, Lyrantzopoulos N, Pitiakoudis MS, Karayiannakis AJ, Manolus KJ, et al. Hydatid disease of the abdomen & other locations. *World J Surg* 2005;29:1161-5.
3. Bannister B, Begg N, Gillespie S. (2000) *Infectious disease: second edition*, P 506 Blackwell Science, United Kingdom.
4. Rofo, Echinokokkuszyste and Uterus myomatosus. *Fortschritte auf dem Gebiete der Rontgenstrahlen und der neuen bildgebenden Verfahren (Germany)* 1997; 166: 590-593.
5. Goel MC, Agarwal MR, Misra A. Percutaneous drainage of renal hydatid cyst: early result & follow-up. *Br.J Urol* 1995; 75:724-8.
6. Shashtri A, Sutaria UD, Bhosle RA. Hydatid disease in Gynaecological Practice. *J Obstet Gynaecol India* 1985; 35: 749-53.
7. Zia FM, Mousavi SJ. Large hydatid cyst of ovary. *Pak J Med Sci* 2011;27(1) : 226-228.
8. SA Eshy, ME Ali. *Annals of Saudi Medicine*, 1999; (19)2.
9. I Dhaifalah. *Biomed Papers* 2001; 145(2): 77-780.
10. NA Yousuf & Colleague Hydatid cyst in the uterus of a young lady *Bangladesh Medical Journal* 2011; 40(2).
11. Basguly A, Kavak ZN. Hydatid cyst of the uterus. *Infect Dis Obstet Gynaecol* 2002; 10:67-70