

# Rare Association of Gullain- Barré Syndrome with Non-Hodgkin's Lymphoma: A Case Report

NC KUNDU<sup>a</sup>, KMNI JOY<sup>b</sup>, M SEN<sup>c</sup>, FA QURAIISHI<sup>d</sup>

## Summary:

*Guillain-Barré Syndrome (GBS) is a very common cause of acute motor neuropathy in medical ward, though its association with lymphoma is not very common. Here we present a case of acute motor neuropathy which was clinically diagnosed as a case of GBS. CSF (Cerebrospinal fluid) study and electrophysiological study supported the clinical diagnosis. The patient also had generalized*

*lymphadenopathy & histopathological examination of lymph node revealed high grade Non-Hodgkin's Lymphoma (NHL). A staging bone marrow study was performed which revealed lymphoreticular malignancy. The case was finally diagnosed as GBS with stage IV Non-Hodgkin's Lymphoma.*

*Key word: Guillain- Barré Syndrome (GBS), Non-Hodgkin's lymphoma (NHL), Association.*

*(J Bangladesh Coll Phys Surg 2013; 31: 168-173)*

## Introduction:

Gullain- Barré Syndrome (GBS) is an acute, frequently severe and fulminant demyelinating polyradiculoneuropathy that is autoimmune in nature. It is characterized by a rapidly ascending muscle weakness or paralysis accompanied by absent or depressed deep tendon reflexes and in some cases, by respiratory distress. Abnormal immune response against target epitopes in Schwann cell surface or myelin (demyelinating form-85%) or epitopes in axonal membrane (acute axonal form-15%) through both humoral and cell mediated mechanisms is the proposed aetiopathogenesis to explain GBS<sup>1, 2, 3</sup>.

Approximately 70% of cases of GBS occur 1-3 weeks after an acute infectious process, usually respiratory or gastrointestinal<sup>4, 5</sup>. Culture and seroepidemiologic techniques show that 30% cases are preceded by infection or reinfection by *Campylobacter jejuni*<sup>4</sup>. Other factors that play role in triggering immune

response for GBS are herpes simplex virus, CMV or Epstein-Barr virus, Mycoplasma pneumonia and some vaccines like swine flu vaccine, influenza vaccine & nerve tissue rabies vaccine. GBS can also occur more frequently than can be attributed to chance alone in patients with lymphoma (including Hodgkin's disease), in HIV-seropositive individual and in SLE patients<sup>4</sup>. Linkage of GBS with several other malignancies has been reported as possible paraneoplastic complications such as breast carcinoma, small cell carcinoma of the lungs, renal carcinoma and rarely in esophageal carcinoma<sup>2, 6, 7, 8</sup>. The effects of lymphoma on the peripheral nervous system have been reviewed in some articles. Many reports have been issued on GBS in association with Hodgkin's disease, but its association with Non-Hodgkin's Lymphoma (NHL) is relatively rare. A few cases of NHL reported developed acute motor neuropathy after or during receiving CHOP chemotherapy for the malignancy attributable to either chemotherapy induced polyneuropathy or demyelinating polyradiculoneuropathy (GBS)<sup>3, 9</sup>. We presents a case of acute motor neuropathy, likely GBS, with concomitant incidental finding of generalized lymphadenopathy which was later proven to be a case of NHL. It stresses the possibility of the occurrence of GBS in a patient of NHL and suggests that the full spectra of these disease entities are yet to be fully defined.

## Case Report:

A 45 years old male smoker, day laborer, normotensive non-diabetic patient hailing from Jurain, Dhaka, was admitted in the neurology department of SSMC Mitford hospital on 1<sup>st</sup> September 2011 with the complaints of low grade intermittent fever for two months, progressive weight loss for the same duration and sudden weakness of all four limbs for last seven days. Fever came at

- a. Dr. Narayan Chandra Kundu, Associate Professor, Department of Neurology, Sir Salimullah Medial College & Mitford Hospital, Dhaka.
- b. Dr. K.M. Nazmul Islam Joy, Assistant Register, Department of Neurology, Sir Salimullah Medial College Mitford Hospital, Dhaka.
- c. Dr. Moushumi Sen, Assistant Professor, Department of Biochemistry, Anwer Khan Modern Medical College, Dhanmondi, Dhaka.
- d. Dr. F.A. Quraishi, Professor of interventional neurology, National institute of neurosciences and hospital, Dhaka.

**Address of Correspondence:** Dr. Narayan Chandra Kundu, Associate Professor, Department of Neurology, Sir Salimullah Medial College & Mitford Hospital, Dhaka.

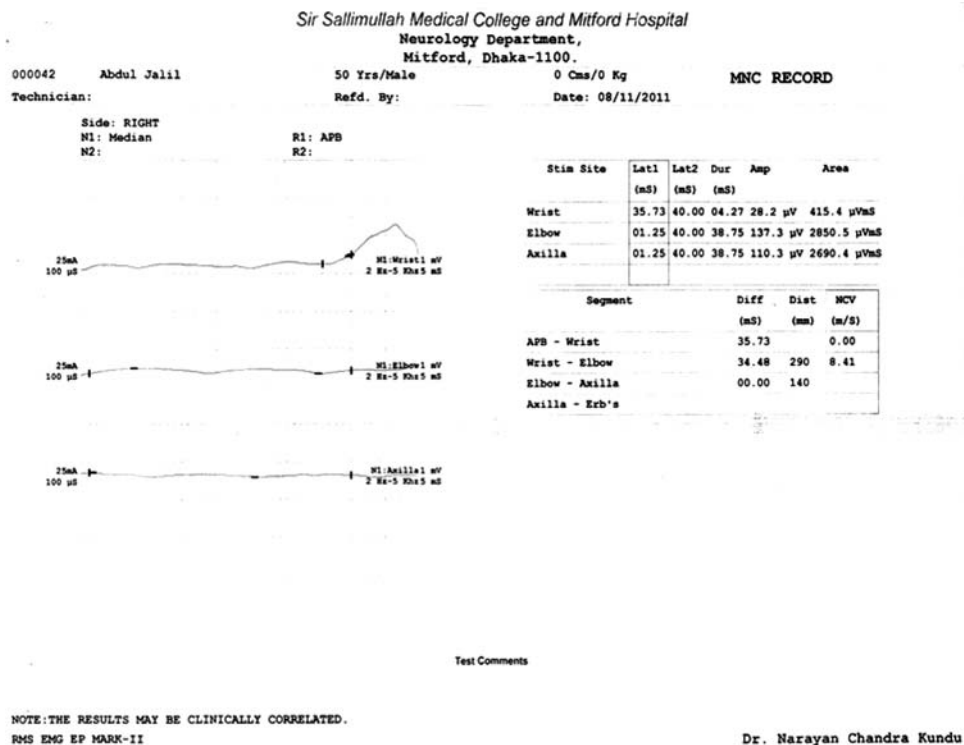
**Received:** 26 November, 2012      **Accepted:** 17 February, 2013

evening, was not associated with chill and rigor or any other organ specific symptoms & subsided spontaneously without sweating. He had no history of contact with known patient of TB. He noticed progressive loss of body weight in the last 2 months which was associated with loss of appetite but not with polyuria, polydipsia, heat intolerance or palpitation. One week ago he developed sudden weakness of left lower limb with diffuse dull aching pain. Weakness progressed to affect all four limbs in a period of 3-5 days and affected both proximal & distal muscles simultaneously. There was no bowel and bladder involvement or any definite sensory complain. There was no recent history of upper respiratory tract infection, diarrhoea or vaccination. There was no history of exposure to any chemical, toxin or drug.

On examination, the patient was cachectic & mildly anaemic & had generalized lymphadenopathy involving cervical and inguinal groups. Lymph nodes were in variable sizes and shapes, non-tender, firm in consistency, not fixed to underlying structure or skin. Liver was enlarged, non-tender, 7.5 cm from right subcostal margin in right mid-clavicular line, firm in consistency with a sharp margin with absent hepatic bruit. Spleen was also enlarged, 3.5 cm from left costal

margin along its long axis, firm in consistency. Higher psychic function with speech and cranial nerves including fundus were normal, motor examination revealed flaccid quadriparesis (muscle power 0/5 both proximally and distally both side) with absence of all deep tendon reflexes. Planter response was absent on both sides. Sensory system was intact. Clinically the patient was diagnosed as a case of GBS.

Complete blood picture of the patient revealed Hb% - 09 gm/dl, ESR 08 mm in 1<sup>st</sup> hour and normal cell counts with a normal peripheral blood film. On biochemical screening RBS, SGPT, serum creatinine and serum electrolytes were normal. CXR P/A view & urine for R/M/E were also normal. USG of whole abdomen revealed hepatosplenomegaly with normal echo texture. MT (Mantoux test) was negative. HIV-1 and HIV-2 screening test was negative. CSF study was performed on the 10th day of onset of weakness which demonstrated albumino-cytological dissociation (protein 105 mg/dL and cell counts 10 cells/cmm, all lymphocytes) while other parameters were within normal limits. Nerve conduction study (crossed limbs) showed evidence of mixed peripheral neuropathy, both axonal and demyelinating, with evidence of radicular involvement (Fig 1- 4.)



**Fig.-1: MNC record of right median nerve at wrist**

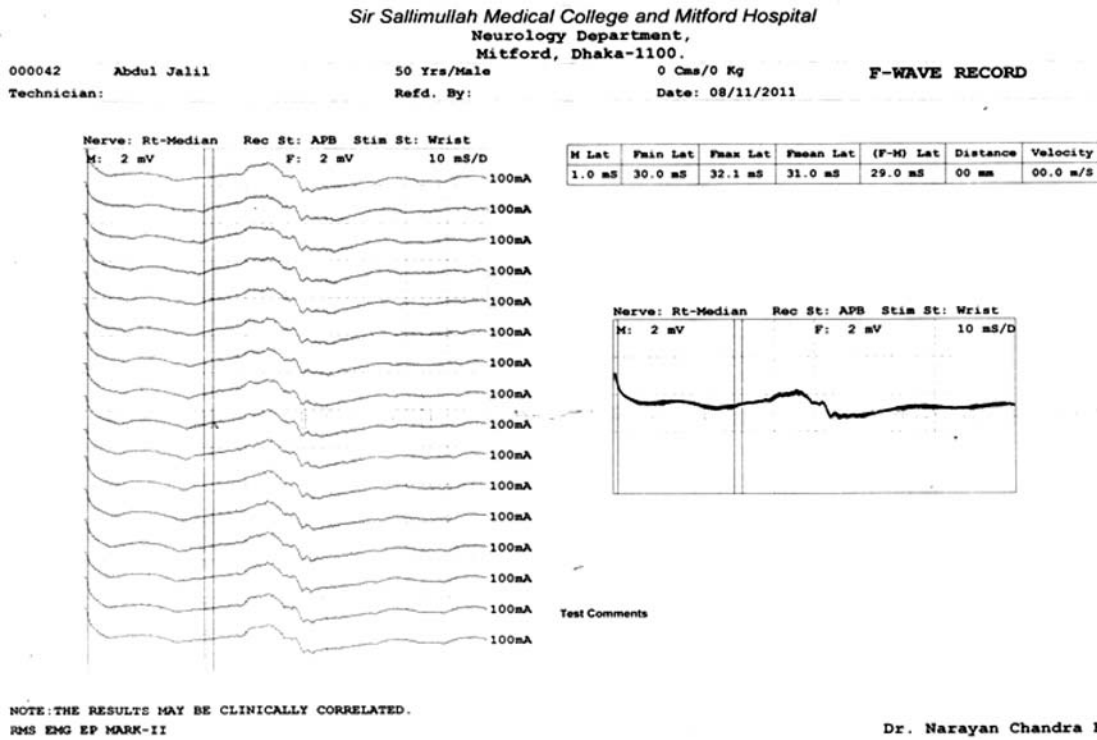


Fig-2: F wave study of right median nerve

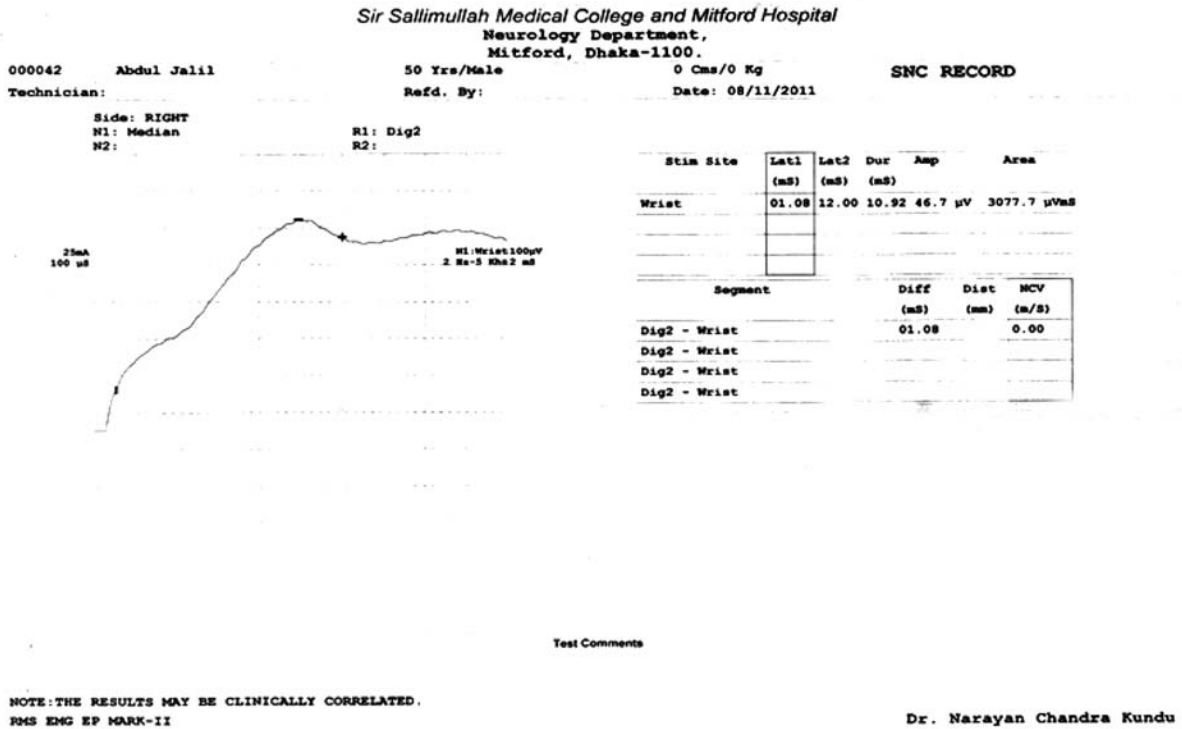
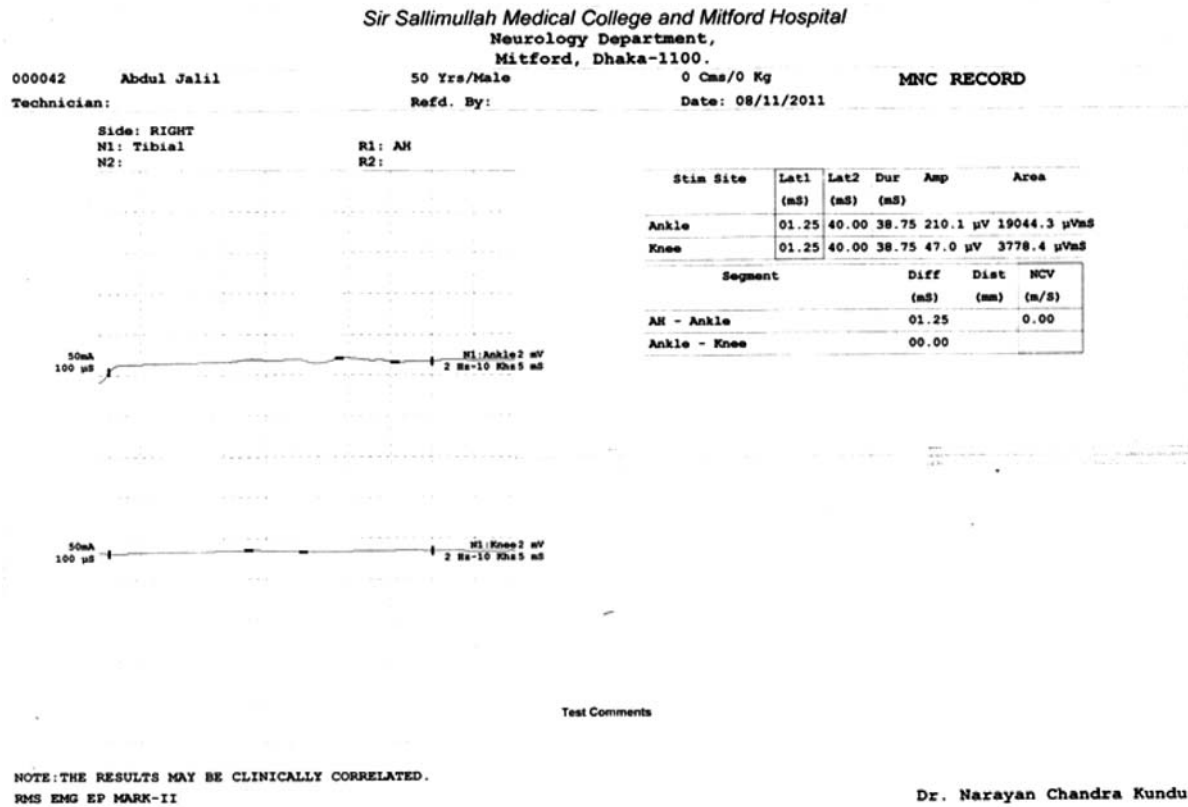
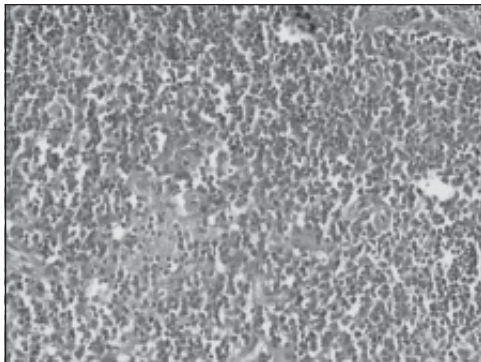


Fig-3: SNC record of right median nerve at wrist

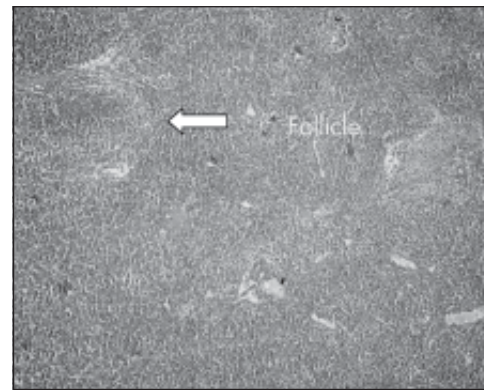


**Fig.-4:** MNC record of right tibial nerve at ankle

The clinical diagnosis of GBS was made according to international criteria. Later, a biopsy of right anterior chain of cervical lymph node was done and histopathological study was compatible with Non-Hodgkin's Lymphoma, high grade follicular type, with areas showing hemorrhage, fibrosis and crushing effects (Fig 5-6). A staging Bone Marrow (BM) study was performed which revealed evidence of



**Fig.-5** Sections of the lymph node show monotonous population of neoplastic lymphocytes (H & E stain 40X).



**Fig.-6** Section of the lymph node shows neoplastic follicles (H& E stain 10X)

lymphoreticular malignancy, suggesting BM metastasis. The patient was finally diagnosed as GBS with high grade NHL (stage IV). Initially only supportive treatment and physiotherapy was given to the patient. Indicated treatment option for the patient like Intravenous Immunoglobulin (IVIg) or plasmapheresis was not possible due to financial

constrains of the patient. He was planned for total 6 cycles of chemotherapy with CHOP (Cyclophosphamide, Doxorubicin, Vincristine, and Prednisolone) along with intrathecal methotrexate in consultation with the hematology department.

### Discussion:

NHL is a neoplastic transformation of cells that reside predominantly within lymphoid tissues which may be of B or T cell origin. There is a slight male to female predominance and incidence steadily rises with age, especially after 40 years. Unlike Hodgkin's disease, NHL is much less predictable and has a greater predilection to involve extra nodal sites. It has been estimated that the nervous system is involved in about 10-25% of cases of NHL.<sup>10</sup> Primary Central Nervous system (CNS) involvement results in headache, seizures, lethargy, focal neurological symptom or paralysis. Uncommon CNS manifestation may include lymphomatous meningitis and spinal cord compression. On the other hand, peripheral nervous system involvement occurs in 5% patients with lymphoma and has a wide differential diagnosis, with Herpes Zoster being the commonest cause<sup>9</sup>. Five distinct types of polyneuropathy occur as an occasional remote accompaniment of lymphoma—GBS, chronic relapsing inflammatory demyelinating polyradiculoneuropathy (CIDP), paraneoplastic sensory neuropathy, sub acute motor neuropathy and diffuse infiltration of nerves by NHL<sup>11</sup>. However, the differential diagnosis of peripheral neuropathies in NHL depends on the clinical settings and mainly includes drug (chemotherapy) toxicity and nerve infiltration by lymphoma -both of which have been well described<sup>3,12</sup>. Besides these, plexopathy, mononeuropathy, vasculitis and paraproteinemic deposition have all been postulated as the underlying etiology of acute neuropathies in NHL.

The Guillain-Barré Syndrome and chronic relapsing inflammatory demyelinating polyradiculoneuropathy (CIDP) probably reflect disordered immune regulation<sup>11</sup>. It seems likely that malignant tumors act as sources of the antigenic factors that are responsible for initiating an immune response in the nervous system, later manifesting as GBS<sup>3</sup>. Another theory is that selective depression of cell mediated immunity of any etiology might allow the development of a humoral and or cellular immune reaction directed against peripheral

nerve antigens. There might also be other epigenetic factors that contribute to the development of GBS in any particular immune-compromised patient<sup>13</sup>.

Chemotherapy, especially with vinca alkaloids (vincristine, vinblastine etc) is probably the most common cause of peripheral neuropathy in patients with lymphoma. In fact, only 01 patient with NHL has been reported to develop GBS before the diagnosis and initiation of chemotherapy; all the rest developed GBS after initiation of CHOP or other chemotherapies<sup>13</sup>. Chemotherapy induced peripheral neuropathy (CIPN) manifest as painful dyesthesias and distal symmetrical sensorimotor neuropathy, predominantly involving large diameter fibers during the early stages. Nerve biopsy is a distinguishing point between GBS and CIPN (neurofilamentous accumulations within the axons are characteristic of CIPN, whereas GBS is characterized by intense lymphocytic infiltrations in the nerve roots and peripheral nerves (demyelinating type) or macrophages invading the periaxonal spaces of myelinated fibers (axonal type)<sup>13</sup>. However, GBS may occur even in a patient who received chemotherapy for NHL. The immunosuppressive status induced in these cases by the treatment could have confounded the real action of the malignancy in the development of GBS by enhancing the immunological-mediated myelin damage catalyzed normally by the tumor epitope<sup>13</sup>.

Diffuse and direct infiltration of peripheral nerves by NHL can produce a progressive, painful and asymmetrical polyneuropathy. This is termed as neurolymphomatosis and is a rare event, often occurring in the presence of widespread systemic disease<sup>9,11</sup>.

Paraneoplastic neuropathy is a heterogeneous group of conditions that often presents as a sub acute sensory neuropathy. Less frequently seen paraneoplastic presentations include motor sensory neuropathies, autonomic neuropathies and lower motor neuron syndromes<sup>13</sup>. Paraneoplastic syndrome is extremely rare in cancer patients with an estimated incidence of about 7%<sup>2</sup>. The commonly proposed criteria to define a paraneoplastic disease are based on the increased incidence of a specific cancer in a population affected by a particular neurological disorder, the short latency between the onset of the neuropathy, the presence of specific onco-neural antibodies directed against antigens expressed by the tumor and the nervous system cells

and the absence of other causes explaining the pathogenesis of the neuropathy<sup>2</sup>. However in contrast to other neurological syndromes which usually express onco-neural antibodies, tumor associated GBS has no specific serological profile to be used in clinical practice. So, defining GBS as a paraneoplastic syndrome is not always conclusive.

In the presented case, our first clinical impression was acute motor neuropathy (GBS?) with lymphoma. The differentials included paraneoplastic motor neuropathy due to any malignancy. Toxic or metabolic causes of the neuropathy were excluded as far as possible. CSF and NCS study suggested that it was a case of polyradiculoneuropathy (both demyelinating and axonal). As lymph node biopsy revealed the histological proof of NHL, a diagnosis of GBS in association with NHL was made, which is a rare one. The cause of this GBS was obviously not due to chemotherapy or neurolymphomatosis. The nature of this relationship, whether, paraneoplastic or an immunologic association remains uncertain.

#### Conclusion:

In conclusion, we reported this case as an uncommon association between NHL and GBS, which was diagnosed concomitantly at the first presentation in a 45 years old male patient. Most reported GBS cases associated with NHL was diagnosed after receiving chemotherapy. The study stresses that a GBS neuropathy of undetermined origin may be associated with underlying malignancy and NHL, though rare, must be included in the differential diagnosis. The study might also provide further insight into the underlying etiology of this syndrome and lead to the development of targeted immunomodulatory therapies that are more specific, less toxic and more beneficial than those currently available.

#### References:

1. Wilson HJ. The immunobiology of Guillain Barre Syndromes. *J Peripher Nerv Syst*,2005;10:94-112.
2. T.Zilli, A.S.Allal. Guillain Barré syndrome as an atypical manifestation of an esophageal carcinoma. *Neurological Sciences-Official Journal of the Italian Neurological Society*,2010-10.1007/s10072-010-0363-9
3. Jun-Hwa Song MD, Gun Wook Park MD,PhD, Young Joo Sim MD,PhD, Jae Yong jeon MD, Seong Jae Lee MD,PhD, Jung Keun Hyun MD,Phd, Yoon-Young Cho MD & Sung-Dong Park MD. Guillain Barré Syndrome Associated With Non-Hodgkin's Lymphoma. *Korean J Hematol*, 2008; 43(4): 263-267
4. Stephen L.Hauser, Arthur K.Asbury : Guillain- Barré Syndrome and other Immune-Mediated Neuropathies. In Anthony S.Fauci MD,Eugene Braunwald MD, Dennis L.Kasper MD, Stephen L.Hauser MD, Dan L.Longo MD, J.Larry Jameson MD,PhD, Joseph Ioscalzo MD,PhD ed.Harrison's Principles of Internal Medicine.17<sup>th</sup> edition. 2008. McGraw-Hill.USA.Pp-2667-2672
5. C.M.C.Allen,C.J.Lueck,M.Dennis :Neurological disease.In Nicki R.Colledge BSc FRCP,Brian R.Walker BSc,MD,FRCP, Stuart H.Ralston MD,FRCP,FMedSci FRSE ed. Davidson's Principles and Practices of Medicine.21<sup>st</sup> edition.2010. Churchill Livingstone.UK.Pp-1229
6. Halls J,Bredkjaer C,Friis ML:Guillain Barré Syndrome: Diagnostic criteria, epidemiology, clinical course and prognosis.*Acta Neurol Scand*,1988;78:118-122
7. Mineo T C, Biancari F,Casciani CU: Polyradiculoneuritis as an initial manifestation of bronchial carcinoma, 1995; 109:1254
8. Swan C H, Wharton BA;Polyneuritis and renal carcinoma, 1963; *Lancet* 2; 383-384.
9. Firas Seffo MD,Hamed A.Daw,MD.2010 Mar;8(3): Non-Hodgkin's Lymphoma and Guillain Barré Syndrome:A Rare Association. *Clinical advances in Hematology and Oncology*. 2010 Mar;8(3):201-205
10. Whisnatt JP, Siekert RG, Sayre GP. Neurologic manifestations of the lymphomas. *Med Clin North am* 1956;40:1151-61
11. Michael Donaghy: Polyneuropathy. In Michael Donaghy ed. *Brain's Diseases of the Nervous System*.12<sup>th</sup> edition. 2009. Oxford University Press.UK. Pp-575
12. Re D Schwenk A, Hegener P, Bamborschke S, Diehl V, Tesch H. Guillain-Barré Syndrome in a patient with Non-Hodgkin's Lymphoma. *Ann Oncol* 2000;11:217-20
13. Re Sindhu Ramchandren MD,MS,Robert P Lisak MD.The Immunopathogenesis of Guillain Barré Syndrome. *Clinical advances in Hematology and Oncology*. 2010 Mar;8(3): 206-208.