

Non-Hodgkin's Lymphoma of Maxillary Sinus

A DAS^a, G BANIK^b, MH CHOWDHURY^c

(*J Bangladesh Coll Phys Surg 2013; 31: 174-175*)

A 50-year-old, business man hailing from South Kafrul, Dhaka, non-diabetic, normotensive non-smoker having complaints of teeth ache and swelling of right cheek for 2 months. Pain was dull in nature, intermittent, not associated with dental anomaly or dental infection or bleeding from gums. Swelling was gradually increasing in size, nontender, overlying skin is normal and not associated with discharge or ulceration. Initially it was soft and later it became hard. He had no history of fever or associated joint pain. He also gave history of 14 kg weight loss within one month. On examination, he was mildly anaemic, palpable lymph node on both submandibular region which are firm in consistency, nontender, and mobile. A swelling in right cheek about 10X7 cm, non-tender and hard in consistency and the skin color over the swelling is normal. There was no discharging sinus. The clinical differential diagnosis included the most common malignancies in the oral cavity such as squamous cell carcinoma (SCC), carcinoma of the maxillary sinus and minor salivary gland tumor.

Investigations revealed normal complete hemogram, blood sugar, and liver and kidney function tests. X-ray PNS showed opacification in right maxillary sinus. Computed tomography (CT) scan revealed a large soft tissue mass in the right maxillary sinus, extending medially into right nasal cavity and superiorly into right orbit and anteriorly to right side of face, and causing destruction of all walls of right maxillary sinus, right side of upper alveolar process. Next FNAC was done for histopathological evaluation, which showed malignant neoplasm composed of monotonous population of anaplastic lymphoid cells. The tumor is of intermediate grade and is infiltrated within the

1. Dr. Aparna Das, Assistant Professor, Dept. of Medicine, DMC
2. Dr. Gobinda Banik, Assistant Professor, Dept. of Medicine, Kustia Medical College
3. Maruf H Hassan, Registrar, Dept. of Medicine, DMC

Address of Correspondence: Dr. Aparna Das, Assistant Professor, Dept. of Medicine, DMC

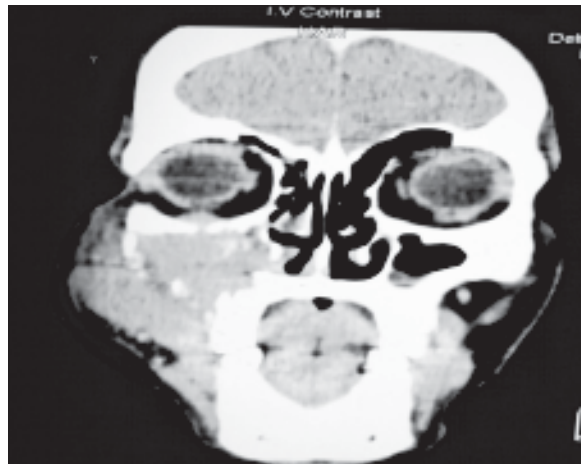


Fig-1: Computed tomography (CT) scan revealed a large soft tissue mass in the right maxillary sinus, extending medially into right nasal cavity and superiorly into right orbit and anteriorly to right side of face, and causing destruction of all walls of right maxillary sinus, right side of upper alveolar process.

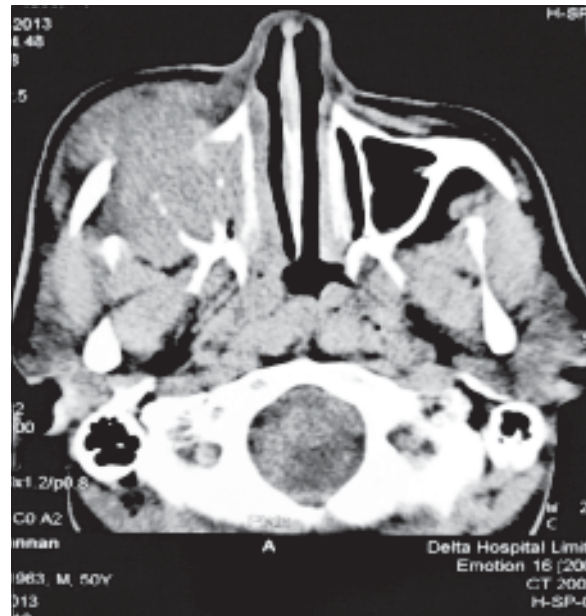

Fig-2: Computed tomography (CT) scan revealed a large soft tissue mass in the right maxillary sinus.

underlying skeletal muscle. Suggestive of non hodgkin's lymphoma of intermediate grade. Chest X-ray , Ultrasonography of abdomen were normal and bone marrow examination revealed nonspecific findings.

Discussion:

Forty percent of Non-Hodgkin's lymphoma arises from extranodal sites. The nasal cavities and paranasal sinuses are rarely affected by primary NHL. Common primary extranodal sites of lymphomas include stomach, liver, soft tissue, dura, bone, intestine and bone marrow. In Western populations, lymphomas of the maxillary sinus are more common than in the nasal cavity. On the contrary, in Asian patients the nasal cavity is more common as a primary site than the maxillary sinus^{1,2,3}. More than 60% of NHLs of the head and neck occur in extra nodal sites, such as the paranasal sinuses, nasal cavity, oral cavity, salivary glands, and laryngopharynx⁴. Most patients present with rapidly enlarging masses, often with symptoms both locally and systemically (fever, recurrent night sweats, or weight loss). Clinically and radiographically, the manifestation is usually similar to squamous cell carcinoma (SCC) or to an odontogenic tumor, cyst, or infection. Lymphomas are usually submucosal, and on gross appearance, differ from SCC which is usually ulcerative. Our case clinically manifested as non-ulcerated growth closely resembling SCC, and it was very difficult to differentiate both of the lesions clinically. Generally histopathological results are assumed to be standard for final diagnosis . Moreover the lesion was spreading on medial as well as lateral sides of left maxillary sinus equally which again created a doubt about its origin. Though

histopathology and immunohistochemistry examination should be performed to ensure the accurate diagnosis and histological grading of lymphoma. But in our case we would not be able to do immunohistochemistry. An atypical case of extranodal Non-Hodgkin's lymphoma of maxillary sinus is presented here for rarity and to increase awareness within medical practitioners.

Management also varies depending on the stage of lymphoma. The vast majority of patients with localized disease are curable with combined modality therapy or combination chemotherapy alone. About 50% patients are cured with doxorubicin based combination chemotherapy and rituximab^{5,6}.

References:

1. Longsdon M, Ha C, Kavadi V, Cabanillas F, Hess M, Cox J. Lymphoma of the nasal cavity and paranasal sinuses. Improved outcome and altered prognostic factors with combined modality therapy. *Cancer* 1997 ; 80 : 477-88.
2. Yamanaka N, Harabuchi Y, Sambe S, Shido F, Matsuda F, Kataura A. Non Hodgkin's lymphoma of Waldayer's ring and nasal cavity, clinical and immunological aspects. *Cancer* 1985; 56:768-76.
3. Chan J, Lo S, Poon Y. Immunophenotypic analysis of non-Hodgkin's lymphomas in Chinese: a study of 75 cases in Hong Kong. *Pathology* 1986 ;18: 419-25
4. Quraishi M, Bessel E, Clark D, Jones N, Bradley P. Non Hodgkin's lymphoma of the sinonasal tract. *Laryngoscope* 2000; 110:1489-92.
5. Adwani D G , Arora R S, Bhattacharya A, Bhagat B. Non-Hodgkin's lymphoma of maxillary sinus: An unusual presentation *Ann Maxillofac Surg.* 2013;3(1):95-7.
6. Shohat I, Berkowicz M, Dori S, Horowitz Z, Wolf M, Taicher S, et al. Primary non-Hodgkin's lymphoma of the sinonasal tract. *Oral Surg Oral Med Oral Pathol* 2004;97: 328-31.